Clinical Imaging 53 (2019) 105–107

Contents lists available at ScienceDirect

Clinical Imaging

journal homepage: www.elsevier.com/locate/clinimag

Solitary fibrous tumor of thyroid: a case report with review of literature

Mohammad Ghasemi-rad[a], Kevin Yuqi Wang[a], Shilpa Jain[b], Christie M. Lincoln[a,*]

[a] Department of Radiology, Baylor College of Medicine, Houston, TX, USA
[b] Department of Pathology & Immunology, Baylor College of Medicine, Houston, TX, USA

ARTICLE INFO

Keywords:
Solitary fibrous tumor
Thyroid gland
Case report

ABSTRACT

Solitary fibrous tumors are rare spindle cell tumors of mesenchymal origin most commonly found in the pleura and peritoneum. In contrast, extra-serosal locations are rare. We present a 41-year-old female with a progressively enlarging left-sided neck mass of one-year duration with subsequent rapid-onset growth over two months, and was pathologically confirmed to be a benign solitary fibrous tumor of the thyroid gland.

1. Introduction

Solitary fibrous tumors (SFTs) are tumors of mesenchymal origin most commonly found in the pleural cavity, but cases in various extra-pleural sites—namely the meninges, eyelids, orbit, paranasal sinuses and nose, oral cavity, breast, lungs, kidney, liver, vulva, and spinal cord—have been reported. Specifically, head and neck solitary fibrous tumors (SFTs) are relatively rare and only a small number of cases have been reported in the literature. Since the first thyroid SFT reported in 1993 by Taccagni et al. [1], there have been 28 cases of thyroid SFTs in the English literature. The age of presentation is between 9–86 (mean 30–40) years in the literature [3]. Whereas 13–15% of pleural SFTs are malignant, extra-pleural SFTs are often benign [2]. Only two out of 28 reported thyroid SFT cases were malignant, and both were in the 6th and 7th decades of life [4,5]. We report a case of a benign SFT of the thyroid gland presenting as a progressively enlarging left-sided neck mass of one-year duration with subsequent rapid-onset growth over two months.

2. Case presentation

A 41-year-old female with no significant past medical history presented to the emergency department with a rapidly enlarging anterior neck mass over the past two months. Patient initially noticed the mass one year prior to presentation and was barely noticeable, but the mass rapidly increased in size and was associated with shortness of breath, changes in her voice (dysphonia), and dysphagia to solid foods. She also reported small amount of hemoptysis. She denied weight loss, pain, or overlying skin changes. Physical exam was notable for a large, slightly fluctuant, non-tender, immobile mass at the left neck at the level of thyroid cartilage extending inferiorly to thoracic inlet. Thyroid function tests were within normal limits.

Computed tomography (CT) of the neck demonstrated a $11.0 \times 6.2 \times 9.7$ cm well-defined, heterogeneously enhancing mass arising from the left lobe of the thyroid gland (Fig. 1A and B). No enlarged cervical or mediastinal lymph nodes were seen. Patient was admitted to the hospital. Fine needle aspiration (FNA) and core biopsy under ultrasound guidance was performed, which was not diagnostic. Patient subsequently underwent total thyroidectomy and was started on thyroid replacement therapy. Surgical biopsy demonstrated spindle cells with a “patternless” distribution, but with collagenous stroma and thin-walled vessels (Fig. 2A, B and C). Cells were positive for Vimentin, CD34, BCL-2, SMA (focal), CD99 (weak, focal), Ki-67 (1%), PAX8 (focal), STAT6 (nuclear). Cells were negative for Pancytokeratin, Thyroglobulin, Desmin, ALK1, p40, HMW keratin, CK7, S-100, TTF-1, CD31, CD45 (very rare small lymphoid cells), Synaptophysin, Chromogranin, CEA, Calcitonin, HMB45, MART-1, MSA, and p63. A diagnosis of SFT arising from thyroid gland was made.

Gross pathology demonstrated an 11-cm encapsulated, tan-pink to tan-white mass in the left thyroid lobe (Fig. 3). Histological features were predominantly similar to the core biopsy. However, there were areas of increased cellularity, moderate atypia, and higher mitotic activity (4/10 high power fields) (Fig. 2A) in the periphery of tumor. Cytoplasmic positivity for CD34 and nuclear positivity for STAT6 were again noted. Ki-67 proliferative index was variable (5–15%), which contrasted the low proliferation index of the core biopsy specimen (approximately 1%). Two cervical lymph nodes dissected were negative for tumor cells. Overall, the combined histologic and immunohistologic profile confirmed the diagnosis of solitary fibrous tumor with areas of high-grade transformation (Fig. 2D). Patient had uneventful hospital course and was discharged home on postoperative day two. Patient is symptom-free 10 months following resection.

* Corresponding author.
E-mail address: Christie.Lincoln@bcm.edu (C.M. Lincoln).

https://doi.org/10.1016/j.clinimag.2018.09.011
Received 6 August 2018; Received in revised form 13 September 2018; Accepted 17 September 2018
0899-7071/ © 2018 Elsevier Inc. All rights reserved.

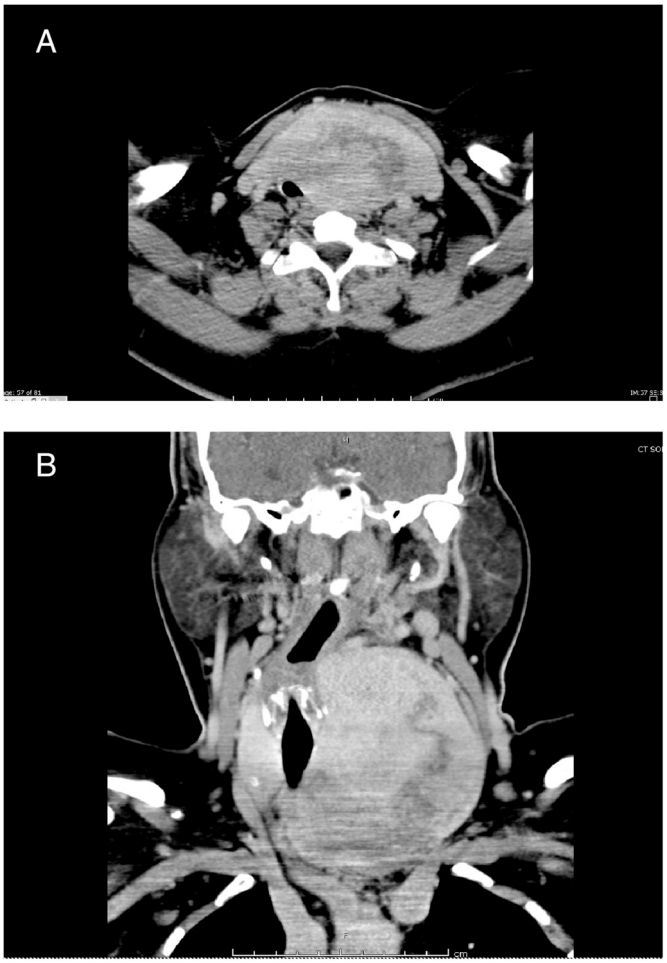

Fig. 1. A and B: Axial (A) and coronal (B) neck CT demonstrated a 11.0 × 6.2 × 9.7 cm well-defined, heterogeneously enhancing mass arising from the left lobe of the thyroid gland. The mass extended superiorly to the level of the hyoid, posteriorly to the prevertebral/retropharyngeal space, anteriorly to the submandibular space and displacing left submandibular gland anteriorly and inferiorly extends retrosternally into the superior mediastinum. There was marked mass effect on the adjacent structures, including approximately 2.4 cm right midline shift of the cervical trachea with mild narrowing of the airway, which measures 0.9 cm at the narrowest transverse dimension.

3. Discussion

SFT is a spindle-cell neoplasm of unknown etiology first described by Klemperer and Rabin in 1931 as a pleural tumor [6]. Since then, various extra-pleural occurrences of these tumors have been reported. Approximately 6% of arise in the head and neck region [7], and have included the tongue, paranasal sinuses, periorbital region, sublingual and thyroid glands, and the parapharyngeal space. The cellular origin of SFT's remains to be determined, but are hypothesized to arise from parafollicular C cells or mesenchymal cells [8]. Of the 28 thyroid SFT cases, the mean age at presentation was 55 years old (range 28–76 years old); 15 cases occurred with females and 13 with males; 11 arose from the right lobe, 14 from the left lobe, 3 did not report laterality, and one was intrathoracic. Two were malignant [5] and one showed tumor necrosis. The mean size was 5.6 cm (range 1.5–13.8 cm), with our case being the second largest thyroid SFT reported thus far (11 cm) and the largest among the benign cases. They usually present as slow-growing masses, but have been reported to undergo degeneration and necrosis.

The initial step in working up thyroid masses is to obtain an ultrasound, and a FNA of suspicious lesions on imaging. When the mass is large or there is concern of airway compromise, CT of the neck may be obtained. Thyroid SFT is diagnosis of exclusion and should be considered if FNA is negative, non-diagnostic [9], or demonstrates spindle cells with a benign morphology as seen in our case. Patient underwent total thyroidectomy. However, the use of STAT6 has been a highly sensitive and specific immunostain to diagnose SFT [10]. The prevalence is likely underestimated, as small, slow-growing SFTs without worrisome imaging features would never be worked up further or result in a non-diagnostic FNA. In one case, a combination of FNA and immunohistochemistry (IHC) was diagnostic for SFT. However, findings suggested a benign process, whereas higher proliferative areas and findings suggestive of a high-grade transformation suggestive of malignancy were demonstrated following excision [4].

On histology, SFTs are composed of bland of spindle fibroblast-like cells growing in nonspecific “patternless” manner with variable amounts of intercellular collagen bundles, keloid-like hyalinization, and alternating hypercellular and hypocellular areas [11]. Areas of hyalinization usually adjacent to collagen deposits are also characteristic features of SFT [12]. The combination of Vimentin and CD34 positivity is typical on immunohistochemical analysis. Over 50% of SFTs are also positive for CD99 [12]. High cellular index, high mitoses (> 4/10 HPF), necrosis, and infiltrating margins are worrisome features for malignancy [13]. Histological differential diagnosis of thyroid tumors exhibiting spindle cell morphology includes hemangiopericytomas, Riedel's thyroiditis, medullary carcinomas, anaplastic carcinomas, sarcomas, leiomyomas, neurofibromas, schwannomas, lymphoma, metastatic spindle cell tumors to the thyroid or neck, and benign nodular goiter with spindle cell component [8–10,14].

The treatment of choice is surgical resection. Depending on the vascularity of the tumor, preoperative embolization may be considered to minimize bleeding intraoperatively. If the tumor is limited to one lobe, a lobectomy can be performed to preserve thyroid function. The prognosis depends on respectability and margins. Recurrence is near 0% with complete excision. Location influences resectability and therefore prognosis. Ultimately, while natural history of these tumors is poorly described due to their rare occurrence, complete resection and long-term follow up are the current recommendations due to the rare possibility of malignant transformation and recurrence.

4. Conclusion

In conclusion, we present the second largest benign case of SFT of thyroid. Though uncommon, SFT should be considered with a slowly enlarging thyroid mass in the setting of negative FNAs. The rarity and unclear natural history requires close and long-term follow-up for recurrence or malignant transformation.

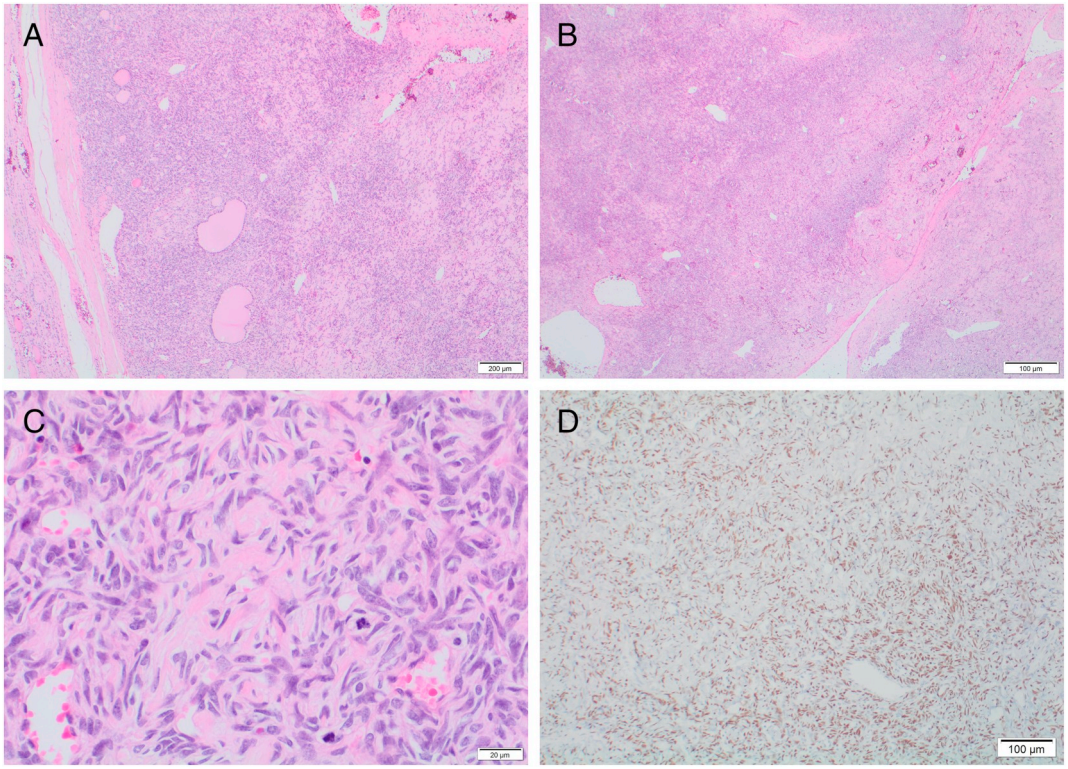

Fig. 2. A, B, C, and D: (A) (H&E; 40×) Encapsulated tumor comprised of spindle cells with entrapped thyroid follicle; (B) (H&E; 100×) Tumor with hyper cellular area (Upper left) and hypo cellular areas (lower right); (C) (H&E; 400×) – High power view of tumor cells in highly proliferative area at the periphery showing moderate pleomorphism and frequent mitoses; (D) STAT6 1: (STAT6 Immunostain; 100×)- tumor cells show diffuse nuclear positivity for STAT6.

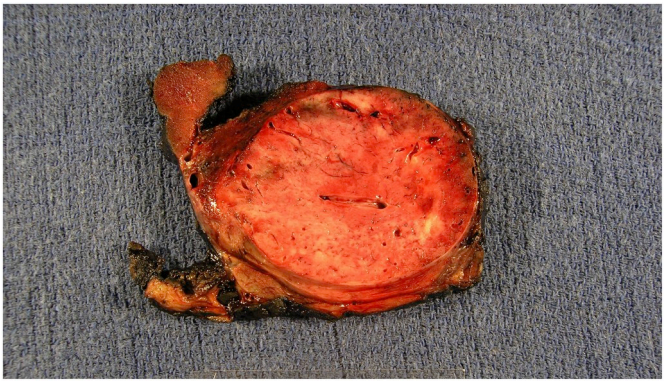

Fig. 3. Gross specimen shows a 11-cm encapsulated, tan-pink to tan-white mass in the left thyroid lobe.

References

[1] Taccagni G, Sambade C, Nesland J, Terreni MR, Sobrinho-Simoes M. Solitary fibrous tumour of the thyroid: clinicopathological, immunohistochemical and ultrastructural study of three cases. Virchows Arch A Pathol Anat Histopathol 1993;422(6):491–7.
[2] Zielinska-Kazmierska B, Grodecka J, Szyszkowski A. Solitary fibrous tumor of the nasal cavity and paranasal sinuses: a case report. J Oral Biol Craniofacial Res 2015;5(2):112–6.
[3] England DM, Hochholzer L, McCarthy MJ. Localized benign and malignant fibrous tumors of the pleura. A clinicopathologic review of 223 cases. Am J Surg Pathol 1989;13(8):640–58.
[4] Alves Filho W, Mahmoud RR, Ramos DM, Araujo-Filho VJ, Lima PP, Cernea CR, et al. Malignant solitary fibrous tumor of the thyroid: a case-report and review of the literature. Arq Bras Endocrinol Metabol 2014;58(4):402–6.
[5] Ning S, Song X, Xiang L, Chen Y, Cheng Y, Chen H. Malignant solitary fibrous tumor of the thyroid gland: report of a case and review of the literature. Diagn Cytopathol 2011;39(9):694–9.
[6] Klemperer PRCB. Primary neoplasms of the pleura. A report of five cases. Am J Ind Med 1931;11:385–412.
[7] Luo Q, Zhang S, Zhang Z. A case of large solitary fibrous tumor originated from the neck. Lin Chung Er Bi Yan Hou Tou Jing Wai Ke Za Zhi 2016;30(2):153–4.
[8] Papi G, Corrado S, LiVolsi VA. Primary spindle cell lesions of the thyroid gland; an overview. Am J Clin Pathol 2006;125 Suppl:S95–123.
[9] Vaziri M, Molanaei S, Tamannaei Z. Solitary fibrous tumor of the intrathoracic goiter. Med J Islam Repub Iran 2014;28:51.
[10] Doyle LA, Vivero M, Fletcher CD, Mertens F, Hornick JL. Nuclear expression of STAT6 distinguishes solitary fibrous tumor from histologic mimics. Mod Pathol 2014;27(3):390–5.
[11] Tanahashi J, Kashima K, Daa T, Kondoh Y, Suzuki M, Kerakawauchi H, et al. Solitary fibrous tumor of the thyroid gland: report of two cases and review of the literature. Pathol Int 2006;56(8):471–7.
[12] Brunnemann RB, Ro JY, Ordonez NG, Mooney J, El-Naggar AK, Ayala AG. Extrapleural solitary fibrous tumor: a clinicopathologic study of 24 cases. Mod Pathol 1999;12(11):1034–42.
[13] Vallat-Decouvelaere AV, Dry SM, Fletcher CD. Atypical and malignant solitary fibrous tumors in extrathoracic locations: evidence of their comparability to intrathoracic tumors. Am J Surg Pathol 1998;22(12):1501–11.
[14] Hirokawa M, Haba R, Kushida Y, Bando K, Kuma S, Kihara M, et al. Benign nodular goiter with spindle cell component. Pathol Int 2010;60(8):586–90.