Table 2 Minimum recommendation of phenotype and units reported in laboratories performing B cell subsets

Subset	Phenotype	Unit(s) reported
Total B cell	$CD19^{+}$	% of PBL
Naïve B cell	$CD19^{+}IgD^{+}$ $IgM^{+}CD27^{-}$	% of PBL and B cells
Marginal zone (non-switched memory B cell)	$CD19^{+}IgD^{+}$ $IgM^{+}CD27^{+}$	% of PBL and B cells
Transitional B cell	$CD19^{+}CD38^{++}IgM^{high}$	% of PBL and B cells
Switched memory B cell	$CD19^{+}IgD^{-}IgM^{-}CD27^{+}$	% of PBL and B cells
$CD21^{low}$	$CD19^{+}CD38^{low}CD21^{low}$	% of B cells

should be reported in the context of age appropriate established biological reference intervals and optimally, reported with an appropriate clinical interpretive comment. This is especially important in the context of treatment [access to intravenous immunoglobulins (IVIg) in Australia], which requires patients with CVID to meet the ESID criteria, which includes B cell phenotype.[8,9]

A significant amount of literature now exists on age-specific biological reference intervals, including paediatric populations.[2,3,10–12] Several studies have demonstrated the age dependent dynamic of B cell numbers and composition in peripheral blood, especially in children.[10,11] Adults have been shown to maintain relatively stable numbers of both immature/transitional and naïve B cells, whereas switched memory B cells and newly generated plasma cell numbers gradually decrease in subjects older than 60 years.[12] Reference intervals used by the laboratory should be documented as outlined in ISO 15189: Medical laboratories - Requirements for quality and competence.

These recommendations aim to standardise the reporting of B cell subset enumeration in routine clinical practice to increase the clinical utility of this assay. These recommendations are the minimum requirements that Australasian laboratories should follow when performing B cell subsets.

Conflicts of interest and sources of funding: The authors state that there are no conflict of interest to disclose.

Louise Wienholt[1], Michael Lane[2,3], Alice Grey[4], Tiffany Hughes[5]

[1]The Royal College of Pathologists of Australasia Quality Assurance Programs (RCPAQAP), St Leonards, Sydney, NSW, Australia; [2]Division of Immunology, Pathology Queensland, Brisbane, Qld, Australia; [3]Faculty of Medicine, University of Queensland, Brisbane, Qld, Australia; [4]Department of Immunology, Royal Prince Alfred Hospital, Sydney, NSW, Australia; [5]Clinical Immunology and Allergy Department, The Royal Adelaide Hospital, Adelaide, SA, Australia

Contact Louise Wienholt.
E-mail: louise.wienholt@rcpaqap.com.au

1. Berglund LJ, Wong SWJ, Fulcher DA. B-cell maturation defects in common variable immunodeficiency and association with clinical features. *Pathology* 2008; 40: 288–94.
2. Warnatz K, Denz A, Drager R, *et al*. Severe deficiency of switched memory B cells (CD27(+)IgM(−)IgD(−)) in subgroups of patients with common variable immunodeficiency: a new approach to classify a heterogeneous disease. *Blood* 2002; 99: 1544–51.
3. Piqueras B, Lavenu-Bombled C, Galicier L, *et al*. Common variable immunodeficiency patient classification based on impaired B cell memory differentiation correlates with clinical aspects. *J Clin Immunol* 2003; 23: 385–400.
4. Wehr C, Kivioja T, Schmitt C, *et al*. The EUROclass trial: defining subgroups in common variable immunodeficiency. *Blood* 2008; 111: 77–85.
5. Ferry BL, Jones J, Bateman EA, *et al*. Measurement of peripheral B cell subpopulations in common variable immunodeficiency (CVID) using a whole blood method. *Clin Exp Immunol* 2015; 140: 532–9.
6. Bonilla FA, Barlan I, Chapel H, *et al*. International Consensus Document (ICON): common variable immunodeficiency disorders. *J Allergy Clin Immunol Pract* 2016; 4: 38–59.
7. European Society for Immunodeficiencies (ESID). *Diagnostic criteria of CVID*. Cited 5 Apr 2019. https://esid.org/Working-Parties/Registry/
8. Plebani M. The clinical importance of laboratory reasoning. *Clin Chim Acta* 1999; 280: 35–45.
9. National Blood Authority Australia. *Criteria for the clinical use of intravenous immunoglobulin in Australia*. Cited 10 Jan 2019. https://www.blood.gov.au/ivig-criteria
10. Morbach H, Eichhorn EM, Liese J, *et al*. Reference values for B cell subpopulations from infancy to adulthood: age-dependent reference values for B cell populations. *Clin Exp Immunol* 2010; 162: 271–9.
11. Piątosa B, Wolska-Kuśnierz B, Pac M, *et al*. B cell subsets in healthy children: reference values for evaluation of B cell maturation process in peripheral blood. *Cytometry B Clin Cytom* 2010; 78: 372–81.
12. Blanco E, Pérez-Andrés M, Arriba-Méndez S, *et al*. Age-associated distribution of normal B-cell and plasma cell subsets in peripheral blood. *J Allergy Clin Immunol* 2018; 141: 2208–19. e16.

DOI: https://doi.org/10.1016/j.pathol.2019.04.013

Simultaneous cytomegalovirus glomerulitis and BK virus nephropathy leading to kidney allograft loss

Sir,
Viral reactivations are a major cause of morbidity and mortality in immunocompromised patients. In kidney transplant recipients, BK polyomavirus is one of the most challenging opportunistic pathogens due to high prevalence, frequent reactivation and poor graft outcome. BK virus belongs to the family of Polyomaviridae and has a tropism for the renourinary tract which represents a site of viral latency. BK virus nephropathy (BKN) is usually encountered in a context of over-immunosuppression and affects up to 10% of kidney transplant recipients, resulting in 60% graft loss.[1] Kidney allograft biopsy remains the gold standard for BKN diagnosis. By contrast, CMV (cytomegalovirus) nephropathy is rare, detected in <1% of biopsied renal allografts,[2] but CMV infection or disease is an independent risk factor for patient death and long-term allograft dysfunction. Although BK and CMV serological reactivations may be associated in the kidney transplantation context,[3–5] histologically-proven co-infection in the kidney allograft is an exceptional finding. We report a case of simultaneous CMV glomerulitis and BKN leading to kidney allograft loss.

A 68-year-old woman with end-stage renal disease secondary to unknown glomerulopathy received a kidney from a cadaveric donor, with graft function (serum creatinine level 81 μmol/L) immediately after transplantation. CMV status was donor-positive (D+)/recipient-positive (R+). The patient received basiliximab, tacrolimus, mycophenolate mofetil and methylprednisolone for induction, followed by maintenance immunosuppression with tacrolimus, mycophenolate mofetil,

and methylprednisolone. Infection prophylaxis included valganciclovir and sulfamethoxazole-trimethoprim. Tacrolimus was replaced with cyclosporin 2 months after transplantation due to new-onset diabetes. Three months after transplantation, an acute rejection episode with isolated vasculitis (v2 according to the Banff classification) was resolved by treatment with thymoglobulin and methylprednisolone (serum creatinine concentration 93 µmol/L). The patient developed BK viraemia without CMV infection six months post-transplantation, leading to a reduction of immunosuppression. Prophylaxis with valganciclovir was stopped 6 months post-transplantation.

The patient was then lost to follow-up, but was subsequently referred to our nephrology department for evaluation of an increase in serum creatinine concentration (300 µmol/L) 34 months post-transplantation. The physical examination was unremarkable. The patient had a proteininuria/creatininuria ratio of 52 mg/mmol, and donor-specific antibodies were undetectable. Trough cyclosporin concentration was satisfactory (75 ng/mL). The area under the curve for mycophenolic acid concentration was 19.2 mg.h/L (normal range 30−60 mg.h/L). Our patient also displayed liver cytolysis (alanine aminotransferase and aspartate aminotransferase levels of 256 IU/L and 346 IU/L, respectively), anicteric cholestasis (alkaline phosphatase and γ-glutamyl transferase levels of 456 IU/L and 769 IU/L, respectively) and anaemia (haemoglobin concentration 7.3 g/dL) with normal leukocyte and platelet counts. Polymerase chain reaction on plasma detected 39,900 copies/mL for CMV and 4,620,000 copies/mL for BK virus.

A biopsy was performed on the transplanted kidney. The renal biopsy specimen consisted of renal cortex with seven glomeruli including three obsolescent glomeruli. Two glomeruli displayed capillary occlusion due to swollen endothelial cells with dystrophic voluminous nuclei suggestive of viral infection (Fig. 1A). Multiples tubules showed flattened epithelium with nuclear enlargement and inclusions (Fig. 1B). Chronic tubulointerstitial damage was extensive (50% of cortex sampled) with focal mononuclear cell infiltration (ti1 according to Banff classification). No tubulitis lesions were observed. C4d was negative in peritubular capillaries. Immunohistochemistry confirmed BKN and CMV glomerulitis (Fig. 2) in a context of CMV disease with kidney and liver injury. Immunohistochemical staining for CMV was negative in the tubular and interstitial compartments.

The immunosuppressive regimen was reduced and mycophenolate mofetil was replaced with leflunomide. CMV viral load increased despite intravenous ganciclovir. Ganciclovir-resistant CMV disease was clinically suspected, but CMV genotypic resistance testing was inconclusive. Maribavir treatment was initiated, leading to the resolution of CMV viraemia. Unfortunately, graft function declined further in a context of severe interstitial fibrosis and persistent BK viraemia, necessitating the initiation of renal replacement therapy.

BK virus tubulo-interstitial nephritis is characterised by acute tubular injury, interstitial inflammation, tubulitis and a viral cytopathic effect observed in renal tubular cells displaying a gelatinous basophilic inclusion replacing the

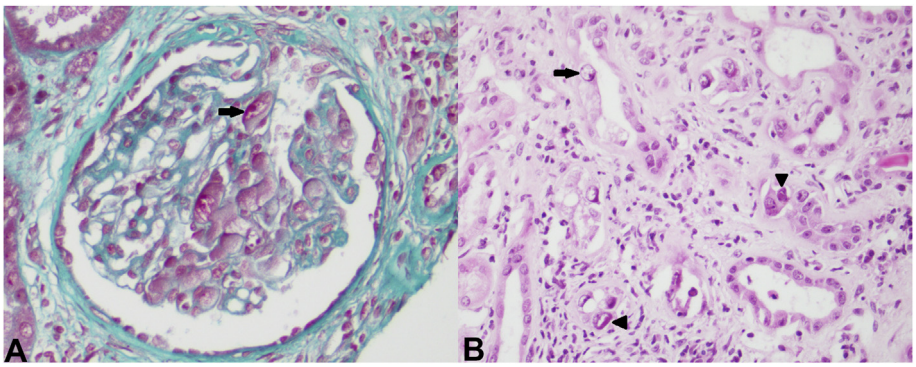

Fig. 1 (A) Glomerulitis: occlusion of glomerular capillaries by swollen endothelial cells (arrow) with dystrophic and voluminous nuclei suggestive of viral infection (Masson's trichrome). (B) Nuclear enlargement (arrow) and inclusions (arrowhead) in necrotic tubular epithelial cells with denudation of the tubular basement membrane (H&E).

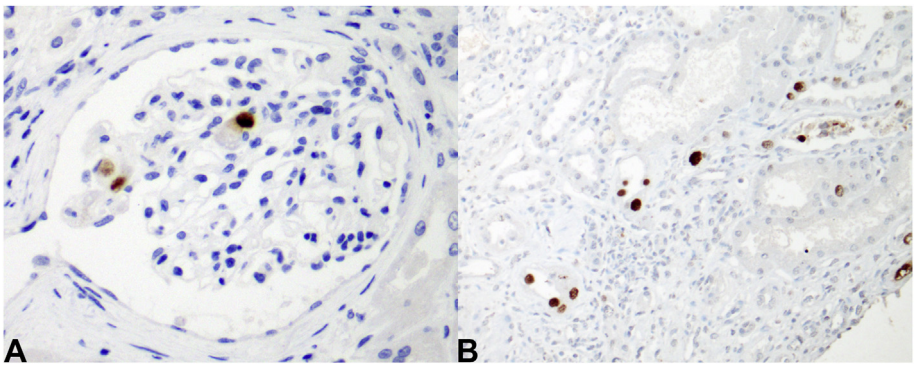

Fig. 2 (A) Anti-CMV immunohistochemistry revealing nuclear positivity in swollen endothelial cells, confirming CMV-mediated glomerulitis. (B) Anti-SV40 immunohistochemistry revealing nuclear positivity in dystrophic tubular epithelial cells, confirming BK virus nephropathy.

nuclear chromatin. BK virus infects only epithelial cells, including podocyte and parietal epithelial cells, potentially leading to crescent formation in a subset of patients.[6] Due to sampling variation and histological heterogeneity, absence of BK virus cytopathic changes may be a source of underdiagnosis. CMV nephropathy may manifest with various histopathological lesions. Tubulo-interstitial nephritis is the most common pattern of CMV infection in the kidney allograft. In contrast to BK virus, CMV may affect endothelial cells leading to CMV glomerulopathy, thrombotic microangiopathy or vasculitis.[2] Viral infections may also represent 'second hits' that lead to glomerular injury in transplanted kidneys with two apoliprotein L1 (APOL1) risk variants. *De novo* collapsing focal segmental glomerulosclerosis has been reported in the context of BK or CMV viraemia in these recipients.[7]

CMV glomerulitis and BKN must be differentiated from humoral rejection-mediated glomerulitis and cellular rejection, respectively, as these conditions are treated with opposing therapeutic regimens. Our case highlights the contribution of SV40 (large T antigen) and CMV immunohistochemistry to correct diagnosis. However, acute T-cell mediated rejection which resembles and overlaps with BKN occurs in 21% of BKN and remains a challenge for the pathologist.[8]

As far as we know, only one case of concurrent CMV glomerulitis and BKN has been reported, in a donor negative (D−)/R+ CMV context, 11 weeks post-transplantation with stable graft function at the last follow-up.[9] Conflicting data have been published concerning the association of CMV and BK viraemias in the kidney transplantation context. Several studies suggested an association between CMV and BK virus reactivations, however Elfadawy *et al.* showed that BK viraemia was not statistically associated with subsequent CMV viraemia in an interventional study.[10]

Recently, a large prospective multicentre study confirmed that CMV and BK reactivations were significantly associated in the kidney transplantation context.[3] Interestingly, the risk of BK virus-associated haemorrhagic cystitis is also associated with CMV viraemia after allogenic haematopoietic stem cell transplantation.[11] A strong association between BK viraemia and CMV infection may simply mirror high-dose immunosuppression. It has also been suggested that BK viraemia may occur after CMV reactivation due to immunomodulatory properties of CMV, as production of suppressive cytokines. Conversely, CMV reactivation may occur after BK virus infection due to the permissive effect of BK virus.[5] In our patient, BK viraemia preceded CMV viraemia and the trough cyclosporin level and the area under the curve of mycophenolic acid were consistent with reduced immunosuppression. However, we cannot speculate about the relationship between CMV and BK virus infections in this case.

Both our patient and the previously reported case were CMV R+. CMV infection risk is higher in CMV seronegative patients receiving CMV D+ allograft. Nevertheless, CMV D+/R+ group present an intermediate risk for active CMV infection and can encounter late onset CMV disease. Intriguingly, the highest incidence of BK viraemia is noted in intermediate CMV risk patients (D−/R+ and D+/R+) and positive recipient serostatus for CMV is a statistically significant risk for the development of BK viraemia.[12] CMV seropositivity of donor is associated with CMV-BK combined reactivation.[3]

It has been suggested that combined reactivation may have a deep impact on renal function one-year post transplantation, even at low viral load levels. Patients with BK-CMV combined reactivation, even at moderate rather than high levels, have lower graft function than those with no viral reactivation.[3]

Our case histologically illustrates the epidemiological association between BK and CMV reactivations which may severely impact kidney allograft function. This case of simultaneous CMV and BK virus nephropathy leading to graft loss advocates for close monitoring of CMV viraemia when BK viraemia is detected, and vice versa. Nephropathologists should also be aware of this possible association in kidney allograft biopsy.

Conflicts of interest and sources of funding: The authors state that there are no conflicts of interest to disclose.

Anissa Moktefi[1,2], Tomek Kofman[3], Hamza Sakhi[2,3], Marie Matignon[2,3], Philippe Grimbert[2,3]

[1]APHP (Assistance Publique-Hôpitaux de Paris), Pathology Department, Groupe Hospitalier Henri-Mondor/Albert Chenevier, Créteil, France; [2]Université Paris-Est-Créteil, (UPEC), DHU (Département Hospitalo-Universitaire), VIC (Virus-Immunité-Cancer), IMRB (Institut Mondor de Recherche Biomédicale), Equipe 21, INSERM U 955, Créteil, France; [3]AP-HP (Assistance Publique-Hôpitaux de Paris), Nephrology and Renal Transplantation Department, Institut Francilien de Recherche en Néphrologie et Transplantation (IFRNT), Groupe Hospitalier Henri-Mondor/Albert-Chenevier, Créteil, France

Contact Dr Anissa Moktefi.
E-mail: anissa.moktefi@aphp.fr

1. Babel N, Volk HD, Reinke P. BK polyomavirus infection and nephropathy: the virus-immune system interplay. *Nat Rev Nephrol* 2011; 7: 399−406.
2. Rane S, Nada R, Minz M, *et al*. Spectrum of cytomegalovirus-induced renal pathology in renal allograft recipients. *Transplant Proc* 2012; 44: 713−6.
3. Blasquez-Navarro A, Dang-Heine C, Wittenbrink N, *et al*. BKV, CMV and EBV interactions and their effect on graft function one year post renal transplantation: results from a large multi-centre study. *EBioMedicine* 2018; 31: 113−21.
4. Schachtner T, Babel N, Reinke P. Different risk factor profiles distinguish early-onset from late-onset BKV-replication. *Transpl Int* 2015; 28: 1081−91.
5. Toyoda M, Puliyanda DP, Amet N, *et al*. Co-infection of polyomavirus-BK and cytomegalovirus in renal transplant recipients. *Transplantation* 2005; 80: 198−205.
6. Celik B, Randhawa PS. Glomerular changes in BK virus nephropathy. *Hum Pathol* 2004; 35: 367−70.
7. Chang JH, Husain SA, Santoriello D, *et al*. Donor's APOL1 risk genotype and "second hits" associated with de novo collapsing glomerulopathy in deceased donor kidney transplant recipients: a report of 5 cases. *Am J Kidney Dis* 2019; 73: 134−9.
8. Drachenberg CB, Papadimitriou JC, Chaudhry MR, *et al*. Histological evolution of BK virus-associated nephropathy: importance of integrating clinical and pathological findings. *Am J Transplant* 2017; 17: 2078−91.
9. Chikeka IO, Paulk A, Haririan JC, *et al*. Concurrent cytomegalovirus glomerulitis and BK polyomavirus-associated nephropathy in a kidney allograft biopsy. *Transpl Infect Dis* 2016; 18: 247−50.
10. Elfadawy N, Flechner SM, Liu X, *et al*. CMV viremia is associated with a decreased incidence of BKV reactivation after kidney and kidney-pancreas transplantation. *Transplantation* 2013; 96: 1097−103.

11. Uhm J, Hamad N, Michelis FV, *et al*. The risk of polyomavirus BK-associated hemorrhagic cystitis after allogeneic hematopoietic SCT is associated with myeloablative conditioning, CMV viremia and severe acute GVHD. *Bone Marrow Transplant* 2014; 49: 1528–34.
12. Jacobi J, Prignitz A, Büttner M, *et al*. BK viremia and polyomavirus nephropathy in 352 kidney transplants; risk factors and potential role of mTOR inhibition. *BMC Nephrol* 2013; 14: 207.

DOI: https://doi.org/10.1016/j.pathol.2019.05.007

Development of monomorphic B-cell plasmacytoma post-transplant lymphoproliferative disorder in a patient with previous autologous stem cell transplant

Sir,

Post-transplant lymphoproliferative disorders (PTLDs) are uncommon lymphoid and/or plasmacytic proliferations that can occur in patients after undergoing solid organ or haematopoietic stem cell transplantation, secondary to extrinsic immunosuppression inherent in these procedures. In the context of haematopoietic stem cell transplantation, the large majority of reported PTLDs occur in patients who received allogenic haematopoietic stem cell transplantation (AlloHSCT). Only a few cases of PTLD following autologous haematopoietic stem cell transplantation (AHSCT) have been reported.[1–6] We herein report the rare interesting case of an Epstein–Barr virus (EBV) negative monomorphic B-cell plasmacytoma post-transplant lymphoproliferative disorder (PTLD), developing in a patient who received AHSCT for treatment of advanced stage classic Hodgkin lymphoma (CHL).

A 23-year-old male presented to our institution 4 years previously with fever, weight loss and shortness of breath of 2–4 months duration. Positron emission tomography (PET) scan performed showed a fluorodeoxyglucose (FDG) avid, large, bulky, 10.6 cm anterior mediastinal mass, multiple FDG avid lymph nodes above and below the diaphragm, as well as multiple FDG lesions in the axial skeleton. A biopsy of the anterior mediastinal mass was performed, and the patient was diagnosed with nodular sclerosis CHL (Fig. 1A). The patient was treated with six cycles of adriamycin, bleomycin, vinblastine and dacarbazine (ABVD) and radiotherapy to the mediastinum. The patient achieved complete remission based on positron emission tomography (PET) scan findings after the treatment. However, 2 years later he developed new FDG avid lymphadenopathy above and below the diaphragm, as well as new FDG avid iliac bone lesions. Biopsy of the iliac bone showed disease relapse of CHL. The patient received platinum-based salvage chemotherapy for the disease relapse. After harvesting of peripheral blood stem cells, he underwent AHSCT. The conditioning regimen consisted of carmustine, etoposide, cytarabine and melphalan. Unmanipulated haematopoietic stem cells were administered at a cell dose of 2.78×10^6 $CD34^+$ cells/kg. The patient had an episode of culture negative neutropenic fever post-AHSCT, from which he subsequently recovered. He was not put on any immunosuppressive drug regimen post-AHSCT. Three and a half months following AHSCT, the follow-up PET scan showed new FDG avid left submental and level II cervical lymph nodes. An excision biopsy of a left level II cervical lymph node was performed. On histology, the cervical lymph node architecture was preserved with presence of reactive lymphoid follicles. There were increased numbers of small mature plasma cells noted in the paracortical areas and sinuses (Fig. 1B). No neoplastic Reed–Sternberg cells were seen. The histological diagnosis

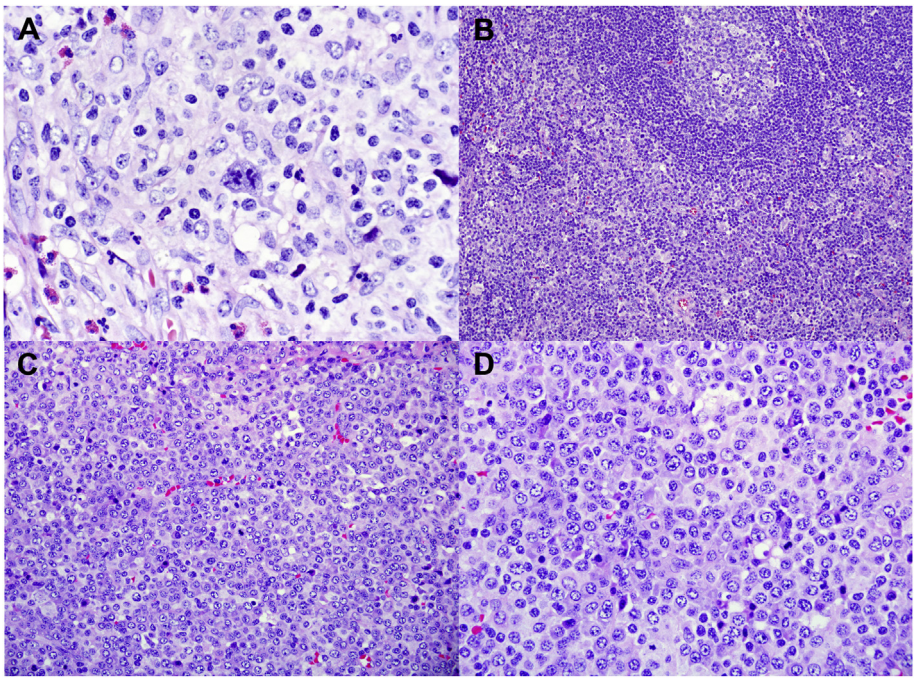

Fig. 1 (A) First mediastinal mass biopsy showing neoplastic classical Reed–Sternberg cells surrounded by reactive inflammatory cells (H&E). (B) Subsequent left level II cervical lymph node biopsy showing preserved nodal architecture, but with increased numbers of plasma cells in the paracortical areas (H&E). (C,D) Final left submental lymph node biopsy showing effacement of nodal architecture by sheets of mature plasma cells and plasmablasts (H&E).