The Knee 26 (2019) 1058–1066

Contents lists available at ScienceDirect

The Knee

Opposite cortical fractures in closed-wedge HTO: New classification and treatment algorithm

Anton Dorofeev [a,*], Alfred Tylla [a], Wolf Robert Drescher [a,b], Richard Stangl [a]

[a] Sana Klinikum Rummelsberg, Department of Orthopaedic Surgery, Rummelsberg 71, 90592 Schwarzenbruck, Germany
[b] Department of Orthopaedics, RWTH University Hospital, Pauwelsstrasse 30, 52074 Aachen, Germany

ARTICLE INFO

Article history:
Received 25 January 2019
Received in revised form 7 July 2019
Accepted 24 July 2019

Keywords:
Classification
Hinge
Fracture
CWHTO
Pseudarthrosis

ABSTRACT

Background: An intact opposite cortex (OC) is essential for HTO stability. For an appropriate prognosis of the role of opposite cortical fracture (OCF) in the development of mechanical complications, it is important to identify the type of OCF. This study seeks to establish an OCF classification in CWHTO with a treatment algorithm.
Methods: The clinical radiological results of 187 angle-stable navigated CWHTOs were retrospectively analyzed. Two OCF types (according the direction of fracture line) with three subtypes (A-nondisplaced, B-primarily, and C-secondarily displaced) were identified.
Results: A total of 67.6% of type 1 and 44.7% of type 2 OCFs were non-displaced ($p = 0.041$). Secondary displacement developed in 36.2% of type 2 OCFs and in none of the type 1 OCFs. The tibial pseudoarthrosis rate was significantly higher with displaced type 2B and 2C OCFs than with non-displaced 2A fractures (30.8% vs. 4.8%, $p = 0.03$). The regression analysis showed a relevant correlation between OCF types 1B, 2B, and 2C and the incidence of mechanical complications; the significance of type 2C fractures (OR 43.8) for the incidence of tibial pseudoarthrosis was more than twice as high than for type 1B fractures.
Conclusion: Type 1 OCFs are considered to be stable and type 2 OCFs unstable with a tendency to become displaced. Only 57.4% of type 2 OCFs were recognizable intraoperatively; thus, increased attention must be focused on this event in postoperative repeat radiographs. The classification provides practice-relevant therapeutic approaches.
© 2019 Elsevier B.V. All rights reserved.

1. Introduction

High tibial osteotomy (HTO) is an effective surgical procedure for treatment of isolated varus gonarthrosis [1–4]. Primary mechanical stability of the osteotomy is essential for good clinical results and appropriate bony consolidation [5,6]. However, this stability can be decreased by several factors, one of which is the opposite cortical fracture (OCF) [6–8]. To recognize the significance of OCFs and the resulting complications, it is important to determine the type of OCF. For the open wedge (OW) technique, various classifications have already been proposed [8–10]; however, thus far, no classification for OCFs with the closed wedge (CW) technique has been published. The objective of the study is to determine the types of OCF in CWHTO, identify potential risk fac-

* Corresponding author.
E-mail addresses: anton.dorofeev@sana.de, (A. Dorofeev), alfred.tylla@sana.de, (A. Tylla), wolf.drescher@sana.de, (W.R. Drescher), richard.stangl@sana.de. (R. Stangl).

https://doi.org/10.1016/j.knee.2019.07.014
0968-0160/© 2019 Elsevier B.V. All rights reserved.

tors for the development of the various types, and track the influence of the various OCF types on the occurrence of mechanical complications.

2. Materials and methods

2.1. Methods

The results of the overall 187 CWHTOs performed from January 2011 to December 2015 were retrospectively analyzed. All of the osteotomies were performed with computer navigation (Orthopilot System, B Braun Aesculap, Tuttlingen, Germany) and fixed with angle-stable NCB (non-contact-bridging, Zimmer-Biomet, Warsaw, IN, USA, n = 124) or lateral TomoFix plates (DepuySynthes, Oberdorf, Switzerland, n = 63). The status of the medial opposite cortex was evaluated intraoperatively under fluoroscopy and postoperatively with radiographs after two to three days, six to eight weeks, three months, and one year. Primary evaluation criteria were displacement of the hinge and whether the displacement occurred primarily or secondarily over time and whether the OCF was already identified intraoperatively or only in the postoperative course. In cases of intraoperatively detected OCF, the stability of the HTO after plate osteosynthesis was checked radiologically. If there was any remaining instability, further stabilization was carried out. All of the patients were mobilized under partial weight bearing with 20 kg (for six weeks) without any immobilization. In patients with OCF, this regimen was changed only in isolated cases: no weight bearing on the operated leg for four weeks (6.2%), if necessary, with immobilization in a Tutor brace for four weeks (3.7%). After 19.8% of the OCFs, re-osteosynthesis was subsequently required with a delayed weight bearing on the operated leg for four weeks after surgery. Primary intraoperative additional osteosynthesis of the detected OCF was performed in five (6.2%) of the CWHTOs with fractures (100% = number of OCFs). These cases were excluded from the statistical analysis of associated mechanical complications. The clinical results were evaluated using KOOS, Lysholm, and VAS scores [11,12,13].

The following were used as possible influencing factors: age, sex, BMI, and various radiological values (the femorotibial angle and medial proximal tibial angle (MPTA), the status of the medial opposite cortex after surgery, the frontal osteotomy angle, the distance between the tip of the osteotomy and the tibial plateau as well as the contralateral tibial cortex, callus formation over time, implant failure). The change in the MPTA (Δ) was measured as the extent of loss of correction over time; the MPTA reduction was referred to as a minus value.

2.2. Surgical technique

All surgeries were performed by four experienced senior surgeons. The first skin incision was performed over the proximal fibula 15 cm below the fibular head proceeding to the next layer entering the fascia between the soleus and peroneal compartments. The fibula was cut obliquely at a site between the proximal and middle third of its length under protection with Hohmann retractors. The navigation sensors were placed femoral and tibial with pins. After that, a longitudinal L-shaped anterolateral approach to the proximal tibia is performed by a subperiostal detaching tibialis anterior muscle. The kinematic and anatomical landmarks were collected, and a degree of the required correction was determined. Using a C-arm, two Kirschner-wires were placed oriented obliquely and ascending from the lateral to the medial cortex according the required degree of correction. A bone wedge was cut and removed, the medial opposite cortex is slightly weakened with a Lambotte-chisel. A locking plate was placed and fixed proximally. The osteotomy gap is carefully gradually closed using a distally positioned standard tension articulated device (Zimmer-Biomet, Warsaw, IN, USA or DepuySynthes, Oberdorf, Switzerland, respectively). All the remaining locking screws were inserted. Afterwards, a leg alignment, an extension of the knee and a position of the Fujisawa point (leg axis line at the point of 62.5% [14] was aimed) were verified by navigation.

In the revision surgeries, the plate was removed, the bone at the osteotomy site was decorticated, and the zones with bone sclerosis were refreshed. An accurate reduction and reconstruction of the leg alignment with the navigation system and a re-osteosynthesis with a new locking plate (NCB, Zimmer-Biomet, Warsaw, IN, USA or TomoFix, DepuySynthes, Oberdorf, Switzerland) were performed. The remaining gap was filled with an allogenic spongiosa graft. For the stabilization of the medial cortex, an additional long, partially threaded spongiosa screw was inserted oriented obliquely and ascending from the distal lateral ventral tibial cortex to the dorsal proximal medial tibial cortex as a lag screw. Thus, the osteotomy gap was bridged.

2.3. Evaluation methods

In principle, two groups of fractures in CWHTO were classified (see Figure 1). As a reference, a line perpendicular to the anatomical tibial axis is drawn through the end of the osteotomy in the direction of the medial opposite cortex. For type 1, the fracture line runs from the osteotomy gap further medially and a little proximally; the fracture remains over the reference line. For type 2 fractures, the fracture line sinks below the reference line and subsequently forms a typical rounded, peaked break (see Figure 1a, b). Both of the OCF types could be subclassified as non-displaced (subtype A), primarily displaced (subtype B), and secondarily displaced (subtype C). An OCF with more than two-millimeter gap was classified as displaced.

Radiologically, in addition to common values, the distances between the tip of the osteotomy and the tibial plateau ("proximal distance") and the medial cortex ("medial distance") as well as the frontal osteotomy angle (defined as an angle between

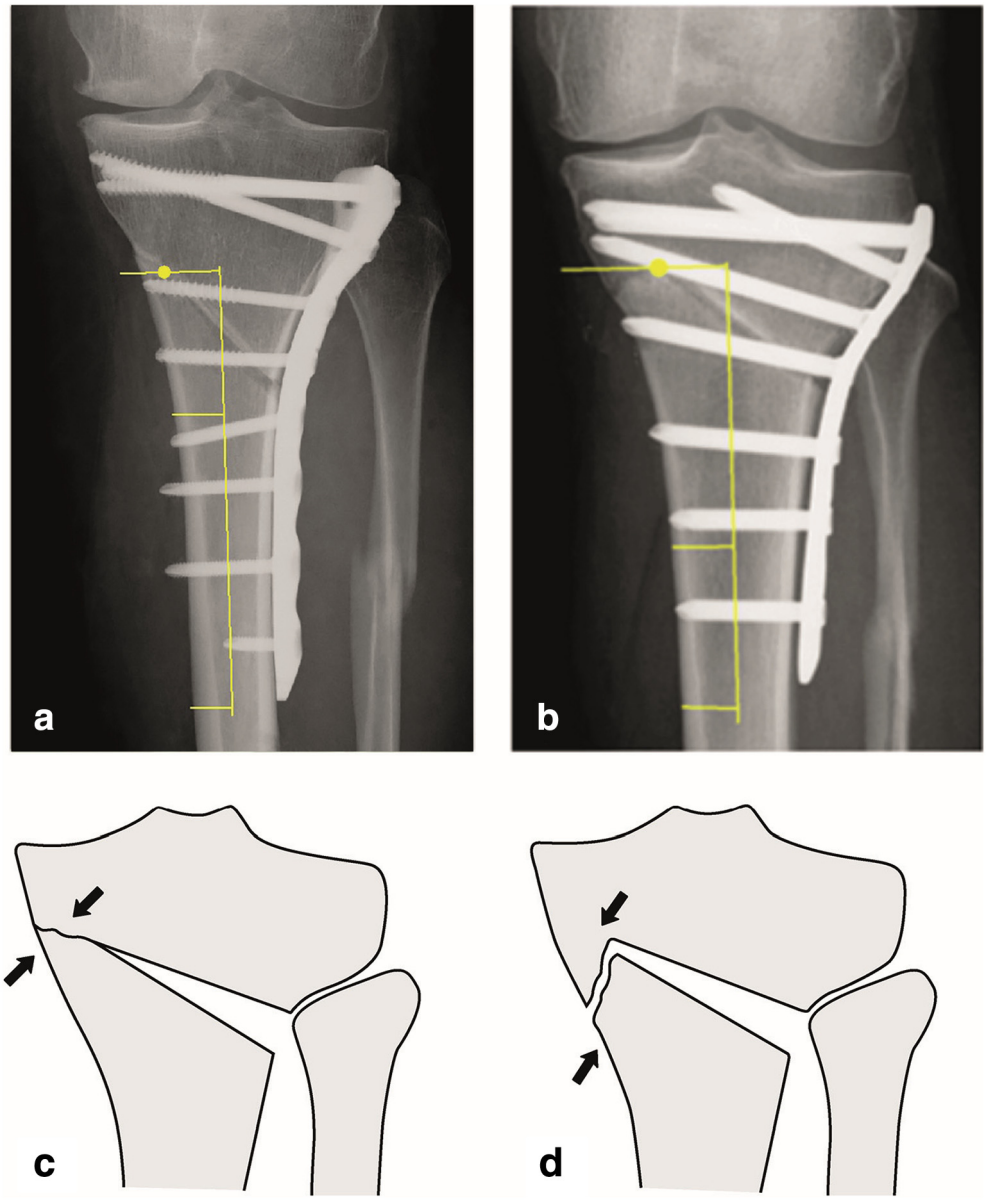

Figure 1. Description of the OCF classification in CWHTO: type 1 (a, c) and type 2 (b, d). OCF — opposite cortical fracture, CWHTO — closed-wedge osteotomy.

the tibial plateau line and the line of the osteotomy from the lateral cortex to the tip of the osteotomy) were measured (Figure 2b).

2.4. Statistical analysis

Statistical processing was carried out using SPSS V22.0 software (SPSS Inc., Chicago, Illinois, USA). Statistical significance was defined as a p value of 0.05. The differences between interval-scaled variables were described using Student's t-test or the Mann–Whitney U-test, depending on the distribution type. For testing differences between ordinal- and nominal-scaled characteristics, the chi^2 test and Fisher's exact test were used. The correlation analysis was carried out using the Pearson and Spearman tests. A binary logistic regression method was used to analyze the impact of different OCF-types on the rate of mechanical complications.

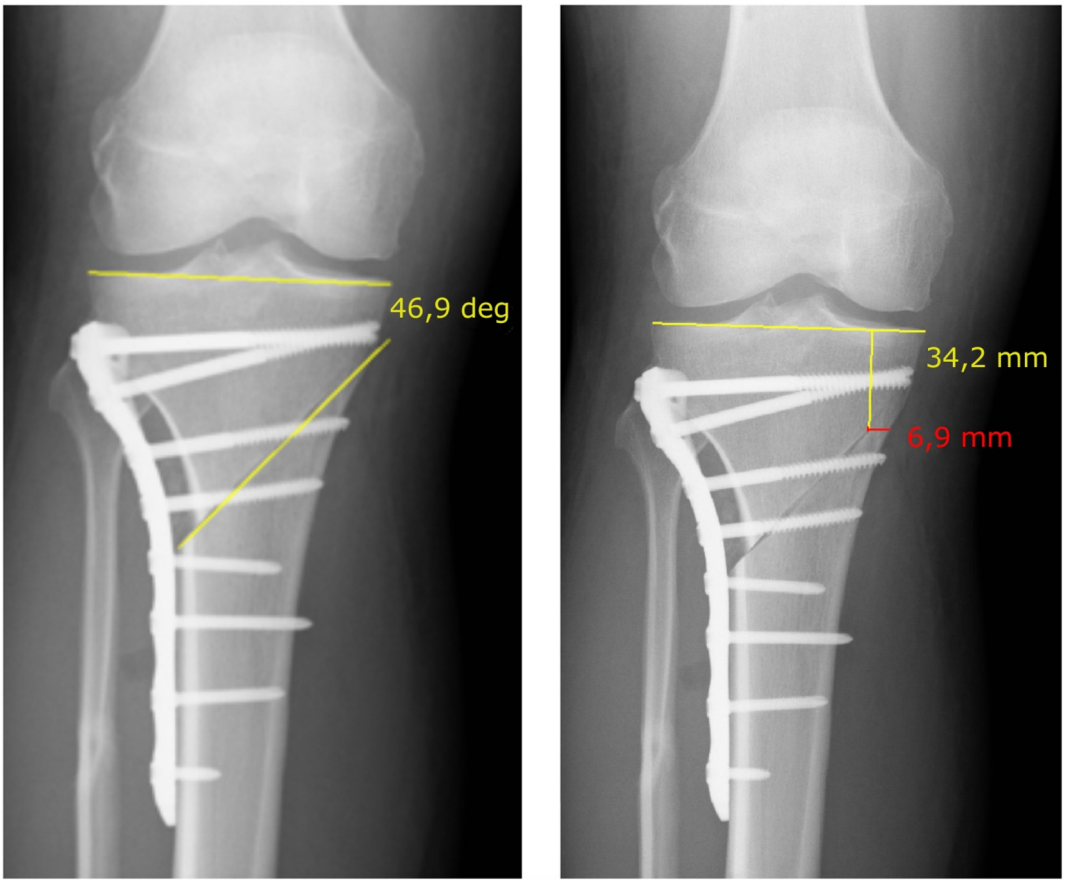

Figure 2. Radiological parameters: (a) the frontal osteotomy angle; (b) "proximal" (yellow) and "medial" (red) distance between the osteotomy tip and the tibial plateau and opposite cortex, respectively. (For interpretation of the references to color in this figure legend, the reader is referred to the web version of this article.)

3. Results

Type 1 OCFs were observed in 34 HTOs (18.1% of the HTOs and 42% of the total number of OCFs) and type 2 OCFs in 47 HTOs (25.1% and 58%, respectively). The majority of the type 1 OCFs showed no displacement either primarily or over time (subtype A, 67.6%); by contrast, only 44.7% of the type 2 OCFs were non-displaced ($p = 0.041$). Whereas secondary displacement (subtype C) was not observed in any of the type 1 OCFs, it was detected in 36.2% of the type 2 OCFs over time ($p < 0.001$, see Table 1).

Table 1
OCF characteristics depending on fracture type.

	Type 1	Type 2	p-value
n, of which:	34 (42%)	47 (58%)	
Non-displaced (A)	23 (67.6%)	21 (44.7%)	**0.041**
Primarily displaced (B)	11 (32.4%)	9 (19.1%)	< **0.001**
Secondarily displaced (C)	0	17 (36.2%)	< **0.001**
Intraoperatively recognizable	29 (85.3%)	27 (57.4%)	**0.007**
Recognizable over time	5 (14.7%)	20 (42.6%)	**0.007**
Degree of correction	9.3 ± 1.8°	8.4 ± 2.1°	**0.038**
Frontal osteotomy angle	44.0 ± 5.0°	43.9 ± 5.8°	n.s.
Distance proximal, mm	32.9 ± 7.1	31.7 ± 6.3	n.s.
Distance medial, mm	8.9 ± 3.0	10.9 ± 3.2	**0.008**
Δ MPTA	−0.8 ± 1.5°	−1.7 ± 1.7°	**0.023**
Age	50.6 ± 6.2 J	49.8 ± 9.8 J	n.s.
Sex	♂ 26 (76.5%)	♂ 37 (78.7%)	n.s.
	♀ 8 (23.5%)	♀ 10 (21.3%)	
BMI, kg/m^2	31.1 ± 5.3	30.5 ± 5.6	n.s.

OCF — opposite cortical fracture, MPTA — medial proximal tibial angle; BMI — body-mass-index; n.s. - not significant.

Table 2
Distribution of complications among fracture types.

Characteristics	No fracture (n = 106)	Type 1 (n = 34)	Type 2 (n = 47)
Mechanical complications	5 (4,7%)	7 (20.6%)	16 (34%)
Non-displaced OCF (subtype A)	–	2/23 (8.7%)	1/21 (4.8%)
Displaced OCF	–	5/11 (45.6%)	15/26 (57.7%)
Primarily displaced OCF (subtype B)	–	5/11 (45.6%)	4/9 (44.4%)
Secondarily displaced OCF (subtype C)	–	–	11/17 (64.7%)
Intraoperatively recognizable OCF	–	7/29 (24.1%)	7/27 (25.9%)
Postoperatively recognizable OCF	–	0/5	9/20 (45%)
Tibial pseudoarthrosis	1 (0,9%)	4 (11.8%)	9 (19.1%)
Non-displaced OCF (subtype A)	–	2/23 (8.7%)	1/21 (4.8%)
Displaced OCF	–	2/11 (18.2%)	8/26 (30.8%)
Primarily displaced OCF (subtype B)	–	2/11 (18.2%)	3/9 (33.3%)
Secondarily displaced OCF (subtype C)	–	–	5/17 (29.4%)
Intraoperatively recognizable OCF	–	4/29 (13.8%)	5/22 (22.7%)
Postoperatively recognizable OCF	–	0/5	4/20 (20%)
Loss of correction	0	2 (5.9%)	6 (12.8%)
Non-displaced OCF (subtype A)	–	0	0
Displaced OCF	–	2/11 (18.2%)	6/26 (23.1%)
Primarily displaced OCF (subtype B)	–	2/11 (18.2%)	1/9 (11.1%)
Secondarily displaced OCF (subtype C)	–	–	5/17 (29.4%)
Intraoperatively recognizable OCF	–	2/29 (6.9%)	2/27 (7.4%)
Postoperatively recognizable OCF	–	0	4/20 (20%)

OCF — opposite cortical fracture.

The absolute majority of type 1 (85.3%) and only 57.4% of type 2 fractures were already recognized intraoperatively ($p = 0.007$). The demographic distribution of the patients in both OCF groups (age, BMI, sex) was homogeneous (see Table 1).

As shown in Table 1, the degree of frontal correction was significantly higher with type 1 OCFs ($p = 0.038$). There was no significant difference between frontal osteotomy angles in the both groups (see Figure 2a). The proximal distance was nearly identical, but the medial distance was significantly greater with type 2 OCF ($p = 0.008$).

The mechanical complications (loss of correction, implant failure, or tibial pseudoarthrosis) were significantly more common in patients with OCFs (28.4% vs. 4.7%, $p < 0.001$, see Table 2). Such complications occurred somewhat more frequently after type 2 OCFs than after type 1 (34% vs. 20.6%). For both types, there was a significantly higher rate of mechanical complications with displaced OCFs ($p = 0.024$ for type 1 and $p < 0.001$ for type 2, see Figure 3).

In both groups, a reduction in the MPTA was detected at the time of the final recheck; however, the loss in correction was significantly higher in patients with type 2 OCFs ($p = 0.023$). In type 2 OCF, no significant difference in the MPTA change was detected between patients with primarily and secondarily displaced OCFs.

The incidence of tibial pseudoarthrosis was, as expected, significantly higher in patients with OCFs (16.1% vs. 0.9%, $p < 0.001$). This complication developed in 11.7% of type 1 OCFs and 19.1% of type 2 OCFs (not significant, n.s.). The tibial pseudoarthrosis rate was significantly higher with displaced type 2 OCFs than with non-displaced fractures in this group (30.8% vs. 4.8%, $p = 0.03$); for type 1 OCFs, no such difference was identified (see Figure 3).

No statistical difference was detected in both implants' groups regarding the rate of mechanical complications (n.s.) (loss of correction (n.s.), implant failure (n.s.), or tibial pseudoarthrosis (n.s.).

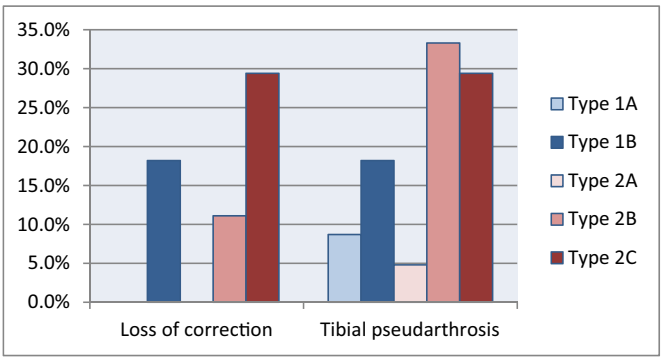

Figure 3. Bar-graph representing the incidence of mechanical complications with both fracture types.

The correlation analysis discovered a significant association between the fracture type and the preoperative varus angle ($\rho = -0.212$, $p = 0.027$), the degree of frontal correction ($\rho = -0.202$, $p = 0.038$), and the Δ MPTA ($\rho = -0.267$, $p = 0.023$); i.e., the greater these parameters are, the higher the likelihood that a type 1 OCF will occur (relative to type 2 OCF). The other important correlation was between the fracture type and the medial distance to the opposite cortex ($\rho = 0.302$, $p = 0.006$): the greater this distance is, the higher the risks are for the development of type 2 OCF (Figure 4).

The regression analysis showed a highly relevant association between OCF types 1B, 2B, and especially 2C and the incidence of mechanical complications (see Table 3); the significance of type 2C fractures (OR = 37.0, CI 9.7–141.4) in the development of mechanical complications and type 2B (OR 52.5, CI 4.7–583) and 2C fractures (OR 43.8, CI 4.7–406) in the incidence of tibial pseudoarthrosis is more than twice as high as for displaced type 1B fractures.

In the evaluation of the clinical outcome (median follow-up of 46.7 months), there was a highly significant improvement in all clinical scores postoperatively without any differences between patients without OCF and with type 1 or 2 OCF (see Table 4).

4. Discussion

HTO is a multidimensional corrective procedure. The development of this concept can be tracked using the example of the evolution of classification systems for OCF. OCF was first described as a complication in 1987 by *Hernigou* et al. [3]. In 2012, *Takeuchi* et al. published a classification of OCF in OWHTO, in which the fractures were classified into three types according to the course of the fracture line determined on a.p. radiographs [8]. However, this classification considers the fractures only in the frontal plane (i.e., two-dimensional). In 2017, *Nakamura* et al. defined five zones based on an analysis of postoperative CT, depending on the end of the OT line [9]. In 2017, *Ogawa* et al. described four types (A, B, C, D) in OWHTO according to the involvement of the anterior and posterior opposite cortex in the coronal CT slice [10].

The above-mentioned classifications consider OCF only in OWHTO. In contrast, no such classification has been published thus far for CWHTO. This study proposes a classification based on the analysis of 81 OCFs in 187 CWHTOs.

The central significance of any classification system lies in the consequences drawn for practical application based on the allocation. The focus of our classification is the stability of the CWHTO performed after an OCF has occurred. The stability depends on the extent to which the additional forces that arise (primarily shear forces) can be compensated for by extra- or intra-articular structures. For fractures of the medial opposite cortex in CWHTO, the medial capsular ligament can serve as a stabilizer as a result of ligamentotaxis. Anatomical studies demonstrate the distal insertion of the superficial medial collateral ligament (MCL) 46 to 60 mm and the deep MCL 10 to 14 cm distal to the tibial plateau [15]. In our patients with fractures of the medial opposite cortex, the tip of the osteotomy was situated 31.9 ± 6.6 mm from the tibial plateau ("proximal distance"); i.e., the differentiation line was exactly between the insertion points of the two parts of the MCL. In CWHTO, the medial opposite cortex fracture can occur either immediately during closure of the OT or, because of the lever mechanism at the distal tibia, during tightening of the distal cortical screw and the resulting shear forces [16]. Presumably, the remaining distal medial cortex in type 1 fractures of the proximal medial cortex can "provide support" and counteract the medial shear forces that arise (see Figure 1c). By contrast, this bony connection is lost in type 2 fractures, and the medial cortex located distally will slip into the varus position (=laterally) during weight bearing [5]; as a result, the distal cortex pushes against the proximal spongiosa, which provokes further instability and osteolysis [17] (see Figure 1d). Thus, subtypes A (non-displaced OCFs), B (primarily displaced), and C (secondarily displaced OCFs) can be differentiated. Type 2 OCFs demonstrated a substantial tendency to become displaced over time relative to type 1

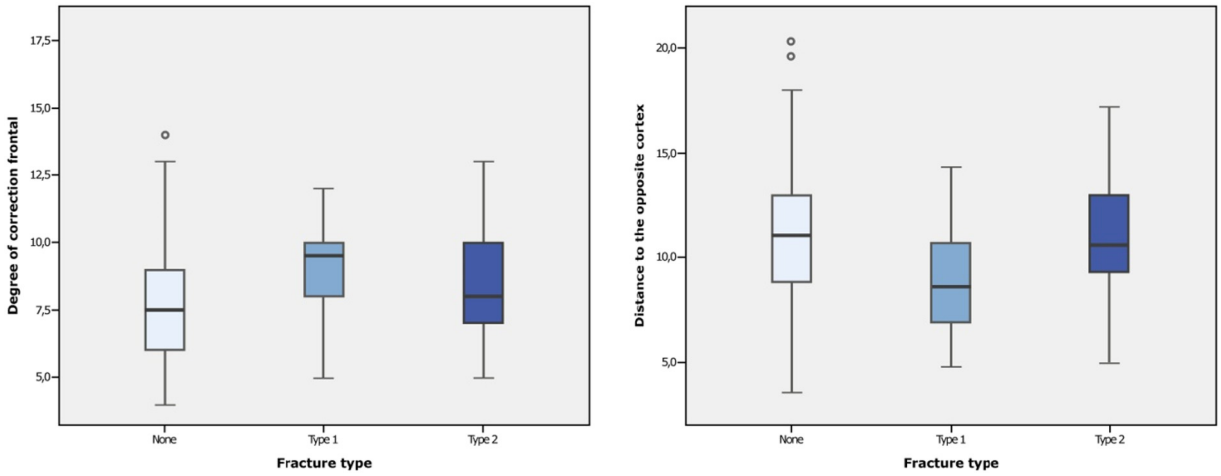

Figure 4. Box-plots graphs representing the correlations between fracture types and the degree of frontal correction (left) and the distance to the opposite cortex (right).

Table 3
Regression analysis of the various OCF types.

OCF type	Mechanical complications			Tibial pseudoarthrosis			Loss of correction		
	p	Exp(B)	CI	p	Exp(B)	CI	p	Exp(B)	CI
1A	n.s.	1.92	0.35–10.59	n.s.	10.0	0.87–115.39	NA	NA	NA
1B	<0.001	16.83	3.8–74.5	0.013	23.3	1.93–282.87	NA	NA	NA
2A	n.s.	1.01	0.11–9.11	n.s.	5.25	0.32–87.44	0.99	0.00	0.00
2B	0.001	16.16	3.29–79.42	**0.001**	**52.5**	**4.72–583.4**	0.92	8.63	0.71–105.5
2C	**<0.001**	**37.03**	**9.7–141.44**	**0.001**	**43.75**	**4.71–406.28**	**<0.001**	**28.75**	**5.03–164.24**

OCF — opposite cortical fracture, CI — confidence interval.

OCFs (36.2% type 2C (secondarily displaced) and no type 1C OCFs). Furthermore, type 1 OCFs in CWHTO can be considered to be stable and type 2 fractures unstable.

In our group of patients, potentially unstable type 2 fractures were primarily observed (58%, see Table 1). The relevant risk factors for the development of type 2 OCFs are the greater lateral distance between the tip of the osteotomy and the medial opposite cortex ($\rho = 0.302$, $p = 0.006$) and the smaller degree of frontal correction ($\rho = -0.202$, $p = 0.038$) relative to type 1 fractures. Only 57.4% of type 2 OCFs were recognizable intraoperatively; thus, increased attention must be focused on this potential event in postoperative repeat radiographs. No fractures of the lateral tibial plateau were detected; in the studies that have already been published, there is also no evidence of these fractures [5,8,22].

The main consequence of determining stability is the prognosis for resulting mechanical complications. The main risk is the secondarily displaced type 2C OCF with a 57.7% incidence of mechanical complications. Postoperative loss of correction occurred significantly more frequently after type 2 fractures than type 1 ($p = 0.023$). The tibial pseudarthrosis rate was also somewhat higher after type 2 fractures (19.1% vs. 11.7% after type 1, $p = 0.37$) and especially with types 2B and 2C (30.8% vs. 4.8% after type 1, $p = 0.03$). The overall incidence of tibial pseudarthrosis in patients with OCFs was 16.1% for displaced and 0.9% for non-displaced fractures ($p < 0.001$); thus, fracture displacement plays an absolutely crucial role for the development of mechanical complications. The regression analysis highlighted the especially important role of 2C fractures in the development of mechanical complications.

When type 1A, 1B, or 2A OCFs are detected radiologically, the follow-up treatment regimen should not be modified; for type 2A OCFs, additional repeat radiographs in the short term may be reasonable to promptly recognize secondary displacement (and thus conversion to type 2C). When type 2B and 2C OCFs are detected radiologically, the operated leg should initially have no weight bearing for six weeks or, presumably ideally, a re-osteosynthesis should be performed (see Figure 5).

There is no uniform opinion in the literature as to whether OCF leads to substantial complication rates. Some authors report no association between OCFs and the above-mentioned complications with both procedures [10,20,21]. In a biomechanical study, *Miller* et al. demonstrated a 58% reduction in axial stiffness and 68% reduction in torsion stiffness after OCF in OWHTO, which results in substantial micromotion on the OT side [6]. *Meidinger* et al. reported a tibial pseudarthrosis rate of 60% after OCF in OWHTO with angle-stable osteosynthesis [7]; *Takeuchi* et al. described a delayed bone healing rate of 40% after unstable type 2 fractures in OWHTO also with angle-stable osteosynthesis [8]. The other authors also demonstrated a significantly higher loss of correction in patients with OCFs with both procedures [10,22].

All of the CWHTOs in this study were performed with computer navigation; in their comparative analysis of 50 navigated and 50 non-navigated CWHTOs, *Bae* et al. did not describe any OCFs with either technique (2009) [19]. The only study published thus far with an analysis of medial OCFs in navigated CWHTOs was also published by *Bae* et al. in 2016. The incidence of non-displaced OCFs was 28.0%, and the incidence of displaced fractures was 6.5% (without further classification) in 200 navigated CWHTOs. The

Table 4
Change in the functional and pain score results (Δ) in patients with and without OCFs.

	CWHTO			
	Without OCF	Type 1	Type 2	p value
KOOS total	32.3 ± 25.7	32.9 ± 23.0	31.1 ± 23.6	n.s.
KOOS-S	33.4 ± 25.3	29.2 ± 25.6	30.6 ± 23.0	n.s.
KOOS-P	36.7 ± 27.5	38.4 ± 25.6	35.6 ± 25.8	n.s.
KOOS-A	32.3 ± 27.7	33.1 ± 25.1	28.4 ± 29.2	n.s.
KOOS-SP	26.9 ± 24.3	28.1 ± 25.9	27.1 ± 22.1	n.s.
KOOS-Q	27.9 ± 25.1	30.3 ± 23.7	28.0 ± 21.8	n.s.
Lysholm	33.1 ± 29.9	33.7 ± 30.9	31.6 ± 27.5	n.s.
VAS	−4.4 ± 3.2	−4.3 ± 3.2	−3.6 ± 3.5	n.s.

CWHTO — closed-wedge high tibial osteotomy, OCF — opposite cortical fracture, KOOS — knee injury and osteoarthritis outcome score, VAS — visual analogue scale, n.s. . not significant.

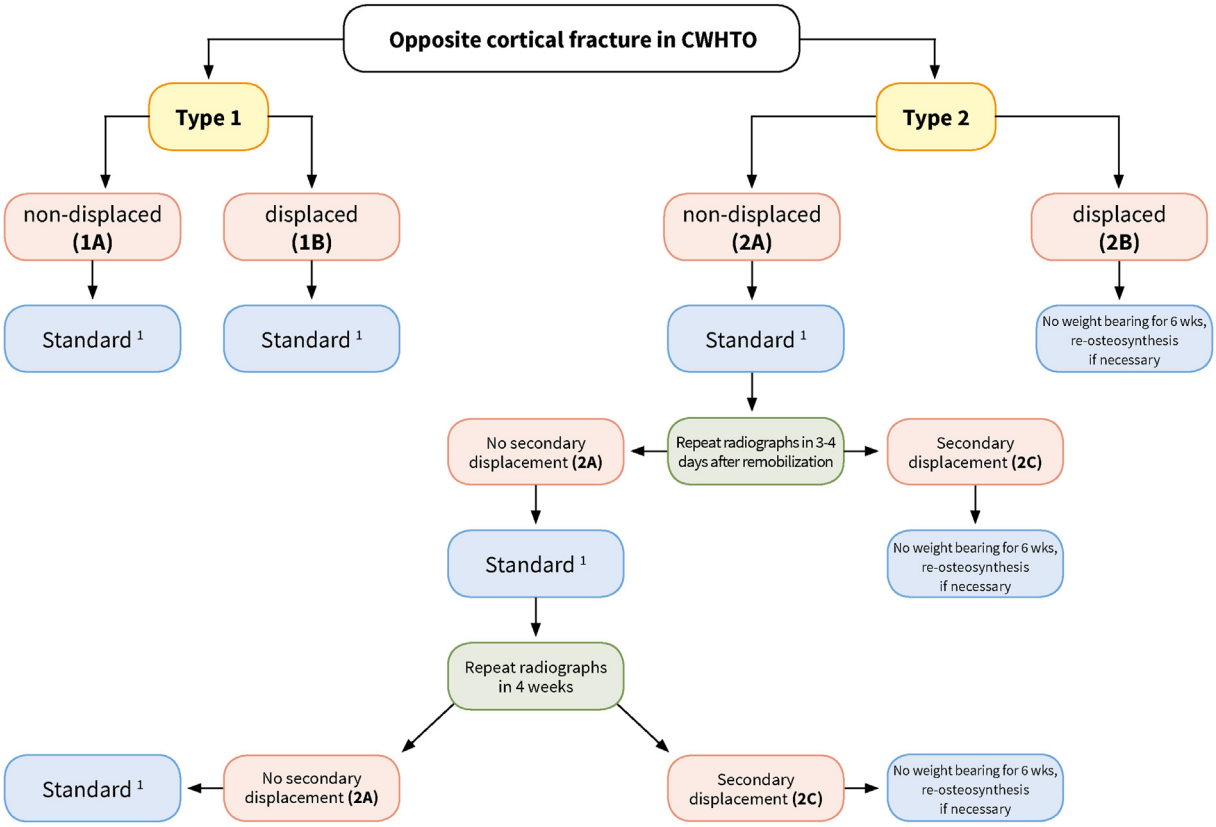

[1] Standard: Mobilization starting on the first postoperative day under partial weight bearing with 20 kg (for 6 weeks) without any immobilization. Then gradual increase in weight bearing until full weight bearing.

Figure 5. Algorithms for various OCF types. OCF — opposite cortical fracture, CWHTO — closed-wedge osteotomy

authors postulated that OCFs cannot be avoided, even by the use of navigation [18]. In both studies however, the osteotomies were carried out transversally and were fixed using a miniplate staple [18,19].

The present study has some limitations. First, the study was not prospective and randomized. Second, all the surgeries were performed by four different senior surgeons; however, the surgical procedure was standard in all cases. Third, changes in the MPTA were measured to determine the loss of correction over the course of the follow-up. In our opinion, the changes in the MPTA are more precise than the changes in the hip knee angle (HKA) because they reflect only the changes in the bone, whereas the changes in the HKA can occur due to a soft tissue imbalance or loss of cartilage. However, the MPTA was measured on long-film antero-posterior radiographs, which were performed routinely many times over the course of the follow-up; the full-leg-length radiograms were performed by most of the patients only once. This method of measurement is obviously not as precise as a measurement of the MPTA from full-leg-length radiograms. The correlation analysis demonstrated a strong positive significant correlation between the changes in the HKA and MPTA ($\rho = 0.782$, $p < 0.001$).

5. Conclusion

In summary, it appears to be important to promptly recognize OCFs (especially in the postoperative course) and to classify them. Based on the proposed classification, potentially unstable OCF types with an increased risk for the development of mechanical complications can be recognized and classified; thus, with appropriate modification of the follow-up treatment regimen or prompt re-osteosynthesis, a good functional result after CWHTO can be obtained despite the opposite cortical fracture.

Ethical statement

This study was discussed with the local ethics committee and it was decided that there is no alteration of the existing practice by this observational study; therefore it was approved without a formal research ethics committee application. All procedures were performed with the ethical standards of the institutional and national research committee and with the 1964 Helsinki declaration and its later amendments or comparable ethical standards.

Informed consent

In this study, formal informed consent was obtained from all participants.

Declaration of Competing Interest

This research did not receive any specific grant from funding agencies in the public, commercial, or not-for-profit sectors.

References

[1] Hernigou P, Medevielle D, Debeyre J, Goutallier D. Proximal tibial osteotomy for osteoarthritis with varus deformity. A ten to thirteen-year follow-up study. J Bone Joint Surg Am 1987:69–A: 332-54.
[2] Gstottner M, Pedross F, Leidensteiner M, Bach C. Long-term outcome after high tibial osteotomy. Arch Orthop Trauma Surg 2008;128:111–5.
[3] Akizuki S, Shibakawa A, Takizawa T, Yamazaki I, Horiuchi H. The long-term outcome of high tibial osteotomy: a ten- to 20-year follow-up. J Bone Joint Surg Br 2008;90(5):592–6.
[4] Amendola A, Bonasia DE. Results of high tibial osteotomy: review oft he literature. Int orthop 2010;34(2):155.
[5] Kessler OC, Jacob HA, Romero J. Avoidance of medial cortical fracture in high tibial osteotomy: improved technique. Clin Orthop Relat Res 2002 Feb(395):180–5.
[6] Miller BS, Dorsey WO, Bryant CR, Austin JC. The effect of lateral cortex disruption and repair on the stability of the medial opening wedge high tibial osteotomy. Am J Sports Med 2005 Oct;33(10):1552–7.
[7] Meidinger G, Imhoff AB, Paul J, Kirchhoff C, Sauerschnig M, Hinterwimmer S. May smokers and overweight patients be treated with a medial open-wedge HTO? Risk factors for non-union. Knee Surg Sports Traumatol Arthrosc 2011 Mar;19(3):333–9.
[8] Takeuchi R, Ishikawa H, Kumagai K, Yamaguchi Y, Chiba N, Akamatsu Y, et al. Fractures around the lateral cortical hinge after a medial opening-wedge high tibial osteotomy: a new classification of lateral hinge fracture. Arthroscopy 2012 Jan;28(1):85–94.
[9] Nakamura R, Komatsu N, Fujita K, Kuroda K, Takahashi M, Omi R, et al. Appropriate hinge position for prevention of unstable lateral hinge fracture in open wedge high tibial osteotomy. Bone Joint J 2017 Oct;99-B(10):1313–8.
[10] Ogawa H, Matsumoto K, Akiyama H. The prevention of a lateral hinge fracture as a complication of a medial opening wedge high tibial osteotomy: a case control study. Bone Joint J 2017 Jul;99-B(7):887–93.
[11] Roos EM, Roos HP, Lohmander LS, Ekdahl C, Beynnon BD. Knee injury and osteoarthritis outcome score (KOOS) – development of a selfadministeredoutcome measure. J Orthop Sports Phys Ther 1998;28:88–96.
[12] Lysholm J, Gillquist J. Evaluation of knee ligament surgery results with special emphasis on use of a scoring scale. Am J Sports Med 1982;10(3):150–4.
[13] Haefeli M, Elfering A. Painassessment. Eur Spine J 2006;15(Suppl1):17–24.
[14] Fujisawa Y, Masuhara K, Shiomi S. The effect of high tibial osteotomy on osteoarthritis of the knee. An arthroscopic study of 54 knee joints. Orthop Clin North Am 1979;10:585–608.
[15] Robinson JR, Sanchez-Ballester J, Bull AM, Thomas Rde W, Amis AA. The posteromedial corner revisited. An anatomical description of the passive restraining structures of the medial aspect of the human knee. J Bone Joint Surg Br 2004 Jul;86(5):674–81.
[16] Pape D, Adam F, Rupp S, Seil R, Kohn D. Stabilität, Knochenheilung und Korrekturverlust nach valgisierender Tibiakopfumstellung. Eine Rönrgenstereometrieanalyse Orthopäde 2004 Feb;33(2):208–17.
[17] Miniaci A, Ballmer FT, Ballmer PM, Jakob RP. Proximal tibial osteotomy: a new fixation device. Clin Orthop Relat Res 1989 Sep;246:250–9.
[18] Bae DK, Park CH, Kim EJ, Song SJ. Medial cortical fractures in computer-assisted closing-wedge high tibial osteotomy. Knee 2016 Mar;23(2):295–9.
[19] Bae DK, Song SJ, Yoon KH. Closed-wedge high tibial osteotomy using computer-assisted surgery compared to the conventional technique. J Bone Joint Surg Br 2009 Sep;91(9):1164–71.
[20] Nelissen EM, van Langelaan EJ, Nelissen RG. Stability of medial opening wedge high tibial osteotomy: a failure analysis. Int Orthop 2010 Feb;34(2):217–23.
[22] Spahn G. Complications in high tibial (medial opening wedge) osteotomy. Arch Orthop Trauma Surg 2004 Dec;124(10):649–53.
[21] van Houten AH, Heesterbeek PJ, van Heerwaarden RJ, van Tienen TG, Wymenga AB. Medial open wedge high tibial osteotomy: can delayed or nonunion be predicted? Clin Orthop Relat Res 2014 Apr;472(4):1217–23.