Check for updates

Microsurgical Anatomy and Approaches to the Cerebral Central Core

Matias Baldoncini[1,2], Alvaro Campero[2,3], Julio César Pérez Cruz[4], Rodolfo Recalde[5], Richard Parraga[6,7], Federico J. Sanchez Gonzalez[8,9], Martin Fortte[10,11], Pablo González López[12]

■ OBJECTIVE: **Through a cadaveric study, we divided the cerebral central core (CCC) into different areas and have proposed a corresponding neurosurgical approach for each sector. As a secondary objective, we analyzed the cortical and subcortical microsurgical anatomy of the CCC. The CCC includes the insula, extreme capsule, claustrum, external capsule, lenticular nucleus, internal capsule, caudate nucleus, and thalamus.**

■ METHODS: **Twelve adult human brain hemispheres and one cadaveric head specimen were dissected and studied at the Laboratory of Neuroanatomic Microsurgical of the University of Buenos Aires. Nine cases of CCC neurosurgical pathologies were included in the present study and analyzed. Digital drawings were created of the approaches proposed for each sector of the CCC showing the most relevant surgical details. Photographs of each dissection and measurements obtained were taken.**

■ RESULTS: **We divided the CCC into a medial, intermediate, and lateral sector, with specific subdivisions for the lateral and medial sectors. The lateral projection of the foramen of Monro was found deep to the third short gyri of the insula with the following distances: anterior insular limen margin, 23.95 mm; posterior insular limen margin, 22.92 mm; superior limiting sulcus, 14.99 mm, and inferior limiting sulcus, 13.76 mm. We have proposed the following approaches: an ipsilateral transcallosal approach, a contralateral transcallosal approach, a choroidal transfissure approach, a trans-splenial approach, transparietal access entering the intraparietal sulcus, and trans-sylvian approach. The preoperative imaging studies should be analyzed using our method to select the most accurate and safe approach.**

■ CONCLUSIONS: **We have provided a description of the limits and anatomy of the CCC using brain dissection, an analysis of operated cases, and useful measurements for the neurosurgeon.**

INTRODUCTION

The cerebral central core (CCC) is a topographical area located between the sylvian cistern laterally and the third ventricle medially. It has been described as a block that rests over the midbrain. It includes the insular cortex, extreme capsule, claustrum, external capsule, lenticular nucleus, internal capsule, caudate nucleus, and thalamus. In addition, it is surrounded by a group of short and long association commissural and projection fibers. This white substance, located between the peri-insular and lateral ventricle grooves, is known as the cerebral isthmus.[1] It connects the nucleus of the central core with the rest of the hemisphere. It also anatomically separates the sylvian cistern from the ventricular system. As the topographic center of

Key words
- Cerebral central core
- Microsurgery
- Neurosurgical approaches
- Neuroanatomy

Abbreviations and Acronyms
AC: Anterior commissure
CCC: Cerebral central core
LPFM: Lateral projection foramen of Monro

From the [1]Department of Neurological Surgery, San Fernando Hospital, Buenos Aires, Argentina; [2]Laboratory of Neuroanatomic Microsurgical, II Division of Anatomy, Medicine School, University of Buenos Aires, Buenos Aires, Argentina; [3]Department of Neurological Surgery, Padilla Hospital, Tucumán, Argentina; [4]Anatomy Academy, Higher School of Medicine, Instituto Politécnico Nacional Neurosciences, Faculty of Medicine, Autonomous National University of Mexico, Mexico City, Mexico; [5]Skull Base Section and Neuroanatomic Laboratory, Neurosurgical Division, Clinical Hospital, University of Buenos Aires, Buenos Aires, Argentina; [6]Department of Neurological Surgery, Hospital Univalle, Cochabamba-Cercado, Bolivia; [7]Institute of Neurological Sciences, São Paulo, Brazil; [8]Epilespy Surgery Section, Neurosurgical Division, Clinical Hospital, University of Buenos Aires, Buenos Aires, Argentina; [9]Neurosurgical Division, Clinic of Cuyo, Mendoza, Argentina; [10]Division Neurosurgery, Interzonal Specialized Children's Hospital, Mar del Plata, Argentina; [11]Belgrano Clinic and 25 de Mayo Clinic, Mar del Plata, Argentina; and [12]Department of Neurosurgery, Hospital General of Alicante, Alicante, Spain

To whom correspondence should be addressed: Matias Baldoncini, M.D.
[E-mail: drbaldoncinimatias@gmail.com]

Citation: World Neurosurg. (2019) 129:e23-e34.
https://doi.org/10.1016/j.wneu.2019.04.139

*Journal homepage: **www.journals.elsevier.com/world-neurosurgery***

*Available online: **www.sciencedirect.com***

1878-8750/$ - see front matter © 2019 Elsevier Inc. All rights reserved.

the brain, it integrates various types of sensitive, motor, cognitive, and emotional information. A few investigators[2-4] have recognized the CCC as a different region in the brain and highlight the importance of surgical planning. From a strictly neurosurgical point of view, its differentiation will be useful, because it contains eloquent structures of deep localization, with complex cisternal and ventricular relationships. Thus, we divided the CCC and proposed different neurosurgical approaches for each sector for the pathological entities located within this important anatomical region.

METHODS

The cortical and subcortical anatomy of the CCC was studied in 12 adult human cerebral hemispheres in the Laboratory of Microsurgery Neuroanatomy of the II Division of Anatomy of the University of Buenos Aires. Axial and coronal sections were taken in 2 cerebral hemispheres. Next, brain staining was performed using the Mulligan technique.[5] The remaining hemispheres were fixed in 10% formaldehyde for 1 month and then frozen for 30 more days, following the guidelines of Ludwig and Klingler[6] and of other investigators.[7] It is through this technique that the expansion of the water that exists between the cerebral fascicules can form ice crystals, thus facilitating their dissection.

We used a human head, previously injected with red and blue silicone and fixed with aqueous solution of 10% diluted formaldehyde for 30 days. After performing the craniotomy, it was frozen for 1 month, allowing for the combination of the coloration of the central core vessels and dissection of the nuclei and fascicles that constitute it. Using the technique proposed by Ribas et al.,[4] morphometric data were obtained from the 12 hemispheres, which had been transfixed with pins from the medial side through the foramen of Monro to analyze its projection on the insular surface. After obtaining the lateral projection of the foramen of Monro (LPFM), the distance from this point to the upper and lower limiting groove of the insula was measured. Finally, 2 coronal planes were drawn to delimit the anterior and posterior edge of the lenticular nucleus, termed the anterior and posterior lenticular margin, respectively. All measurements were obtained manually on each specimen using a digital caliper.

Two magnification microscopes of 6×, 10× and 40×, blunt instruments, and diaeresis elements were used to perform the dissections, including curved and straight microsurgery scissors, straight micro-tweezers, Penfield model no. 7 straight and curved, and wooden and cerebral spatulas, straight and curved. The photographs were taken using a Nikon D7200 camera with a Micro Nikon 40mm F2.8 lens and annular flash (Nikon, Tokyo, Japan). This was configured using a variable diaphragm, with a shutter speed of 100, ISO 250, and ring flash 1/128.

Finally, we have described the different strategies for the neurosurgical approaches for pathological entities of the CCC according to the proposed topographic division, after performing them in cadavers at the University of Buenos Aires Laboratory of Neuroanatomic Microsurgical and patients treated at the Neurosurgery Service of the Petrona Villegas Cordero Hospital of San Fernando, Buenos Aires. To complete our research, we incorporated digital drawings created specifically for our report to highlight the anatomy of the region and the microsurgical division through the cranial approaches.

RESULTS

Anatomy of CCC

The lateral side of the CCC corresponds to the insular surface that is in the depth of the sylvian cistern when retracting the fronto-parietal and temporal operculum. The insular surface is surrounded by the circular groove composed of an anterior, superior, and inferior limiting sulcus. The circular sulcus is interrupted at the inferior anterior border of the insular surface by the insular limen, which presents as a C-shape and has upper and lower points.[4,8-13]

The upper point of the limen joins the anterior limiting sulcus in the frontal lobe, termed the frontal limen point by Ribas et al.[4] The lower point joins the lower limiting groove in the temporal lobe and has been referred to as the "temporal limen point."[4]

The anterior limiting sulcus extends from the frontal limen point to the point where it intersects with the upper limiting sulcus, referred to as the anterior insular point, and coinciding on the surface of the sylvian fissure with the anterior sylvian point. The upper limiting groove continues toward the posterior edge of the insula, reaching the so-called posterior insular point,[4,9] at which it joins with the inferior limiting groove. The inferior limiting sulcus extends from the posterior insular point to the temporal limen point. The medial aspect is limited inferiorly by the hypothalamic sulcus, anteriorly by the head of the caudate nucleus, and superiorly by the body of the caudate nucleus, crossing on its trajectory the septal area, fornix, third ventricle, frontal horn, and body of the lateral ventricle.

The CCC anterior surface is an imaginary plane that extends from the anterior limiting sulcus, passes through the anterior edge

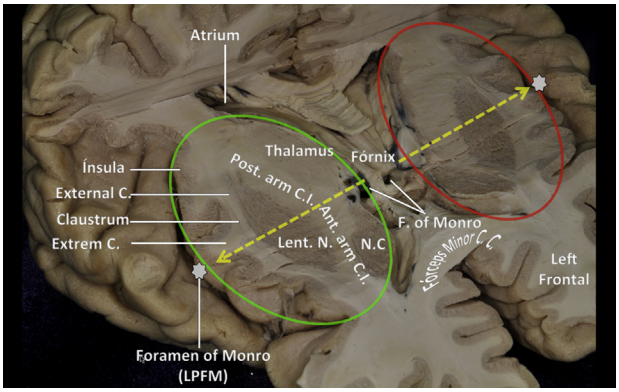

Figure 1. An axial section is shown at the frontoparietal level that crosses both cerebral central core centers at the point of the foramen of Monro. The projection of the foramen on the insular surface (LPFM) was graphed with *yellow arrows*. In the *green ellipse*, the right central core is delimited and the left, in *red*. In front of and behind the lenticular nucleus, the extreme capsule, external and internal, continue without a demarcation plane. Thus, measurements were made from these margins to the projection of the foramen of Monro.

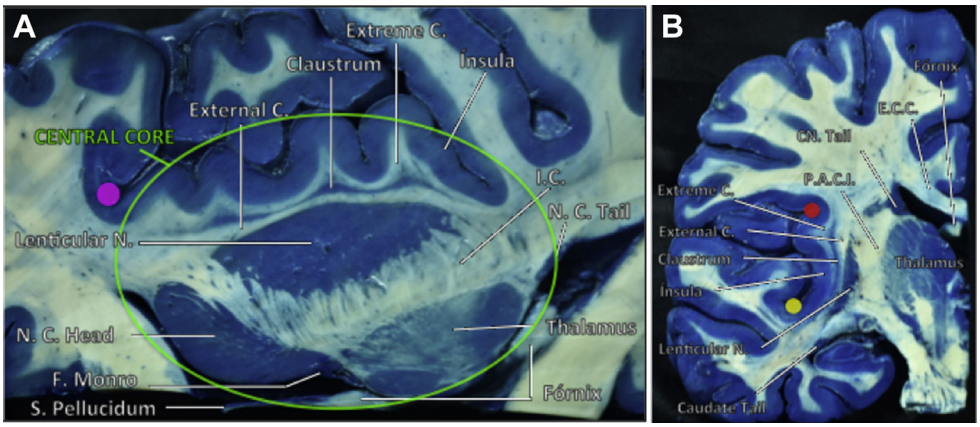

Figure 2. (**A**) An axial section can be observed above the foramen of Monro, where it has been stained with the Mulligam technique to highlight in *blue* the gray structures of the cerebral core central (CCC). In a *green circle,* the right CCC can be seen, viewed from above with its constituent structures. A *magenta circle* points to the anterior limiting groove of the insula. It is worth noting that in this section, one can identify the anterior and posterior limits of the CCC.[4] (**B**) Coronal section of the right cerebral hemisphere at the level of the thalamus, in a *red circle,* indicating the superior limiting groove of the insula and in *yellow,* the inferior.

of the head of the caudate nucleus, and ends at the anterior horn of the lateral ventricle superiorly and the anterior border of the septal region inferiorly (Figures 1–3). The upper edge is represented by a plane connecting the upper boundary groove at the level of the body and atrium of the lateral ventricle, just above the body of the caudate nucleus.

The posterior border of the cerebral central core is a line joining the posterior insular point to the posterior border of the pulvinar nucleus, crossing the anterior border of the atrium of the lateral ventricle.[4] The lower edge of the central core is represented by a medially directed plane connecting the inferior limiting sulcus of the insula to the atrium and to the temporal horn of the lateral ventricle.

Lateral Structures of the CCC

The insula is triangular in shape, with the apex directed anteriorly and inferiorly toward the insular limen, which is a slight relief of the cortex that covers the uncinate fascicle. It is surrounded by the circular sulcus, which can be divided into 3 edges: anterior, superior, and inferior.[14-17] The anterior border is located in the depth of the pars triangularis of the lower frontal gyrus. The upper border separates the insula from the frontal and parietal lobes. Finally, the lower edge separates the insula from the temporal lobe.

The insular sulci and gyri are directed superiorly in a radiated fashion from the apex to the insular limen.[15] The central sulcus of the insula is a relatively constant groove that extends from inferiorly to superiorly and from anteriorly to posteriorly, practically parallel to the central groove in the convexity. It divides the insula into an anterior lobe formed by short island turns and a posterior lobe formed by long, anterior and posterior turns.[17]

Below the insular cortex, a thin group of short association fibers, termed the extreme capsule, will be uncovered. This system connects the insular turns adjacent to each other and projecting into the depth of the upper and lower limiting sulcus to the opercular areas.[17-19] Removing these thin fibers, one will find the claustrum and external capsule, both divided into a ventral and dorsal portion. The dorsal external capsule is formed by claustrocortical projection fibers that connect the claustrum and cortex between the supplementary motor cortex anteriorly and the posterior portion of the parietal lobe posteriorly. The external ventral capsule is formed by the inferior occipital frontal fasciculus above and the uncinate fasciculus below. The dorsal claustrum is located between the extreme and external capsule. The ventral claustrum is formed by islets of gray substance interposed in the ventral external capsule that extends laterally to the amygdaloid nucleus.

The uncinate fascicle is composed of long association fibers that connect the frontal and temporal lobes. It is located deep at the edge of the insula, assuming its "hook-shape" morphology. It is found in the inferior portion of the anterior limiting sulcus and the anterior portion of the inferior limiting sulcus.

The inferior fronto-occipital fasciculus connects the superior and middle frontal gyri to the temporal, parietal, and occipital lobes. It is immediately superior to the uncinate fascicle and has a concave portion that encompasses the lower surface of the putamen nucleus.

The lenticular nucleus is located between the internal and external capsule. It is divided into 3 segments by 2 layers of white matter, the medial and lateral medullary laminae.[19,20] The lateral segment, the putamen, is the most prominent of the 3. The 2 remaining segments form the pallidum globe. The putamen has a darker color and is larger than the pallidum. The pallidum presents with a greater consistency and a lighter appearance owing to the greater amount of fibers running through it.

In a coronal section through the cerebral hemispheres (Figure 2B), the lenticular nucleus has a triangular shape and 3 faces (lateral, superomedial, and inferior). The lateral surface is

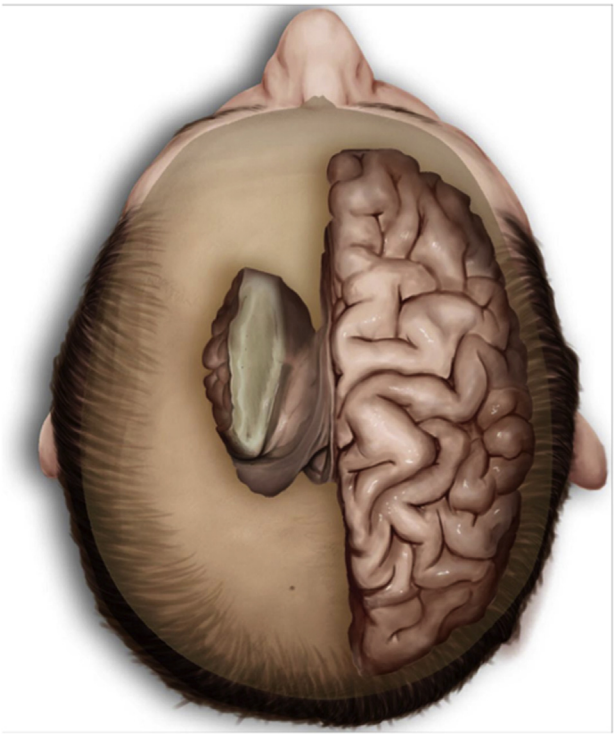

Figure 3. Artistic illustration and graphic representation of the left cerebral central core (CCC), highlighting the ventricular surface of the caudate nucleus, ventricular surface of the left thalamus, and the fornix covering the dorsal surface of the thalamus, forming the choroidal cleft. This fissure divides the medial segment of the CCC into a ventricular and cisternal sector. The ventricular sector is related to the frontal horn, body, and atrium of the lateral ventricle and to the thalamic surface of the third ventricle. It is this division of the medial CCC that we have proposed because it allows for its classification in relation to the different approaches for accesses to the neurosurgical pathological features of this area.

separated from the insular cortex by a layer of white matter, which, in turn, is subdivided into 2 by a thin layer of gray substance, the claustrum, in the extreme and external capsule. The superomedial surface corresponds to the internal capsule, and, in its anterior portion, it has a bridge of gray substance that connects with the head of the caudate nucleus, termed the striated body segment. The inferior surface is related to the anterior commissure (AC) and is separated from the temporal horn of the lateral ventricle through a layer of neural tissue where the tail of the caudate nucleus can be recognized.[4,20]

The AC is a fascicle of interhemispheric commissural fibers that crosses the ventral surface of the CCC and, in this sector, is a part of it. It mainly connects different regions of the temporal lobes. When it crosses the midline, it appears in close relation to the anterior perforated substance. Next, the AC bifurcates into a ventral extension in relation to the olfactory sulcus and a lateral extension directed toward the temporal lobe. The lateral extension is covered by a layer of tissue, which represents the so-called Gatriolet canal, and is formed by the anterior surface of the pallidum.

Table 1. Measurements of Distances From Lateral Projection of Foramen of Monro to Upper and Lower Insular Limiting Sulcus and Anterior and Posterior Lenticular Insular Margins

Hemisphere	LPFM-SLS (mm)	LPFM-ILS (mm)	LPFM-AILM (mm)	LPFM-PILM (mm)
1	20.61	14	20.59	21.49
2	17.78	12.53	23.68	20.79
3	11.62	14	22.19	19.81
4	16.35	13.53	21.98	24.60
5	11.82	14	24.20	26.64
6	16.35	13.53	28.65	24.20
7	11.82	9.88	27.77	23.15
8	10.60	10.90	27.74	22.53
9	10.50	14.39	22.85	18.37
10	18.79	20.81	21.79	23
11	17.67	12.63	24.68	27.33
12	16	15	21.35	23.22
Average	14.99	13.76	23.95	22.92

LPFM, lateral projection foramen of Monro; SLS, superior limiting sulcus; ILS, inferior limiting sulcus; AILM, anterior insular limen margin; PILM, posterior insular limen margin.

The external capsule and claustrum can be divided into ventral and dorsal portions. The dorsal external capsule is formed by claustrocortical projection fibers that connect the claustrum and cortex between the supplementary motor cortex anteriorly and the posterior portion of the posterior parietal lobe. The external ventral capsule is formed by the lower fronto-occipital fasciculus above and the uncinate fasciculus below. Toward the medial aspect, we also found a small group of fibers dependent on the AC, which were directed anteroposteriorly toward the parietal region. The dorsal claustrum is located between the extreme and external capsule. The ventral claustrum is formed by islets of gray matter interposed in the ventral outer capsule that extends laterally to the amygdaloid nucleus.[20]

Intermediate Structures of the CCC

The internal capsule represents the projection fibers located between the lenticular nucleus laterally and the caudate and thalamus medially. It continues superiorly with the radiated crown, and inferiorly with the cerebral peduncles of the midbrain. In an axial plane through the cerebral hemispheres (Figures 1 and 2), the internal capsule has a "V" shape, with the medial vertex directly related to the foramen of Monro and, therefore, the division between the frontal horn and central portion of the lateral ventricle. The internal capsule can be divided into 5 portions: the anterior limb, between the head of the caudate and the lenticular nuclei; the genu in direct relation with the foramen of Monro; the posterior limb, between the thalamus and lenticular nucleus; the retrolenticular portion behind the lenticular nucleus; and, finally, a sublenticular portion below it.

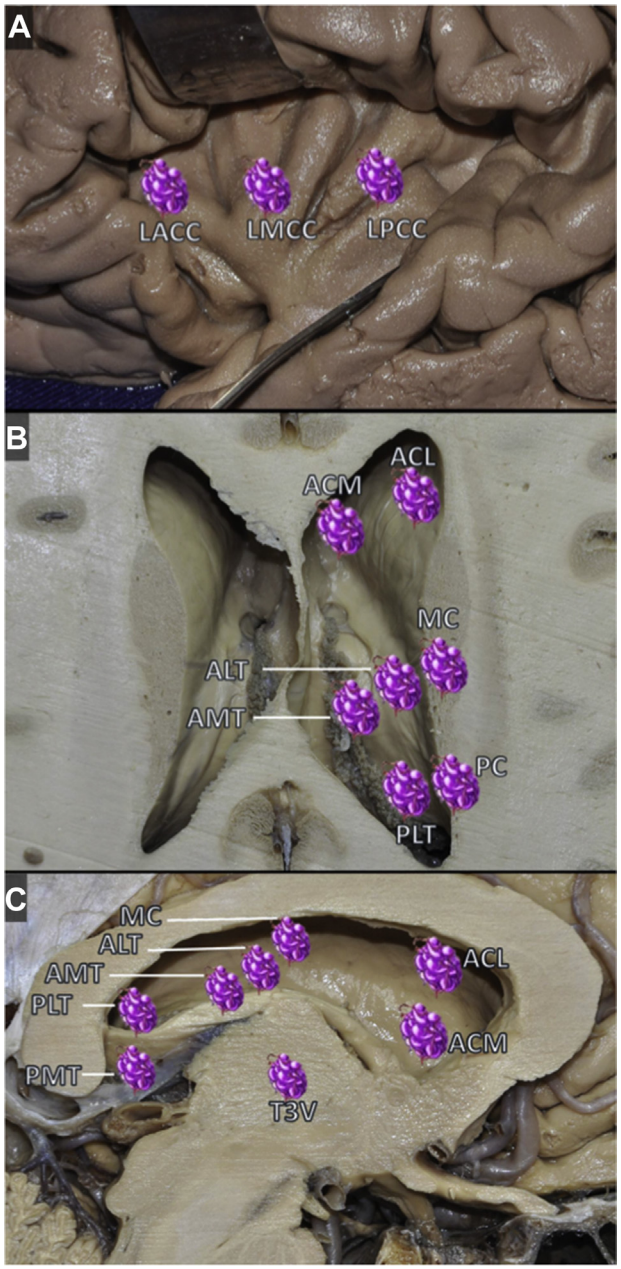

Figure 4. Graphic representation of dissection of injuries in the cerebral central core (CCC) according to the proposed classification. (**A**) Opening of Sylvian fissure where the insular surface can be observed. (**B**) Axial section over the lateral ventricles where the dorsal surface of the medial CCC can be observed. Related to the anterior horn of the lateral ventricle is the head of the caudate nucleus, which we divided into a medial sector and a lateral sector. In the central portion, or body of the lateral ventricle, is the medial thalamus and body of the caudate nucleus laterally. We have proposed a division in the anterior medial thalamus (AMT), corresponding to the dorsal surface of the thalamus in the vicinity of the choroidal fissure. (**C**) Sagittal section of the brain, observing the CCC from the medial side. ACL, anterior lateral caudate; ACM, anterior medial caudate; ALT, anterior lateral thalamus (surface related to the body of the NC); LACC, lateral anterior central core; LMCC, lateral medial central core; LPCC, lateral posterior central core; MC, middle caudate (corresponding to body of NC); MPT, medial posterior thalamus (corresponding to surface of medial pulvinar to choroidal fissure in relation to quadrigeminal cistern); NC, caudate nucleus; PC, posterior caudate (tail of NC at atrial level); PLT, posterior lateral thalamus (corresponding to ventricular pulvinar surface [atrium]); T3V, thalamus of third ventricle (extending from choroidal fissure to hypothalamic sulcus of ventricular surface).

Medial Structures of the CCC

The thalamus is an ovoid structure located above the mesencephalon, it has medial, lateral, superior, inferior, anterior, and posterior surfaces. The lateral surface is convex and adherent to the caudate nucleus superiorly and to the posterior segment of the internal capsule inferiorly. The medial surface has an ependymal surface called the ventricular surface and an extraventricular or cisternal surface, related to the quadrigeminal cistern. It forms the lateral wall of the lateral ventricle in its anterior two thirds and is related to the superior colliculus in its posterior third. The upper surface is divided by the medullary thalamic stria into 2 halves: medial and lateral. The lateral half is related to the caudate nucleus and constitutes the lateral body floor of the lateral ventricle. The medial half is related to the choroidal tissue and the fornix; the lower surface lies on the mesencephalon. The posterior border, represented by the pulvinar nucleus, is subdivided by the choroidal fissure in a medial or quadrilateral and lateral or ventricular segment.[8,11,12] This is very important because it allows for the division of this sector according to the surgical approach to be used. The anterior border can be divided by medial and lateral halves. The lateral half is related to the head of the caudate nucleus, and the medial half forms the posterior limit of the foramen of Monro.

The caudate nucleus is divided into the head, body, and tail.[9,11,16] The head is located in the lateral aspect of the anterior border of the thalamus, and the body is located on the upper surface of the thalamus. The fornix is formed by hippocampal mammillary fibers that originate in the hippocampus, subiculum, and dentate gyrus of the temporal lobe. It then runs posterosuperiorly to become the fornix crura.[11] Both crura join at the confluence of the atrium with the body of lateral ventricle to form the body of the fornix, which runs anteriorly through the superomedial edge of the thalamus, to the anterior edge, where it divides into 2 columns that curve to form the anterior limit of the foramen of Monro. This structure is related to the lateral ventricle. The body of the fornix is located in the medial portion of the body of the lateral ventricle, the crura of the fornix are located on the medial border of the atrium; and the fimbria of the fornix are found in the medial aspect of the temporal horn.

The choroidal fissure is a cleft between the thalamus and the fornix, where the lateral ventricles of the choroidal plexus adhere and through which the anterior choroidal and medial posterolateral artery can be exposed.[11] It presents a "C" shape that extends from the foramen of Monro, through the body and atrium and, finally, to the temporal horn of the lateral ventricle. Therefore, this fissure extends around the inferior, superior, and posterior surfaces of the thalamus. It can be divided into a body, between the body of the fornix and the thalamus, an atrial portion between the crura of the fornix and the pulvinar nucleus of the

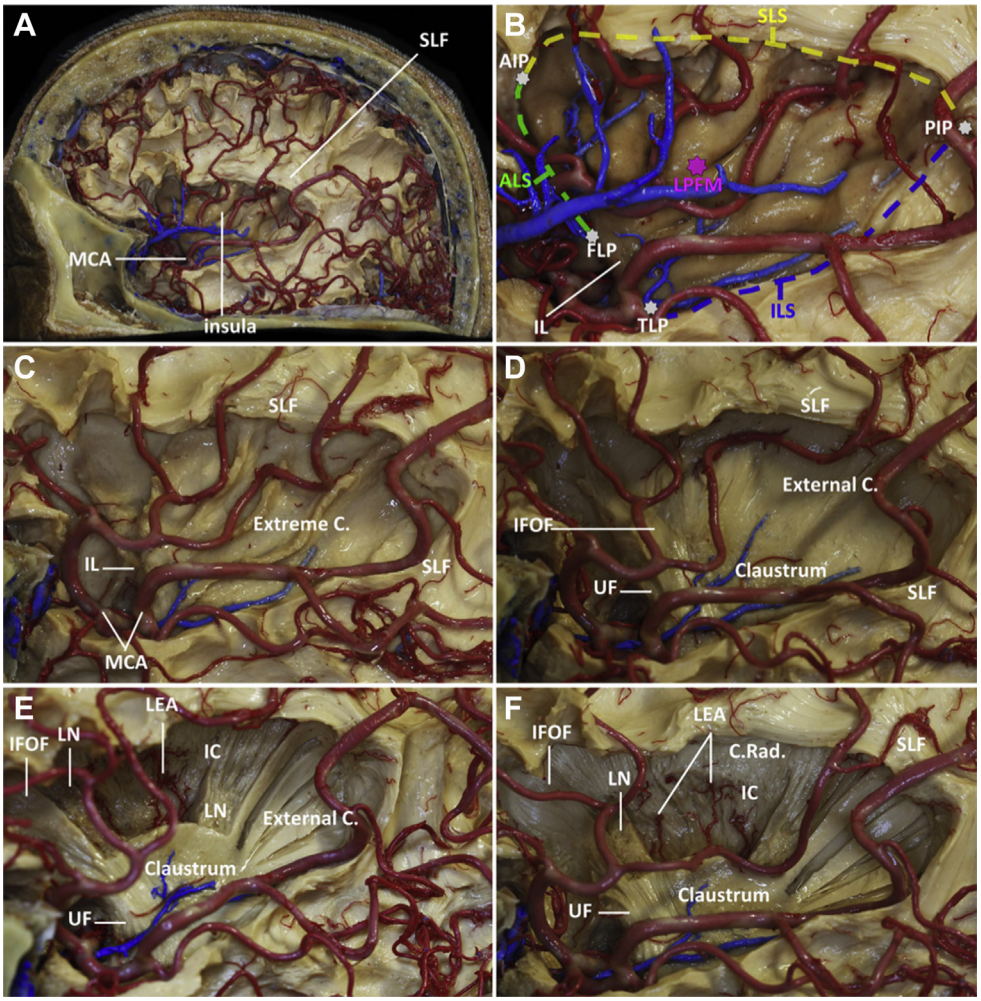

Figure 5. (**A**) In the first step of the dissection, the cranial bone is removed. Next, the cortex of the lateral surface of the left cerebral hemisphere is retracted to expose the superior longitudinal fasciculus (SLF) with its pars arcuata, in intimate relationship with the superior and inferior limiting sulcus (SLS and ILS, respectively) of the insula. The middle cerebral artery (MCA) can be observed. (**B**) Photograph showing greater localized increase over the lobe of the left insula. IL, insular limen anterior (ALS; *green*), superior (SLS; *yellow*), and inferior limiting sulcus (ILS; *blue*) of the insula. Indicated by *white points*: FLP, frontal limen point; AIP, anterior insular point; PIP, posterior insular point; TLP, temporal limen point. The lateral projection foramen of Monro (LPFM) has been demarcated with a *magenta dot*: *white lines* in front and behind it indicate coronal direction projecting the anterior and posterior lenticular insular margins. (**C**) After removing the cortex from the short and long gyrus of the insula, a thin layer of fibers termed the extreme capsule can be observed, which will be thicker at the points at which the insular turns were previously found but thinner at the site of the sulcus. (**D**) Below the extreme capsule, we found a thin layer of gray substance called claustrum. Under it will be a group of fibers called the external capsule; both can be divided into a dorsal and a ventral sector. In the most anterior sector of the insular external surface, and below the cortex of the limbus, a group of long association fibers will be found. In this step of the dissection, the limiting sulcus of the insula can be conserved, because the central core is developed within them. Injected with *red silicone*, the middle cerebral artery can be observed with its upper and lower branches. The latter is related to the lower limiting groove and the upper branch flanges to its M2 branches on the insular surface, directly related to the superficial core sector. (**E**) The external capsule was removed to reveal the lateral surface of the lenticular nucleus (LN), considered an external shield of a gray substance that protects the internal capsule. After removing part of the putamen and pallidum, the lateral lenticulostriate arteries can be identified, and medial to them, the fibers of cephalocaudal orientation can be seen. The internal capsule (IC) can be seen, which extends beyond the anterior and posterior margins of the lenticular nucleus. (**F**) The last step of dissection of the central core from laterally, where the presence of the internal capsule with its anterior arm, posterior arm, and knee is highlighted, demarcated in an ovoid manner by the morphology printed on the medial side of the lenticular nucleus. Important anatomical and microsurgical data showed the absence of a demarcation between the extreme, external, and internal capsules in the periphery of the lenticular nucleus. Therefore, we performed the measurements in the coronal plane of the anterior and posterior limits of the same, represented in *broken lines*, denominating them: anterior and posterior lenticular insular margins. UF, unciform fasciculus; IFOF, inferior fronto-occipital fasciculus.

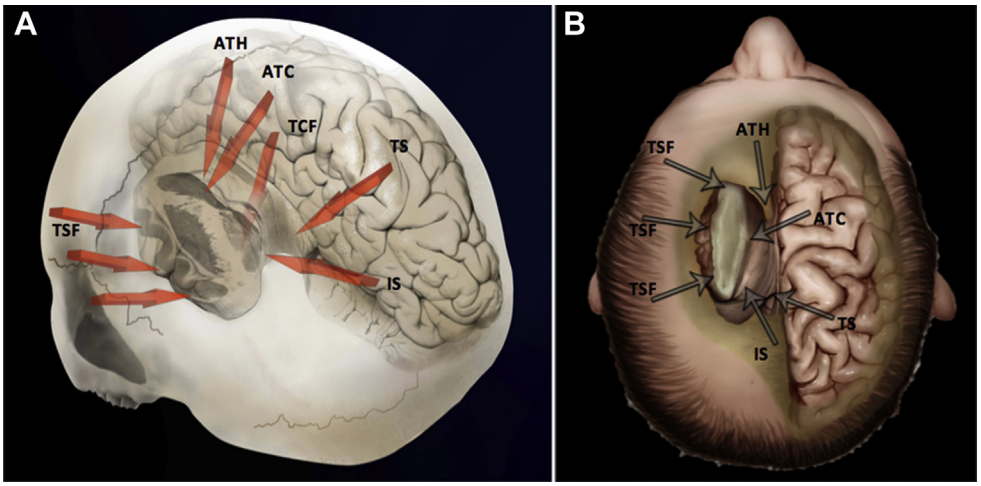

Figure 6. (**A, B**) Artistic illustrations of the approaches to the left cerebral central core. ATC, anterior transcallosal contralateral (provides access to lateral thalamus and lateral caudate lesions); ATH, anterior transcallosal homolateral (for access to dorsal and medial intraventricular surface of thalamus and caudate nucleus); IS, transparietal access (entering intraparietal sulcus into ventricular atrium with direct vision of pulvinar of intraventricular thalamus and tail of caudate nucleus); TCF, transchoroidal fissure (for thalamic lesions in the third ventricle); TS, trans-splenium (approach allows access to cisternal surface of pulvinar of thalamus); TSF. trans-Sylvian fissure (approach to access lateral cerebral central core).

thalamus, and a temporal portion between the fimbria of the fornix and the stria terminalis (or thalamostriate sulcus) on the ventral side of the thalamus. Opening the body portion will expose the third ventricle, the atrial portion allows for access to the quadrigeminal cistern, and the temporal portion will expose the ambient cistern.[11,21]

Measurements of the CCC

On the 12 cerebral hemispheres, the LPFM was demarcated and the distances between this point and the anterior insular limen margin and posterior insular limen margin were measured. The distances between the LPFM and the superior and inferior limiting sulci of the insula were also measured. The results are presented in Table 1.

Subdivisions of the CCC

For neurosurgical purposes, divisions of the CCC have been made for insular gliomas[22-25] and cavernomas located at the level of the thalamus.[26-29] However, to the best of our knowledge, no studies have presented the different neurosurgical approaches to the CCC by dividing the CCC into different regions. Thus, we divided the CCC into medial, intermediate, and lateral sectors (Figure 4 and 5).

The medial structures include the thalamus and caudate nucleus. The lateral components include the putamen, pallidum, external capsule, claustrum, extreme capsule, insular cortex, anterior commissure, uncinate fascicle, and the inferior fronto-occipital fascicle. The internal capsule with its anterior and posterior arms and genu, which, topographically, coincides with the foramen of Monro, remains an intermediate and divisive element.

Two subdivisions of the lateral central core have been proposed. One is from a coronal plane that passes through the lateral projection of the foramen of Monro, and the second is an axial plane through it. Thus, it can be divided into 4 sectors: anterosuperior, posterosuperior, posteroinferior, and anteroinferior. These were divided into zones I, II, III, and IV by Sanai et al.,[22]

Table 2. Summary of Proposed Subdivisions of Cerebral Central Core and Proposed Neurosurgical Approaches According to Our Experience for Each Sector

Region of CCC	Neurosurgical Approach to CCC
Lateral CCC	
Lateral anterior central core	Trans-Sylvian fissure
Lateral medium central core	Trans-Sylvian fissure
Lateral posterior central core	Trans-Sylvian fissure
Medial CCC	
Anterior caudate medial	Homolateral transcallosal
Anterior caudate lateral	Contralateral transcallosal
Anterior medial thalamus	Homolateral transcallosal
Anterior lateral thalamus	Contralateral transcallosal
Middle caudate	Contralateral transcallosal
Posterior medial thalamus	Trans-splenium
Posterior lateral thalamus	Intraparietal sulcus
Posterior caudate	Intraparietal sulcus
Thalamus third ventricle	Transchoroidal fissure

CCC, cerebral center core.

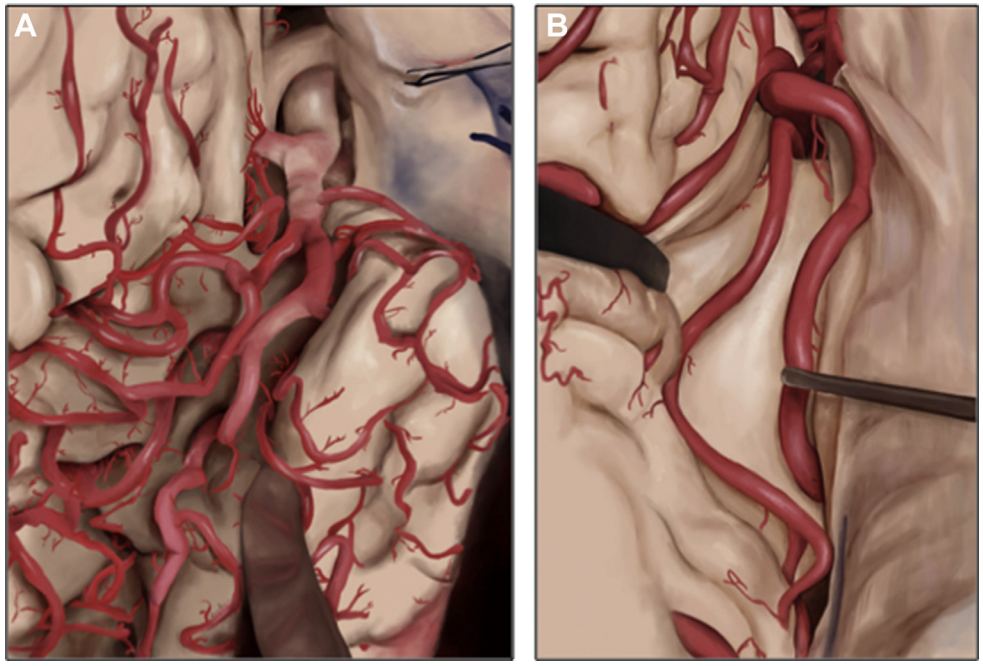

Figure 7. (**A**) Artistic representation of pretemporal approach with opening of the Sylvian fissure for access to the insular surface in its anterior, middle, and lateral sectors. Using this type of approach allows for access to surgically resect pathological features located in the cortex of the insula, claustrum, external and extreme capsules, unciform and fronto-occipital fasciculus. (**B**) Drawing of the transcallosal interhemispheric approach to reach the central core related to the lateral ventricle, third ventricle, or quadrigeminal cistern through trans-splenial access. Its variants are the homolateral, contralateral, trans-splenial, and transchoroidal fissure approaches.

respectively. The second subdivision that we have proposed is through 2 coronal lines that demarcate the projection on the insular cortex of the anterior and posterior edges of the lenticular nucleus. We have designated these planes as the anterior and posterior lenticular insular margin (Figure 5A, B). Therefore, we delimited the lateral CCC in the anterior, middle, and posterior segments. The middle segment appears to be the safest when addressing deep pathological features to the insular cortex, because in the anterior and posterior segments, the extreme, external and internal capsules do not present with a clear separation border between them.

We divided the medial aspect of the CCC in relation to the sectors of the lateral and third ventricles, with which it is related (Figure 6B and C). The head of the caudate lies in the anterior horn of the lateral ventricle, and we divided it into the medial and lateral sectors: the caudate anterior medial and lateral. The central portion,[9,17] or body of the lateral ventricle, is represented medially by the thalamus and laterally by the body of the caudate nucleus. For this portion, we have proposed the division into the anterior medial thalamus, corresponding to the dorsal surface of the thalamus near the choroidal fissure; and the anterior lateral thalamus in relation to the caudate nucleus, and lateral to the medullary thalamic stria. Finally, we described the middle caudate sector, which corresponds to the tail of the caudate nucleus.

The posterior surface of the thalamus is divided by the choroidal fissure in an intraventricular segment in the atrium, which we termed the posterior lateral thalamus, and a medial or cisternal extraventricular segment, in relation to the quadrigeminal cistern, termed the posterior medial thalamus. The last sector of the medial CCC is the thalamic surface in relation to the third ventricle (thalamus in the third ventricle), which extends from the choroidal fissure to the hypothalamic sulcus of the ventricular surface.

Neurosurgical Approaches to the CCC

As previously stated, isolated studies have reported on the CCC divisions. However, none of these studies were oriented to microsurgical corridors. After analyzing the anatomy of the central cerebral core, we have proposed the following approaches: ipsilateral transcallosal, contralateral transcallosal, transchoroidal fissure, trans-splenial, transparietal access entering through the intraparietal sulcus, and trans-sylvian approaches. The divisions of the CCC with each proposed approach are presented in Table 2.

As summarized in Table 2, the anatomic division of the CCC provide for surgical orientation, with a corresponding strategy determined by the approach for each case. The frontotemporal approaches (pterional, pretemporal, etc.) allow for access to the sylvian fissure and, after its dissection in its sphenoidal and lateral segments, the lateral surface of the central core will be exposed. As seen in the dissection shown in Figure 5 and

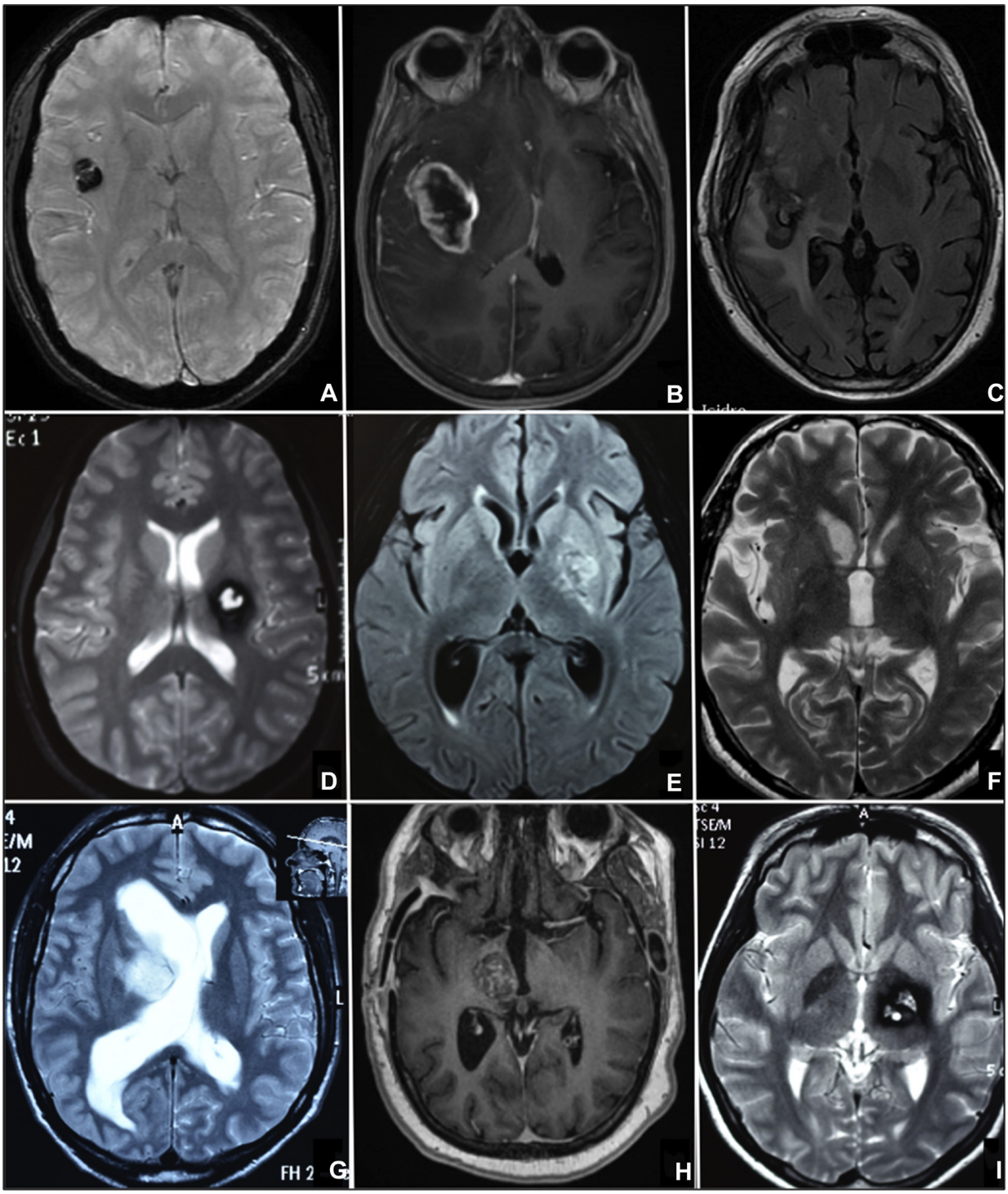

Figure 8. Magnetic resonance images of patients with cerebral central core pathological features. (**A**) Cavernoma at the level of the right insula and extreme capsule, with a halo of hemosiderin extending to the claustrum, is projected in the lateral point of the foramen of Monro. (**B**) Glioblastoma with extensive right insular component. (**C**) Right posterior insular anaplastic astrocytoma, located behind the posterior insular lenticular plane, and reaching deep to the external capsule. (**D**) Left lenticular cavernoma, with a hemosiderin halo extending to the posterior arm of the internal capsule. (**E**) Glioma of low grade at the left lentiform nucleus. (**F**) Subependymoma of the head of the right caudate nucleus, located medially. (**G**) Glioblastoma located at the level of the body of the right caudate nucleus. (**H**) Right thalamic cavernoma with pial expression at the atrial pulvinar level. (**I**) Left thalamic cavernoma with halo of hemosiderin in relation to internal capsule.

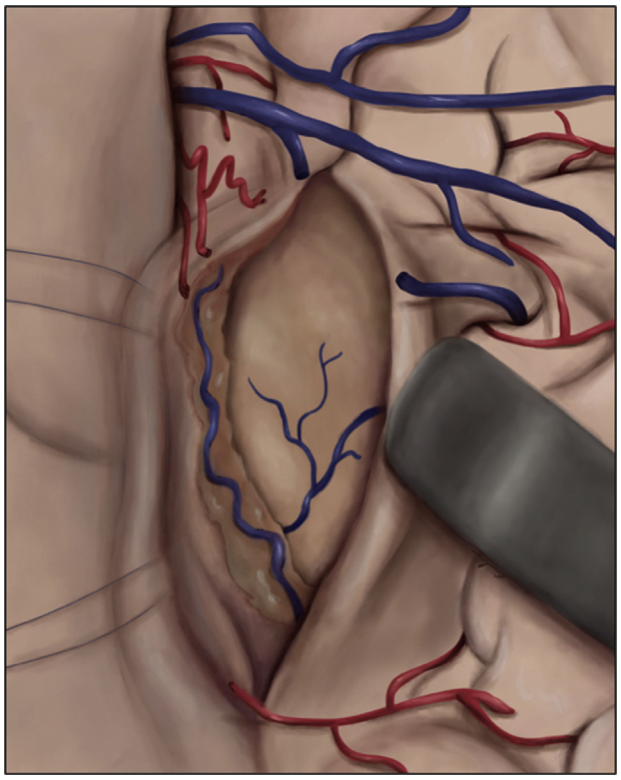

Figure 9. Artistic illustration of a transparietal sulcus approach through the right intraparietal sulcus for access to the ventricular atrium and, through it, to the ependymal surface of the pulvinar of the thalamus. Although it is a transcortical choice, this corridor avoids damaging the geniculocalcarine fibers and, in addition, the fibers of the cingulate fascicle will be respected medially. The intraparietal sulcus separates the interior parietal lobe from the superior and will generally run parallel to the median line at 2 or 3 cm from the medial border of the cerebral hemisphere. Once access has been created, it should be gently retracted. In some cases, endoscopic assistance can be used for intraventricular microsurgery on the thalamus or tail of the caudate nucleus.

plotted in the drawing shown in Figure 6A, the trajectory of the M2 branches of the middle cerebral artery should be preserved, using the space between them for dissection and access to the subcortical structures of the lateral CCC. The latter is especially important behind the posterior insular lenticular plane (distances presented in Table 1), because these arterial branches provide perforators that traverse the insular cortex, reaching the posterior arm of the internal capsule.

In Figure 7B and an original digital artistic representation, a left interhemispheric approach is shown. It crossed the corpus callosum on the ipsilateral or contralateral side,[30-35] allowing for access to the medial central core in relation to the lateral ventricle, third ventricle, or quadrigeminal cistern in the case of posterior transcallosal access through the splenium.

The access to the pulvinar of the thalamus in its intraventricular sector and the tail of the caudate nucleus include those used for pathological entities of the ventricular atrium. The intraparietal sulcus is located anteroposteriorly, separating the superior parietal lobe from the inferior lobe (supramarginal and angular gyrus), and generally runs parallel to the median line at 2 or 3 cm from the interhemispheric fissure. Once access has been achieved, it should be gently retracted and, in some cases, endoscopic assistance can be used for intraventricular microsurgical work on the thalamus or tail of the caudate nucleus.

We have used this approach for pulvinar cavernomas and subependymomas of the tail of the caudate nucleus, because access is direct to these components of the CCC, as shown in Figures 8H and 9.

DISCUSSION

The subdivision of the cerebral hemispheres into lobes was determined from the skull bones with which they are related.[36] However, in 1809, in its original description by Reil, the insula was recognized as a distinct lobe.[4,36] If the insula behaves as an external shield to the CCC[2] and the latter is located above the brainstem, one can easily understand that the approaches to this topographic sector will represent a great challenge. In addition, the CCC includes numerous eloquent cortical and subcortical structures. Therefore, the preoperative studies of each case must be carefully analyzed to understand the lesion's relationship to the location and, thus, enable selection of the most accurate and safe approach.

For those lesions with a lateral ependymal component in the lateral ventricle, the contralateral transcallosal access will provides a greater angle of vision[34,37] without the need for retraction of the cingulate gyrus and fascicle. Although some investigators have recommended transcortical access to the frontal horn or body of the lateral ventricle, we have preferred to use the natural corridor offered by the interhemispheric fissure and the pericallosal cistern. By avoiding the transcortical access, the likelihood of postoperative seizures will be reduced, as will the risk of injuring the fibers of the corpus callosum, which invariably extend below the corticotomy. The small sector of the CCC in relation to the dorsal surface of the third ventricle, represented by the medial surface of the thalamus, can be exposed to the surgeon's vision by a transcallosal or transcortical endoscopic corridor using access through the transchoroidal fissure. With the homolateral transcallosal approach, after entering the body of the lateral ventricle, the choroid plexus must be identified and moved medially to proceed with the opening of the choroidal fissure and below it to reach the thalamic surface of the third ventricle, which is limited by the hypothalamic groove. In the case of patients with hydrocephalus, another valid option is to perform endoscopic access via the trans-foramen of Monro to the third ventricle.

The trans-sulcal access through the intraparietal sulcus of the lateral surface of the hemisphere will direct one toward the ventricular atrium, without damaging important fascicles, such as the optic radiations, superior longitudinal fascicle, and occipital forceps of the corpus callosum. If difficulty is encountered in locating the intraparietal sulcus, ultrasound guidance can be used to determine the trajectory to the ventricular atrium.

We began with the stratification proposed by Ribas et al,[4] with the division of the central core laterally into 4 quadrants, with the

addition of delimitating the anterior and posterior borders of the lenticular nucleus, because it acts as a shield of gray substance that protects the internal capsule. This division into 4 quadrants from the insular projection of the foramen of Monro will allow one to orient oneself for the trans-sylvian approaches for pathological entities located in the CCC lateral to the internal capsule.

We have proposed a division of the medial central core for the neurosurgical approach to be used for access to this anatomical region. These include the ipsilateral and contralateral transcallosal interhemispheric approachs[34,38] to the transchoroidal fissure, trans-splenium, and transintraparietal sulcus.

The access to pathological entities in this area involves transcortical routes, cisternal dissection, or primary access to some sector of the lateral ventricles or third ventricle, until the CCC can be visualized. Therefore, correct positioning of the patient, the use of microsurgical and endoscopic techniques, and the use of neuronavigation or stereotaxic guidance with needle or laser will be important, in addition to the use of intraoperative cortical and subcortical stimulation.

CONCLUSIONS

We have provided a detailed description of the limits and cortical and subcortical anatomy of the CCC using brain sectioning, fiber dissections, and step-by-step analysis of cadaveric material injected with silicone and prepared with Klingler's technique. The useful measurements for the neurosurgeon were analyzed, including the projection of the foramen of Monro on the insular surface and from that, the anterior and posterior insular lenticular plane. With the advances in transcortical ultrasound techniques, localization of the foramen of Monro using transcortical insular ultrasonography might be feasible, which would allow us to use the measurements obtained from our study in patients with central lateral core tumors and decreasing the postoperative morbidity.

ACKNOWLEDGMENTS

We thank Evelyn Nieva for the original digital drawings created especially for this work.

REFERENCES

1. Koutsarnakis C, Liakos F, Liouta E, Themistoklis K, Sakas D, Stranjalis G. The cerebral isthmus: fiber tract anatomy, functional significance, and surgical considerations. *J Neurosurg*. 2016;12:450-462.
2. Ribas GC, de Oliveira E. A insula e o conceito de bloco cerebral central. *Arq Neuropsiquiatr*. 2007;65:92-100.
3. Brodal A. *Neurological Anatomy in Relation to Clinical Medicine*. 3rd ed. New York: Oxford University Press; 1981.
4. Ribas EC, Yağmurlu K, de Oliveira E, Ribas GC, Rhoton A Jr. Microsurgical anatomy of the central core of the brain. *J Neurosurg*. 2018;129:752-769.
5. Refojos M, Morley G, Trindade de Veglia HM. *Preparación anatómica de encéfalo bovino con fines didácticos*. Corrientes, Argentina: Universidad Nacional del Nordeste, Comunicaciones Científicas y Tecnológicas; 2003.
6. Ludwig E, Klingler J. *Atlas Cerebri Humani*. Boston: Little, Brown & Co.; 1956.
7. Rubino P, Baldoncini M, Conesa HA. Disección de Sustancia Blanca Cerebral. Importancia para el Entrenamiento Neuroquirúrgico — pág. *Revista Argentina de Anatomía Online*. 2012;3:97-136.
8. Nieuwenhuys R, Voogd J, van Huijzen C. *The Human Central Nervous System*. 4th ed. New York: Springer; 2008.
9. Federative Committee on Anatomical Terminology. *Terminología Anatómica: International Anatomical Terminology*. Stuttgart: Thieme; 1998.
10. Ribas GC, de Oliveira E. [The insula and the central core concept.]. *Arq Neuropsiquiatr*. 2007;65:92-100.
11. Rhoton AL. The cerebrum. *Neurosurgery*. 2002;51:375-410.
12. Testut L, Latarjet A, Latarjet M. *Tratado de anatomía humana*. Barcelona: Salvat; 1988.
13. Ono M, Kubik S, Abernathey CD, eds. *Atlas of the Cerebral Sulci*. Stuttgart, Germany: G. Thieme Verlag; 2017.
14. Ribas G. The cerebral sulci and gyri. *Neurosurg Focus*. 2010;28:E2.
15. Yaşargil MG, Krisht AF, Türe U, Al-Mefty O, Yaşargil DCH. Microsurgery of insular gliomas: part I: surgical anatomy of the Sylvian cistern. *Contemp Neurosurg*. 2002;24:1-8.
16. Duvernoy H. *The Human Brain*. Vienna: Springer; 1999.
17. Terminología Anatómica Internacional. *Comité Federal sobre Terminología Anatómica*. Madrid, Spain: Editorial Medica Panamericana; 2001.
18. Nieuenhuys R, Voogd J, Van Huijzen C. *The Human Central Nervous System: A Synopsis and Atlas*. 4th ed. Heidelberg: Steinkopff-Verlag; 2008.
19. Türe U, Yaşargil DC, Al-Mefty O, Yaşargil MG. Topographic anatomy of the insular region. *J Neurosurg*. 1999;90:720-733.
20. Türe U, Yaşargil MG, Friedman AH, Al-Mefty O. Fiber dissection technique: lateral aspect of the brain. *Neurosurgery*. 2000;47:417-426 [discussion: 426-427].
21. Wen HT, Rhoton AL Jr, de Oliveira E. Transchoroidal approach to the third ventricle: an anatomic study of the choroidal fissure and its clinical application. *Neurosurgery*. 1998;42:1205-1219.
22. Sanai N, Polley M-Y, Berger MS. Insular glioma resection: assessment of patient morbidity, survival, and tumor progression. *J Neurosurg*. 2010;112:1-9.
23. Potts MB, Chang EF, Young WL, Lawton MT. Transsylvian- transinsular approaches to the insula and basal ganglia: operative techniques and results with vascular lesions. *Neurosurgery*. 2012;70:824-834.
24. Yaşargil MG. *Microneurosurgery, Vol IVB, Microneurosurgery of CNS Tumors*. Stuttgart: Georg Thieme Verlag; 1996:54-57.
25. Naidich TP, Kang E, Fatterpekar GM, et al. The insula: anatomic study and MR imaging display at 1.5 T. *AJNR Am J Neuroradiol*. 2004;25:222-232.
26. Rangel-Castilla L, Spetzler RF. The 6 thalamic regions: surgical approaches to thalamic cavernous malformations, operative results, and clinical outcomes. *J Neurosurg*. 2015;123:676-685.
27. Tanriover N, Rhoton AL Jr, Kawashima M, Ulm AJ, Yasuda A. Microsurgical anatomy of the insula and the sylvian fissure. *J Neurosurg*. 2004;100:891-922.
28. Türe U, Yaşargil MG, Al-Mefty O, Yaşargil DC. Arteries of the insula. *J Neurosurg*. 2000;92:676-687.
29. Stein BM. Transcallosal approach to third ventricular tumors. In: Schmidek HH, Sweet WH, eds. *Current Techniques in Operative Neurosurgery*. New York: Grune & Stratton; 1977:247-255.
30. Ehni G. Comments on Shucart WA, Stein BM: transcallosal approach to the anterior ventricular system. *Neurosurgery*. 1978;3:343.
31. Kasowski M, Piepmeier JM. Transcallosal approach for tumors of the lateral and third ventricles. *Neurosurg Focus*. 2001;10:E3.

32. Campero A, Ajler P, Emmerich J. *Abordajes neuroquirúrgicos al cerebro y la base del cráneo. Cap. 1 Abordaje interhemisferico transcoroideo*. 2013.

33. Yaşargil G, Türe U, Yaşargil D. Surgical anatomy of supratentorial midline lesions. *Neurosurg Focus*. 2005;18:E1.

34. Baldoncini M, González López P. Abordaje Interhemisférico Contralateral Transfalcino, Subfalcino y Transcalloso. *Rev Argentina Neurocir*. 2018;32:1-15.

35. García Navarro V, Castillo Velázquez G. "Estrategias y abordajes en neurocirugía craneal" Chapter 14 Apertura del valle silviano, Cap. 23 Abordajes Interhemisfericos. Distrito Federal, Mexico: Editorial AMOLCA; 2015.

36. Ribas GC. Neuroanatomical basis of behavior: history and recent contributions. *Rev Bras Psiquiatr*. 2007;29:63-71.

37. Lawton MT, Golfinos JG, Spetzler RF. The contralateral transcallosal approach experience with 32 patients. *Neurosurgery*. 1996;39:729-735.

38. Nehls DG, Marano SR, Spetzler RF. Transcallosal approach to the contralateral ventricle. Barrow Neurological Institute, Phoenix. *J Neurosurg*. 1985; 62:304-306.

Conflict of interest statement: The authors declare that the article content was composed in the absence of any commercial or financial relationships that could be construed as a potential conflict of interest.

Received 23 January 2019; accepted 16 April 2019

Citation: World Neurosurg. (2019) 129:e23-e34.
https://doi.org/10.1016/j.wneu.2019.04.139

Journal homepage: ***www.journals.elsevier.com/world-neurosurgery***

Available online: ***www.sciencedirect.com***

1878-8750/$ - see front matter © 2019 Elsevier Inc. All rights reserved.