Journal of Robotic Surgery (2019) 13:539–543
https://doi.org/10.1007/s11701-019-00949-8

REVIEW ARTICLE

Robotic harvesting of the omental flap: a case report and mini-review of the use of robots in reconstructive surgery

Ömer Özkan[1] · Özlenen Özkan[1] · Anı Çinpolat[3] · Cumhur Arıcı[2] · Gamze Bektaş[3] · Mehmet Can Ubur[1]

Received: 22 December 2018 / Accepted: 20 March 2019 / Published online: 25 March 2019
© Springer-Verlag London Ltd., part of Springer Nature 2019

Abstract

This study describes the robotic harvesting of a free omental flap. The patient was a 58-year-old man who had undergone several previous operations due to osteomyelitis caused by trauma. There was a non-healing wound and purulent discharge in the distal pretibial region. The flap was harvested based on the right gastroepiploic artery using robotic facilities only. The flap was then transferred to the debrided defect in the pretibial region. Anastomoses were performed between the posterior tibial vessels and the pedicle of the flap. A split thickness skin graft was used to cover the omental flap. The operation lasted 2.5 h in total, including flap harvesting, microvascular anastomoses, inset and skin grafting. The postoperative period was uneventful and the patient was discharged on the 12th day postoperatively. The reliability of the technique is discussed in this report, together with a brief review of the use of robot surgery in reconstructive surgery in the literature.

Keywords Free flap · Omental flap · Reconstructive surgery · Robotic surgery

Introduction

As with all other surgical specialties, technological developments find a particular place in the treatment of problems in plastic and reconstructive surgery. With the advent of microsurgical techniques, there has been considerable work on refinements of detail. Following the description of several innovative flap options, 100 of papers have reported techniques intended to reduce morbidity rates, shorten operating time, increase surgeon comfort during surgery, facilitate rehabilitation in the postoperative period and reduce length of hospitalization during the harvesting and transfer of these tissues.

The omental flap is large peritoneal fold of sufficient size and bulk to fill large three-dimensional dead spaces, and with large reliable feeding arteries and draining veins, and rich vascular and lymphatic networks. It is a versatile reconstructive tool with various applications in the field of plastic and reconstructive surgery. The main disadvantage of the flap is the need for laparotomy, which may be associated with significant morbidities for flap harvesting. Laparoscopic harvesting was recently described to eliminate this disadvantage [1–3]. Most of the disadvantages of laparotomy can be eliminated or at least minimized using this technique, while preserving all the valuable advantages of the flap.

One recent technological advance, robotic surgery, is one of the latest developments used in plastic surgery, especially in flap harvesting, and provides easier surgery using the da Vinci system's precision controls and magnified, 3-D high definition view of the operating field [4]. In this report, we describe the harvesting of a free omental flap with the help of a robot. The recent use of robots in reconstructive surgery is also discussed.

✉ Ömer Özkan
omozkan@hotmail.com

Özlenen Özkan
ozlenend@yahoo.com

Anı Çinpolat
anicinpolat@hotmail.com

Cumhur Arıcı
cumarici@yahoo.com

Gamze Bektaş
gamze-bkts@hotmail.com

Mehmet Can Ubur
mcubur@hotmail.com

1 Department of Plastic, Reconstructive and Aesthetic Surgery, Akdeniz University Hospital, Antalya, Turkey

2 Department of General Surgery, Akdeniz University Hospital, Antalya, Turkey

3 Reconstructive and Aesthetic Surgery, Private Clinic, Plastic, Istanbul, Turkey

Methods

A 58-year-old male patient who had undergone several previous operations due to osteomyelitis caused by a fall from a height 2.5 years previously was admitted to our clinic due to a non-healing wound in the distal pretibial region. The defect was 10 × 12 cm in size. A purulent discharge issued from the tibial bone (Fig. 1). The patient had a previous history of cardiac by-pass surgery. A da Vinci XI model robot was used to harvest an omental flap. A Veress needle was used for insufflation of CO_2 in a standard laparoscopic manner. The camera port was inserted through an incision over the superior border of the umbilicus. Two 8-mm ports were docked on either side of the camera port, approximately 10 cm laterally (to the lateral border of the rectus abdominis muscle) and 2 cm inferiorly. A grasper was placed in the right port, and a monopolar cautery with added scissors was placed in the left port. An additional 5-mm port was inserted in the right anterior axillary line 5 cm below the level of the right port (Fig. 2). This was intended as a manually held port for additional manipulations by an assistant surgeon. Following the docking and placement of the instruments, the main surgeon sat at the console and performed the dissection.

Fig. 1 Preoperative view of the defect in the pretibial region

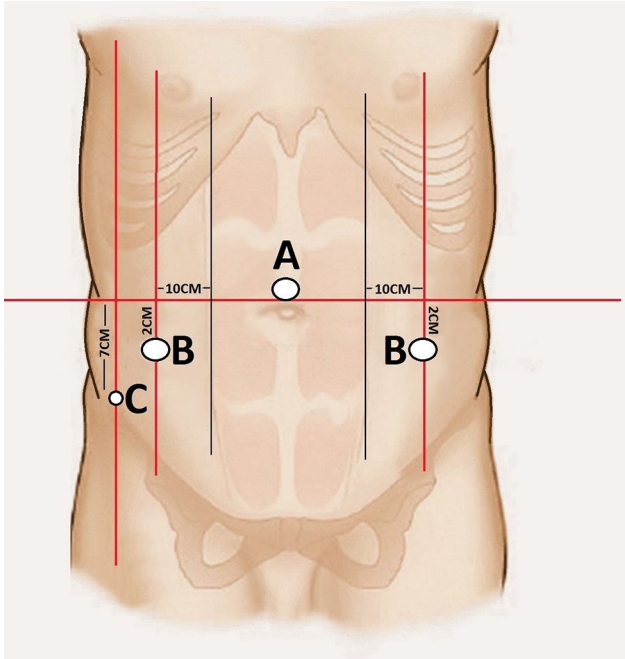

Fig. 2 Schematic representation of positions of the cannulas. **a** Camera port, **b** lateral 8 mm ports, **c** additional 5 mm port

Following abdominal exploration, all minor intraperitoneal adhesions were released. The omentum was visualized and detached from the transverse colon and greater curvature, and all gastric branches were coagulated and cut at a safe distance from the main pedicle. The left gastroepiploic vessels were ligated and cut. Finally, the omentum was mobilized on the right gastroepiploic vessels (Fig. 3). After dissecting and skeletonizing the pedicle, approximately 2 cm

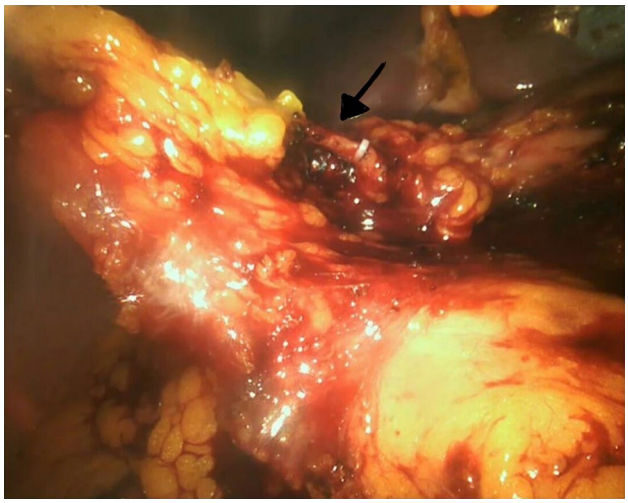

Fig. 3 Intraoperative (intra-abdominal) view of the flap based on the right gastroepiploic vessels. (Arrow shows the ligated right gastroepiploic artery)

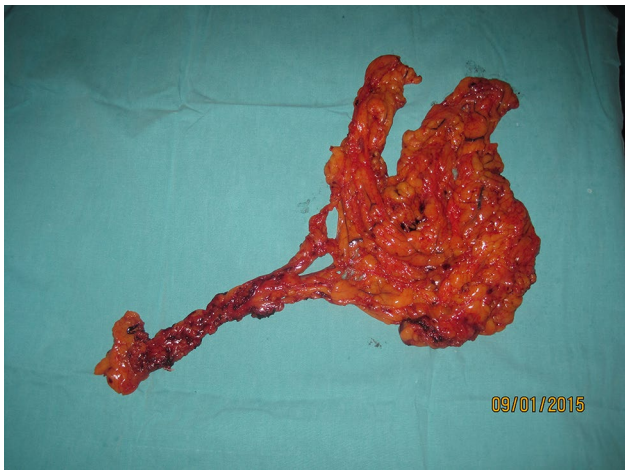

Fig. 4 The robotic-harvested omental flap

Fig. 5 View at postoperative month 12 of the transferred flap in the pretibial region

in length, the pedicle was ligated using laparoscopic hemoclips and divided. The harvested flap was removed from the abdomen through a 5-cm incision in the inferior part of the previous cardiac by-pass surgery scar (Fig. 4).

All incisions were closed primarily after inspecting the intra-abdominal space for any bleeding or uneventful injury and removing CO_2 gas.

The omentum was prepared to adapt the defect, and debulking was performed with three-layer closure on the table. The flap was brought to the defect, and anastomoses were performed between the posterior tibial vessels and the pedicle of the flap. Arterial anastomosis was performed end-to-side, and venous anastomosis in an end-to-end manner. The flap was folded over itself as prepared on the table, and the defect was sutured. A split thickness skin graft was used to cover the omental flap. The operation lasted 2.5 h (1 h for flap harvesting and 1.5 h for anastomosis, inset and skin grafting).

Results

The postoperative period was uneventful. The flap was monitored with conventional clinical observation (color check and bleeding) and using Doppler ultrasonography. The patient started to eat on the 1st day and was discharged on the 12th day postoperatively (Fig. 5).

Discussion

Robotic surgery enjoys wide clinical use in urology, gynecology, general surgery and cardiothoracic surgery [5–7]. It has been used in plastic surgery since 2010 [4]. Selber first used the system in oropharyngeal tumor resection and reconstruction of the remaining defect [8]. He resected the tumors without performing mandibulotomy, using a transoral robotic approach or lateral pharyngotomy. Robotic-assisted reconstruction was performed using free or regional flaps, and anastomoses by means of the robotic system. Selber reported that the system allowed access and precision within the oropharynx with minimal morbidity, as well as permitting traditional reconstructive options for defects formed after resection.

Selber et al. [9] also described the harvest of the latissimus dorsi flap using robotic systems. They harvested seven flaps, two of which were used as a free flap for scalp reconstructions and the remaining five as pedicled flaps. The technique required a short axillary incision. It also afforded esthetic advantages over the traditional open technique. The main disadvantage of robotic harvesting of the latissimus dorsi flap is that it does not provide a large view compared with the intraperitoneal space. The field of view increases as dissection proceeds in the subcutaneous space.

Pederson et al. [10] (Selber's team once again) described the robotic intraperitoneal harvesting of the rectus abdominis muscle. Using three contralateral ports and a intraperitoneal approach, they harvested the rectus abdominis flap and transferred it as a free or pedicled flap to cover extremity soft tissue defects or to reconstruct abdominopelvic deformities. The robotic-assisted technique provided an intact anterior rectus sheath and eliminated incisional hernia risk and scar formation.

Another area of use of the robotic system is brachial plexus injuries [11, 12]. Naito et al. [11] performed a robotic-assisted Oberlin procedure to provide elbow flexion. Myamoto et al. [12] performed nerve transfer to the deltoid muscle using the nerve to the long head of the triceps with a da Vinci robot in six cases. In that study, due to

the limited field of view they modified the strategy to open surgery in two cases. The reliability of robotic surgery in brachial plexus injury was studied in a cadaveric experiment [13]. The authors suggested that the technique was useful and could be extensively used in brachial plexus surgeries, and particularly in thoracic outlet syndrome. However, they also emphasized the need to develop new instruments for the technique to be applied more broadly.

Robotic-assisted vessel anastomoses have been studied in a pig model, and the reliability and safety of that technique have been proved [14]. Advantages include tremor elimination, scalable movements, fully articulating instruments and a dynamic three-dimensional visualization system. That study also emphasized the need to develop new, modified instruments.

The use of the robotic-assisted omental flap has been reported in the prevention of recurrent fibrosis after ureterolysis [15, 16]. In that study, the omentum was rotated as a partial wrap flap. No pedicle dissection was performed. The present study describes the first robotic-harvested free omental flap in the literature. The main advantages of the omental flap are sufficient size and bulk to fill large three-dimensional dead spaces, a long pedicle, and rich vascular and lymphatic networks. Ever since its introduction, it has been the subject of broad interest from reconstructive surgeons. However, the need for open laparotomy is a significant drawback of the flap. Since this drawback associated with harvesting can result in severe complications, the omentum has achieved limited popularity and has been unable to extend its use in the reconstructive field. Laparoscopic harvesting has recently been described to overcome this significant drawback [1–3]. Using this less invasive technique compared to open laparotomy, the morbidity risk for flap harvesting is significantly reduced. Additionally, the abdominal incision required for flap harvesting is relatively minimal, and the operation is well-tolerated by the patient. Nevertheless, despite this novel technique, the omental flap with its many important properties, such as tissue bulk and rich vascularity with a long vascular pedicle, has not become popular. Researchers have suggested that harvesting is much easier when performed using the da Vinci's precision controls and magnification, even compared to the laparoscopic technique, and this is very probably due to the increasing experience gained. It has also been suggested that the robotics allow the operation to proceed more smoothly and quickly, while the surgery itself can be performed more precisely with minimal risk of mis-steps compared to standard laparoscopy [12].

Increased experience with robotic surgery and a more economical technological background should increase the popularity of the omental flap still further. Increasingly lower levels of morbidity with less conspicuous scarring (involving the same scar as the laparoscopic technique) will also contribute to an increase in popularity in the near future. As described above, clearer and three-dimensional visualization, tremor elimination and the provision of a wide range of articulation are the main advantages of the robotic system over even the laparoscopic technique. This potentially infinite angulation of the surgical instruments, including scissors and clamps, provides superior control of the surgical field compared with their laparoscopic equivalents with their limited degree of motion. Robotic instrument articulation is very close to that of the human wrist and hand, and even provides better manipulation, eliminating human hand tremor. This is especially important in magnified fields and permits stable and accurate dissection and further surgical steps. In robotic surgery, the comfort of the surgeon is increased, and ideal alignment of eyes, hands and operative field, together with a cushioned console, give the illusion of operating directly, and even more easily and accessibly [16]. As in all other technological applications, with wider use and background advances this will very probably become more economical and gain greater acceptance in many surgical fields as a result of this remote control facility. This feature will be particularly helpful for educational purposes, in that it will permit wide attendance of scientific activities such as congresses, workshops, and courses from any part of the world.

With the case presented here, we believe that with further experiences with robotic reconstructive surgery, the omental flap, one of the milestone flaps, will come to acquire its own prestige, eliminating the major disadvantages while preserving all the advantages. Using robotic techniques, pedicle dissection is as easy as the open technique. Microvascular transfer of the flap is reliable, and the flap can be used more radically and represents a good alternative for recent popular flap options.

The operative time in this case, a total of 2.5 h including all the steps involved, is quite close to that of any conventional free flap procedure, even though this was the team's first experience of robotic free flap harvesting.

Since the technology is relatively new, the system is still expensive. It should become more economical as its area of use expands and as more alternative systems appear. This will in turn result in the development of cheaper and improved equipment and instruments. Another important point is the need to use CO_2 gas for insufflation, as in the laparoscopic technique. Massive subcutaneous emphysema, pneumothorax, pneumomediastinum and gas emboli are potential major complications of robotic surgery [17]. Most plastic surgery operations take place in the subcutaneous space, and visualization is not as clear as in the intraperitoneal, thoracic or oropharyngeal spaces. Again, this problem can be overcome, or at least minimized, with the development of modified instruments and improved techniques.

Conclusions

In conclusion, the robotic surgery technique is particularly suited to an intra-abdominal approach, such as harvesting omental and rectus abdominis flaps or for intra-abdominal microsurgical anastomoses or oropharyngeal surgeries, including resection and reconstruction and brachial plexus repair. Robotic techniques are likely to enjoy increasing popularity in reconstructive surgery in the future.

Acknowledgments This study was supported by the Akdeniz University Scientific Research Projects Unit. We thank them for their support.

Compliance with ethical standards

Conflict of interest O. Ozkan has no conflict of interest. O. Ozkan has no conflicts of interest. A. Cinpolat has no conflicts of interest. C. Arici has no conflicts of interest. G. Bektas has no conflicts of interest. MC. Ubur has no conflicts of interest.

References

1. Saltz R, Stowers R, Smith M, Gadacz TR (1993) Laparoscopically harvested omental free flap to cover a large soft tissue defect. Ann Surg 217:542–546. https://doi.org/10.1097/00000658-199305010-00015
2. Saltz R (1995) Endoscopic harvest of the omental and jejunal free flaps. Clin Plast Surg. 22:747–754
3. Acarturk TO, Swartz WM, Luketich J, QuinlinRF Edington H (2004) Laparoscopically harvested omental flap for chest wall and intrathoracic reconstruction. Ann Plast Surg 53:210–216. https://doi.org/10.1097/01.sap.0000116285.98328.f7
4. Saleh DB, Syed M, Kulendren D, Ramakrishnan V, Liverneaux PA (2015) Plastic and reconstructive robotic microsurgery–a review of current practices. Ann Chir Plast Esthet 60:305–312. https://doi.org/10.1016/j.anplas.2015.03.005
5. Giedelman CA, Abdul-Muhsin H, Schatloff O, Palmer K, Lee L, Sanchez-Salas R et al (2013) The impact of robotic surgery in urology. Actas Urol Esp 37:652–657. https://doi.org/10.1016/j.acuro.2012.11.015
6. Bush B, Nifong LW, Chitwood WR Jr (2013) Robotics in cardiac surgery: past, present, and future. Rambam Maimonides Med J 25(4):e0017. https://doi.org/10.5041/RMMJ.10117
7. Buchs NC, Pugin F, Ris F, Volonte F, Morel P, Roche B (2013) Early experience with robotic rectopexy. Int J Med Robot 9:e61–e65. https://doi.org/10.1002/rcs.1498
8. Selber JC (2010) Transoral robotic reconstruction of oropharyngeal defects: A case series. Plast Reconstr Surg 126:1978–1987. https://doi.org/10.1097/PRS.0b013e3181f448e3
9. Selber JC, Baumann DP, Holsinger FC (2012) Robotic latissimus dorsi muscle harvest: a case series. Plast Reconstr Surg 129:1305–1312. https://doi.org/10.1097/PRS.0b013e31824ecc0b
10. Pedersen J, Song DH, Selber JC (2014) Robotic intraperitoneal harvest of the rectus abdominis muscle. Plast Reconstr Surg 134:1057–1063. https://doi.org/10.1097/PRS.0000000000000586
11. Naito K, Facca S, Lequint T, Livemeaux PA (2012) The Oberlin procedure for restoration of elbow fl exion with the da Vinci Robot: four cases. Plast Reconstr Surg 129:707–711. https://doi.org/10.1097/PRS.0b013e318241287f
12. Miyamoto H, Leechavengvongs S, Atik T, Facca S, Liverneaux P (2014) Nerve transfer to the deltoid muscle using the nerve to the long head of the triceps with the da Vinci robot: six cases. J Reconstr Microsurg 30:375–380. https://doi.org/10.1055/s-0033-1361927
13. Tetik C, Uzun M (2014) Novel axillary approach for brachial plexus in robotic surgery: A Cadaveric Experiment. Minim Invasive Surg 2014:927456. https://doi.org/10.1155/2014/927456
14. Katz RD, Rosson GD, Taylor JA, Singh NK (2005) Robotics in microsurgery: use of a surgical robot to perform a free flap in a pig. Microsurgery 25:566–569. https://doi.org/10.1002/micr.20160
15. Mufarrij PW, Stifelman MD (2006) Robotic ureterolysis, retroperitoneal biopsy, and omental wrap for the treatment of ureteral obstruction due to idiopathic retroperitoneal fibrosis. Rev Urol 8:226–230
16. Mufarrij PW, Lipkin ME, Stifelman MD (2008) Robot-assisted ureterolysis, retroperitoneal biopsy, and omental wrap: Pilot series for the treatment of idiopathic retroperitoneal fibrosis. J Endourol 22:1669–1675. https://doi.org/10.1089/end.2008.0034
17. Celik H, Cremins A, Jones KA, Harmanli O (2013) Massive subcutaneous emphysema in robotic sacrocolpopexy. JSLS 17:245–248. https://doi.org/10.4293/108680813X13654754535151

Publisher's Note Springer Nature remains neutral with regard to jurisdictional claims in published maps and institutional affiliations.