Interdisciplinary Neurosurgery 15 (2019) 98–100

Contents lists available at ScienceDirect

Interdisciplinary Neurosurgery

journal homepage: www.elsevier.com/locate/inat

Technical Notes & Surgical Techniques

Using the cortical bone trajectory screw technique with vertebral column resection to treat an osteoporotic compression fracture in progressive thoracolumbar hyperkyphosis: A case report

Chia-Hung Chao (MD)[a,*,1], Cheng-Yang Hsieh (MD, PhD)[b], Yu-Feng Su (MD)[c], Aij-Lie Kwan (MD, PhD)[c,d]

[a] Department of Neurosurgery, Tainan Sin-Lau Hospital, Tainan, Taiwan
[b] Department of Neurology, Tainan Sin-Lau Hospital, Tainan, Taiwan
[c] Department of Neurosurgery, Department of Surgery, Kaohsiung Medical University Hospital, Kaohsiung Medical University, Kaohsiung, Taiwan
[d] Department of Surgery, Faculty of Medicine, College of Medicine, Kaohsiung Medical University, Kaohsiung, Taiwan

ARTICLE INFO

Keywords:
Cortical bone trajectory screw
Osteoporotic compression fracture
Thoracolumbar hyperkyphosis

ABSTRACT

Progressive thoracolumbar hyperkyphosis (aka hunchbacked) with a sagittal imbalance in an osteoporotic compression fracture might warrant surgical correction when conservative treatment fails. A 70-year-old woman presented with an L1 osteoporotic compression fracture after an L1 vertebroplasty and a short-segment (T12-L2) pedicle screw fixation. Because of the osteoporosis, the pedicle screws had loosened and a new L4 compression fracture occurred after the surgery. The author used the cortical bone trajectory screw technique for a long-segment posterior fixation after an anterior vertebral column resection. The outcome was good at the one-year follow-up. This technique provided a thoracolumbar Cobb angle correction of 20° and a sagittal vertical axis correction from 8.3 cm to 2.5 cm. This was the first reported case using the long-segment cortical bone trajectory screw technique to treat an osteoporotic compression fracture in progressive thoracolumbar hyperkyphosis.

1. Introduction

Thoracolumbar fractures are common in patients with osteoporosis. Without proper treatment, they might cause progressive hyperkyphosis with a sagittal imbalance and might warrant surgical correction when conservative treatment fails. The cortical bone trajectory screw (CBT) technique is beneficial for osteoporotic spines and provides better screw anchoring force than do other methods. Using this technique to treat thoracolumbar hyperkyphosis in an osteoporotic spine has never been reported. We report one case with good clinical results after one year.

2. Case report

A 70-year-old woman presented with an osteoporotic L1 compression fracture about 18 months ago. At that time, she presented with severe back pain with bilateral lower limb weakness. The MRI exam revealed the bone fragments present within the spinal canal. After conservative treatment failed, she had undergone an L1 laminectomy, an L1 vertebroplasty, and T12, L1, and L2 transpedical screw fixation. However, she developed progressive back pain and kyphosis. About 4 months after her first surgery, and with no significant trauma history, she developed one new L4 compression fracture. The L2 screws had

* Corresponding author.
E-mail address: rickyohmygod@gmail.com (C.-H. Chao).
[1] No.220, Sec. 2, Dongmen Rd., East Dist., Tainan City 701, Taiwan (R.O.C.).

https://doi.org/10.1016/j.inat.2018.10.008
Received 23 August 2018; Received in revised form 9 October 2018; Accepted 14 October 2018
2214-7519/ © 2018 The Authors. Published by Elsevier B.V. This is an open access article under the CC BY-NC-ND license (http://creativecommons.org/licenses/BY-NC-ND/4.0/).

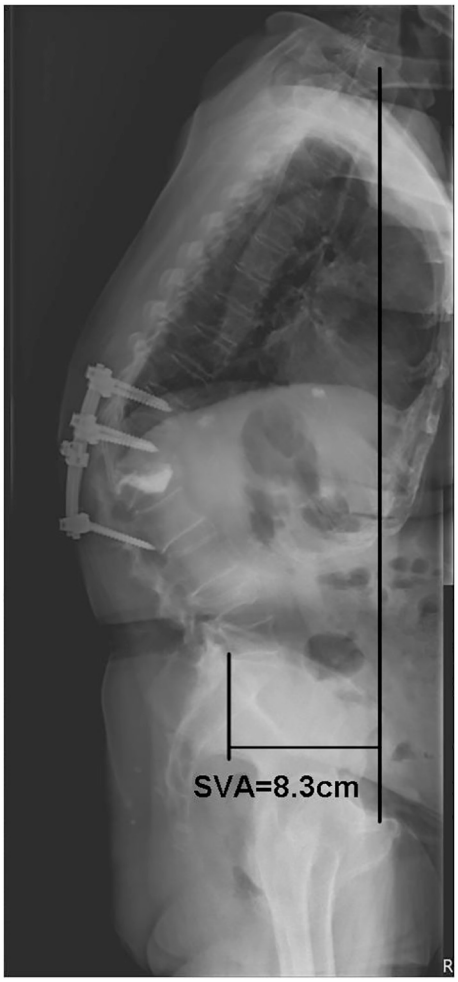

Fig. 1. A preoperative X-ray (standing lateral view) shows sagittal imbalance: Sagittal Vertical Axis (SVA) = 8.3 cm; T12-L2 kyphotic angle = 52.6°.

gradually loosened during the previous 11 months. The T-score of her bone mineral density (BMD) test was −3.3, and the treatment for her osteoporosis was the selective estrogen receptor modulators (SERMs) of raloxifene [60 mg/day]. The L2-screw pull-outs were detected about 18 months after her first surgery. She then came to our clinic because of bilateral sciatica and intractable stabbing back pain, especially while lying flat. She could not stand and walk erectly without a walker. We started to give her subcutaneous teriparatide [20 μg/day]. A whole-spine lateral X-ray showed thoracolumbar hyperkyphosis with a sagittal imbalance. The T12-L2 kyphotic angle was 52.6°, and the thoracic spine kyphotic angle was 35.6°. The spinal vertical axis (SVA) was about 8.3 cm. The pelvic incidence (PI) was 29.7°, and the lumbar lordosis (LL) was 1.6° (Fig. 1). A magnetic resonance image showed L3–4 and L4–5 spinal stenosis. After six months of subcutaneous teriparatide therapy, the T-score of her BMD improved to −2.6. We did an L1 partial corpectomy and reconstruction (graft) using a lateral approach and a silica tube filled with poly(methyl methacrylate) (PMMA) (Fig. 2). Then, posteriorly, we removed all screws and arranged for a T11, T12, and L2 PMMA vertebroplasty. We also did an L3–4 and L4–5 Smith-Petersen osteotomy and long-segment fixation (T9-S1 except L1 and L4) using the cortical bone trajectory screw technique under fluoroscopic guidance.

The patient's recovery was uneventful. Her clinical symptoms were significantly attenuated. One year postoperatively, the T12-L2 kyphotic angle was 32°, with a thoracic kyphotic angle of 21.6°. Lumbar lordosis was about 22°, and SVA was 2.5 cm (Fig. 3). She was doing well and could walk without the walker.

3. Discussion

To treat the patient's thoracolumbar kyphosis, we did a L1 partial corpectomy and a reconstruction to lengthen the anterior column. To increase her lumbar lordosis, we also did L34 and L45 Smith-Petersen osteotomies to shorten the posterior column. Because the patient had osteoporosis and a BMD T-score of −3.3 (poor bone quality), and for its cost-effectiveness, we chose a silica tube.

Recently, the cortical bone trajectory screw (CBT) technique has become more popular in short-segment lumbar fusion surgery, in adjacent level disease, and in spinal revision surgery [1] because it is minimally invasive. The benefits of using this technique in osteoporotic spine surgery have been confirmed in *in vivo* and *in vitro* studies [2,3]. The safety of the CBT technique was also confirmed in the lumbar, low thoracic, and middle thoracic spine because it affords a smaller chance to injure internal organs and great vessels [4,5].

The prevalence of sacral fracture after long segment fixation was reported to be about 3.1% [6]. Further instrumenting to the pelvis should be considered in this case given the osteoporotic bone quality to prevent it. We did not extend the fusion segment to the pelvis due to the improvement of her BMD before surgery. The daily subcutaneous teriparatide therapy was also continued for one and half year. There has been no clinical or image evidence of sacral fracture till now and the long-term result should be followed.

4. Conclusion

We conclude that CBT provided good screw anchoring force and that the whole construct supported the spine well after the deformation had been corrected. This is the first published case to use CBT to correct an osteoporotic compression fracture in progressive thoracolumbar hyperkyphosis. However, additional biomechanical studies and more clinical case series might be required to support this point.

Fig. 2. A CT scan (coronal and sagittal view) revealed L1 partial corpectomy and reconstruction with a silica tube filled with poly(methyl methacrylate) (PMMA).

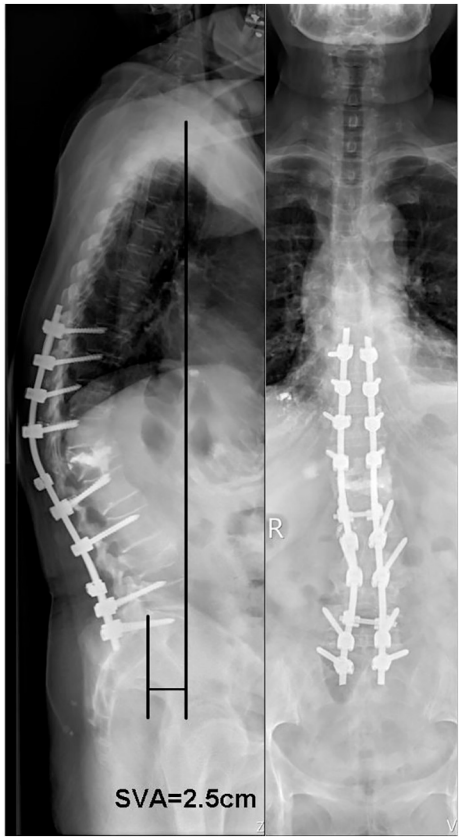

Fig. 3. A one-year postoperative X-ray (standing AP and lateral view) shows an SVA = 2.5 cm, and a T12 to L2 kyphotic angle = 32°.

Conflict of interest

The authors declare no conflict of interest.

References

[1] A. Rodriguez, M.T. Neal, A. Liu, A. Somasundaram, W. Hsu, C.L. Branch Jr.et al., Novel placement of cortical bone trajectory screws in previously instrumented pedicles for adjacent-segment lumbar disease using CT image-guided navigation, Neurosurg. Focus. 36 (3) (2014) E9.

[2] K. Matsukawa, Y. Yato, T. Kato, H. Imabayashi, T. Asazuma, K. Nemoto, *In vivo* analysis of insertional torque during pedicle screwing using cortical bone trajectory technique, Spine (Phila Pa 1976) 39 (2014) E240–E245.

[3] B.G. Santoni, R.A. Hynes, K.C. McGilvray, G. Rodriguez-Canessa, A.S. Lyons, M.A. Henson, et al., Cortical bone trajectory for lumbar pedicle screws, Spine J. 9 (2009) 366–373.

[4] K. Matsukawa, Y. Yato, R.A. Hynes, H. Imabayashi, N. Hosogane, T. Asazuma, et al., Cortical bone trajectory for thoracic pedicle screws: a technical note, Clin. Spine Surg. 30 (5) (2017) E497–E504.

[5] S.R. Sheng, J.X. Chen, W. Chen, E.X. Xue, X.Y. Wang, Q.A. Zhu, Cortical bone trajectory screws for the middle-upper thorax: an anatomico-radiological study, Medicine (Baltimore) 95 (35) (2016) E4676.

[6] E. Klineberg, T. McHenry, C. Bellabarba, T. Wagner, J. Chapman, Sacral insufficiency fractures caudal to instrumented posterior lumbosacral arthrodesis, Spine 33 (16) (2018) 1806–1811.