



Imaging in Suspected Renal Colic: Systematic Review of the Literature and Multispecialty Consensus

Christopher L. Moore, MD*¹; Christopher R. Carpenter, MD, MSc²; Marta E. Heilbrun, MD³; Kevin Klauer, DO, EJD⁴; Amy Krambeck, MD⁵; Courtney Moreno, MD⁶; Erick M. Remer, MD⁷; Charles Scales, MD⁸; Melissa M. Shaw, BS⁹; Kevan M. Sternberg, MD¹⁰

*Corresponding Author. E-mail: Chris.moore@yale.edu, Twitter: [@cmoore433](https://twitter.com/cmoore433).

Study objective: Renal colic is common and computed tomography (CT) is frequently used when the diagnosis of kidney stone is suspected. CT is accurate but exposes patients to ionizing radiation and has not been shown to alter either interventional approaches or hospital admission rates. This multiorganizational transdisciplinary collaboration seeks evidence-based, multispecialty consensus on optimal imaging across different clinical scenarios in patients with suspected renal colic in the acute setting.

Methods: In conjunction with the American College of Emergency Physicians (ACEP) Emergency Quality Network, we formed a 9-member panel with 3 physician representatives each from ACEP, the American College of Radiology, and the American Urology Association. A systematic literature review was used as the basis for a 3-step modified Delphi process to seek consensus on optimal imaging in 29 specific clinical scenarios.

Results: From an initial search yielding 6,337 records, there were 232 relevant articles of acceptable evidence quality to guide the literature summary. At the completion of the Delphi process consensus, out of the 29 scenarios agreement was rated as perfect in 15 (52%), excellent in 8 (28%), good in 3 (10%), and moderate in 3 (10%). There were no scenarios in which at least moderate consensus was not reached. CT was recommended in 7 scenarios (24%), with ultrasonography in 9 (31%) and no further imaging needed in 12 (45%).

Conclusion: Evidence and multispecialty consensus support ultrasonography or no further imaging in specific clinical scenarios, with reduced-radiation-dose CT to be used when CT is needed for patients with suspected renal colic. [Ann Emerg Med. 2019;74:391-399.]

Please see page 392 for the Editor's Capsule Summary of this article.

0196-0644/\$-see front matter

Copyright © 2019 by the American College of Emergency Physicians. This is an open access article under the CC BY-NC-ND license (<http://creativecommons.org/licenses/by-nc-nd/4.0/>).
<https://doi.org/10.1016/j.annemergmed.2019.04.021>

INTRODUCTION

Background

There are greater than 2 million annual emergency department (ED) visits for suspected renal colic in the United States, and computed tomography (CT) scanning is now performed for more than 90% of patients who receive a diagnosis of kidney stone.^{1,2} Despite a significant increase in CT use for diagnosis during the last 2 decades, patient-centered outcomes such as admission and intervention do not appear to have been affected.^{3,4} In 2014, a multicenter prospective trial randomized patients with suspected renal colic to CT, radiology-performed ultrasonography, or point-of-care ultrasonography and concluded that initial ultrasonography reduced radiation exposure without adversely affecting patient-centered outcomes.⁵ Despite this evidence, recent data suggest that ultrasonography is used

for less than 7% of patients receiving a diagnosis of kidney stone, and CT use has continued to increase.¹ Similarly, although reduced-radiation-dose CT is recommended for the evaluation of renal colic, it is used for less than 10% of patients with kidney stone.⁶

Renal colic is a self-limited condition in most patients. However, CT can effectively guide therapy in the subset of patients requiring urologic intervention and can detect alternate conditions in patients with similar symptoms (eg, appendicitis). There is wide practice variation in the initial imaging decisions in patients with renal colic.⁷ Although guidelines on “appropriate use” have been developed, they tend to emphasize CT without providing guidance on optimal imaging or scenarios in which CT may not be needed.⁸⁻¹⁰

We convened a multispecialty group with representation from national organizations including emergency medicine,

Editor's Capsule Summary*What is already known on this topic*

Computed tomography (CT) scanning is commonly used for patients with suspected renal colic, and ultrasonography may be underused.

What question this study addressed

This literature review and multispecialty expert panel sought to reach consensus on imaging strategies in different clinical scenarios and to specify when CT was not necessary in the emergency department (ED).

What this study adds to our knowledge

Urologists, radiologists, and emergency physicians agreed that in many scenarios, CT is not necessary.

How this is relevant to clinical practice

CT is not necessary in the ED evaluation of many patients with suspected renal colic, and the decision should be influenced by factors including age, clinical suspicion, history of kidney stone, pregnancy, and relief of pain.

urology, and radiology to perform a systematic literature review and seek consensus on imaging approaches in specific clinical scenarios in which renal colic was suspected, with an emphasis on situations in which CT may not be required.

MATERIALS AND METHODS

This initiative was formed under the Emergency Quality Network (<https://www.acep.org/equal/>), a Centers for Medicare & Medicaid Services–funded Support and Alignment Network, which is part of a Transforming Clinical Practice Initiative and administered through the American College of Emergency Physicians (ACEP). A 9-member panel was sought, with representation from 3 specialty societies: ACEP (through the Emergency Quality Network) (C.L.M., C.R.C., and K.K.), the American College of Radiology (M.H., C.M., and E.M.R.), and the American Urological Association (A.K., C.S., and K.S.). All panel members were board-certified practicing academic physicians and were nominated according to previous work on specialty-specific guidelines. The project was led by C.L.M.

Consensus definitions are included in [Appendix E1](#), available online at <http://www.annemergmed.com>. The clinical question was, “For patients presenting to the ED with pain suspected to be uncomplicated renal colic, what

imaging should be pursued compared with standard noncontrast CT scanning to optimize patient-centered outcomes?”

A systematic literature review was performed that followed the Preferred Reporting Items for Systematic Reviews and Meta-analyses guidelines. National Library of Medicine PubMed and EMBASE databases were queried for English-language articles published between January 1995 and May 2018, using a search strategy including Medical Subject Headings, as well as key words ([Appendix E2](#), available online at <http://www.annemergmed.com>). Relevant articles were rated for quality of evidence with a hybrid tool that combined the Quality Assessment of Diagnostic Accuracy Studies–2 instrument with the ACEP Clinical Policy Committee criteria for diagnostic questions to rate evidence as I, II, III, or X ([Appendix E3](#), available online at <http://www.annemergmed.com>). Some articles not amenable to rating by this tool were included after review, rated “n/a” (not applicable).

After reviewing and summarizing the literature for imaging modalities, we delineated specific clinical scenarios to illustrate decisionmaking with respect to initial imaging. We composed 29 brief clinical vignettes representing a balance of possible permutations (age, sex, pregnancy status, likelihood of stone disease, and likelihood of acute alternative diagnosis) ([Table 1](#)). Consensus was sought with a modified Delphi process that included 3 rounds of anonymous voting, with 2 group discussions between rounds. All 9 members of the group answered the vignettes in a blinded fashion.

For each clinical scenario, the physician was asked to select the “optimal diagnostic imaging strategy,” using a priori definitions ([Appendix E1](#), available online at <http://www.annemergmed.com>). Imaging options included no (further) imaging, point-of-care ultrasonography, radiology-performed ultrasonography, reduced-radiation-dose CT, standard CT (noncontrast), and CT with intravenous contrast. For purposes of defining consensus, imaging modalities were separated into 3 groups (no further imaging, ultrasonography, and CT), although subtypes within imaging modalities are reported. A priori, consensus was defined as perfect (9/9), excellent (8/9), good (6 to 7/9), moderate (5/9), and not reached (<5/9).

RESULTS

Of 6,337 articles screened, 232 were deemed relevant, with acceptable methodology ([Figure](#); [Appendix E4](#), available online at <http://www.annemergmed.com>). Of key articles provided by authors blinded to the search results, 100% (95% confidence interval 93% to 100%) were

Table 1. Clinical vignettes with level of agreement and imaging modality (after third round of voting).

Question No.	Vignettes	Agreement	Answers
1	A 35-y-old man with 2 previous kidney stones that passed spontaneously presents with an acute onset of flank pain during the last 3 h. He reports nausea with vomiting and has hematuria on urine dip. He has no abdominal tenderness. His pain is relieved after intravenous analgesics.	Moderate	5 POCUS, 4 no imaging
2	A 55-y-old man with 2 previous kidney stones that passed spontaneously presents with an acute onset of flank pain during the last 3 h. He reports nausea with vomiting and has hematuria on urine dip. He has no abdominal tenderness. His pain is relieved after intravenous analgesics.	Moderate	5 no imaging, 4 POCUS
3	A 75-y-old man with 2 previous kidney stones that passed spontaneously presents with an acute onset of flank pain during the last 3 h. He reports nausea with vomiting and has hematuria on urine dip. He has no abdominal tenderness. His pain is relieved after intravenous analgesics.	Good	7 RDCT, 2 ultrasonography (1 POCUS, 1 RPUS)
4	A 35-y-old man with no history of kidney stones presents with an acute onset of flank pain during the last 3 h. He reports nausea with vomiting and has hematuria on urine dip. He has no abdominal tenderness. His pain is relieved after intravenous analgesics.	Perfect	9 POCUS
5	A 55-y-old man with no history of kidney stones presents with an acute onset of flank pain during the last 3 h. He reports nausea with vomiting and has hematuria on urine dip. He has no abdominal tenderness. His pain is relieved after intravenous analgesics.	Excellent	8 RDCT, 1 POCUS
6	A 75-y-old man with no history of kidney stones presents with an acute onset of flank pain during the last 3 h. He reports nausea with vomiting and has hematuria on urine dip. He has no abdominal tenderness. His pain is relieved after intravenous analgesics.	Perfect	9 RDCT
7	A 35-y-old man with 2 previous kidney stones that passed spontaneously presents with an acute onset of flank pain during the last 3 h. He reports nausea with vomiting and has hematuria on urine dip. He has no abdominal tenderness. His pain is relieved after intravenous analgesics. Ultrasonography is performed; there is hydronephrosis on the side with the pain, and a stone is not visualized.	Perfect	9 no imaging
8	A 35-y-old man with 2 previous kidney stones that passed spontaneously presents with an acute onset of flank pain during the last 3 h. He reports nausea with vomiting and has hematuria on urine dip. He has no abdominal tenderness. His pain is relieved after intravenous analgesics. Ultrasonography is performed; there is no hydronephrosis, and a stone is not visualized.	Perfect	9 no imaging
9	A 35-y-old man with no history of kidney stones presents with an acute onset of flank pain during the last 3 h. He reports nausea with vomiting and has hematuria on urine dip. He has no abdominal tenderness. His pain is not relieved after intravenous analgesics.	Perfect	9 RDCT
10	A 35-y-old man with no history of kidney stones presents with an acute onset of flank pain during the last 3 h. He reports nausea with vomiting and has hematuria on urine dip. He has no abdominal tenderness. His pain is relieved after intravenous analgesics. Ultrasonography is performed; there is hydronephrosis on the side with the pain, and a stone is not visualized.	Excellent	8 no imaging, 1 RDCT
11	A 35-y-old man with no history of kidney stones presents with an acute onset of flank pain during the last 3 h. He reports nausea with vomiting and has hematuria on urine dip. He has no abdominal tenderness. His pain is relieved after intravenous analgesics. Ultrasonography is performed; there is no hydronephrosis, and a stone is not visualized.	Excellent	8 no imaging, 1 RDCT
12	A 35-y-old woman with no history of kidney stones presents with an acute onset of flank pain during the last 3 h. She reports nausea with vomiting and has hematuria on urine dip. She has no abdominal tenderness. Her pain is relieved after intravenous analgesics.	Excellent	8 ultrasonography (6 POCUS, 2 RPUS), 1 RDCT

Table 1. Continued.

Question No.	Vignettes	Agreement	Answers
13	A 35-y-old man with 2 previous kidney stones that passed spontaneously presents with left flank pain during the last 2 days. He reports nausea but no vomiting and has hematuria on urine dip. He has some left lower quadrant abdominal tenderness. His pain is relieved after intravenous analgesics.	Good	7 POCUS, 2 RDCT
14	A 35-y-old man with 2 previous kidney stones that passed spontaneously presents with left flank pain during the last 2 days. He reports nausea but no vomiting and has hematuria on urine dip. He has some left lower quadrant abdominal tenderness. His pain is relieved after intravenous analgesics. Ultrasonography is performed; there is hydronephrosis on the side with the pain, and a stone is not visualized.	Excellent	8 no imaging, 1 RDCT
15	A 35-y-old man with 2 previous kidney stones that passed spontaneously presents with left flank pain during the last 2 days. He reports nausea but no vomiting and has hematuria on urine dip. He has some left lower quadrant abdominal tenderness. His pain is relieved after intravenous analgesics. Ultrasonography is performed; there is no hydronephrosis, and a stone is not visualized.	Moderate	5 no imaging, 4 RDCT
16	A 35-y-old man with no history of kidney stones presents with left flank pain during the last 2 days. He reports nausea but no vomiting and has hematuria on urine dip. He has some left lower quadrant abdominal tenderness. His pain is relieved after intravenous analgesics.	Excellent	8 RDCT, 1 POCUS
17	A 55-y-old man with no history of kidney stones presents with left flank pain during the last 2 days. He reports nausea but no vomiting and has hematuria on urine dip. He has some left lower quadrant abdominal tenderness. His pain is relieved after intravenous analgesics.	Perfect	9 CT (7 RDCT, 1 NCCT, 1 CT IV CON)
18	A 75-y-old man with no history of kidney stones presents with left flank pain during the last 2 days. He reports nausea but no vomiting and has hematuria on urine dip. He has some left lower quadrant abdominal tenderness. His pain is relieved after intravenous analgesics.	Perfect	9 CT (5 NCCT, 4 CT IV CON)
19	A 35-y-old woman who is 10 weeks pregnant with no history of kidney stones presents with an acute onset of right flank pain during the last 3 h. She reports nausea with vomiting and has hematuria on urine dip. She has no abdominal tenderness. Her pain is relieved after intravenous analgesics.	Perfect	9 ultrasonography (8 RPUS, 1 POCUS)
20	A 35-y-old woman who is 10 weeks pregnant with no history of kidney stones presents with an acute onset of right flank pain during the last 3 h. She reports nausea with vomiting and has hematuria on urine dip. She has no abdominal tenderness. Her pain is relieved after intravenous analgesics. Ultrasonography is performed; there is hydronephrosis on the side with the pain, and a stone is not visualized.	Perfect	9 no imaging
21	A 35-y-old woman who is 10 weeks pregnant with no history of kidney stones presents with an acute onset of right flank pain during the last 3 h. She reports nausea with vomiting and has hematuria on urine dip. She has no abdominal tenderness. Her pain is relieved after intravenous analgesics. Ultrasonography is performed; there is no hydronephrosis, and a stone is not visualized.	Excellent	8 no imaging, 1 RPUS
22	A 35-y-old woman who is 30 weeks pregnant with no history of kidney stones presents with an acute onset of right flank pain during the last 3 h. She reports nausea with vomiting and has hematuria on urine dip. She has no abdominal tenderness. Her pain is relieved after intravenous analgesics.	Perfect	9 ultrasonography (8 RPUS, 1 POCUS)
23	A 35-y-old woman who is 30 weeks pregnant with no history of kidney stones presents with an acute onset of right flank pain during the last 3 h. She reports nausea with vomiting and has hematuria on urine dip. She has no abdominal tenderness. Her pain is relieved after intravenous analgesics. Ultrasonography is performed; there is hydronephrosis on the side with the pain, and a stone is not visualized.	Perfect	9 no imaging

Table 1. Continued.

Question No.	Vignettes	Agreement	Answers
24	A 35-y-old man was treated in the ED the previous day with an acute onset of right flank pain, and a CT was performed that showed a 4-mm stone in the proximal right ureter, with some hydronephrosis. He presents today with recurrent, severe right flank pain.	Perfect	9 no imaging
25	A 12-y-old boy with no history of kidney stones presents with an acute onset of flank pain during the last 3 h. He reports nausea with vomiting and has hematuria on urine dip. He has no abdominal tenderness. His pain is relieved after intravenous analgesics.	Perfect	9 ultrasonography (7 RPUS, 2 POCUS)
26	A 12-y-old boy with no history of kidney stones presents with an acute onset of flank pain during the last 3 h. He reports nausea with vomiting and has hematuria on urine dip. He has no abdominal tenderness. His pain is relieved after intravenous analgesics. Ultrasonography is performed; there is hydronephrosis on the side with the pain, and a stone is not visualized.	Perfect	9 no imaging
27	A 12-y-old boy with no history of kidney stones presents with an acute onset of flank pain during the last 3 h. He reports nausea with vomiting and has hematuria on urine dip. He has no abdominal tenderness. His pain is relieved after intravenous analgesics. Ultrasonography is performed; there is no hydronephrosis, and a stone is not visualized.	Excellent	8 no imaging, 1 RDCT
28	A 35-y-old man with kidney stones who underwent shock-wave lithotripsy without stent placement 2 days ago presents with an acute onset of flank pain during the last 3 h. He reports nausea with vomiting and has hematuria on urine dip. He has no abdominal tenderness. His pain is relieved after intravenous analgesics.	Good	7 ultrasonography (6 RPUS, 1 POCUS), 2 RDCT
29	A 35-y-old man with a 6-mm left-sided ureteral stone diagnosed by CT underwent stent placement yesterday. He presents with left flank and suprapubic pain worsening for the past 24 h. He has some nausea without vomiting. He has microscopic hematuria, but no abdominal tenderness. His pain is relieved after intravenous analgesics.	Perfect	9 POCUS

POCUS, Point-of-care ultrasonography; RDCT, reduced-radiation-dose CT; RPUS, radiology-performed ultrasonography; IV CON, intravenous contrast.

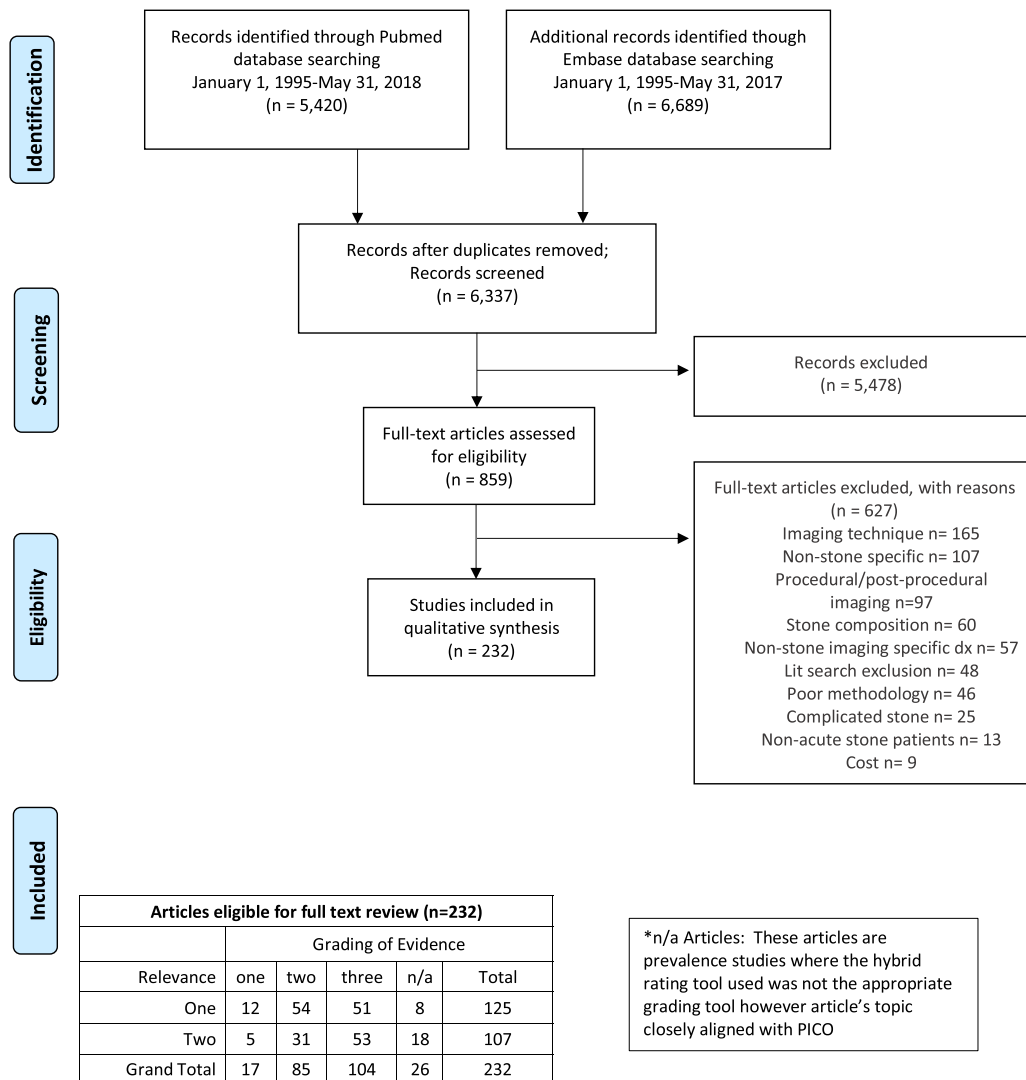
identified, indicating excellent capture of relevant articles. Interobserver agreement for inclusion or exclusion yielded a κ of 0.45 (95% confidence interval 0.26 to 0.63).

Abbreviated review of the literature for the main imaging modalities (radiology-performed ultrasonography, point-of-care ultrasonography, standard CT, and reduced-radiation-dose CT) that was used as the basis for the discussion and the consensus process follows.

For radiology-performed ultrasonography, there were 43 relevant articles with grades of evidence 1 (n=3), 2 (n=17), 3 (n=20), and n/a (n=3). Reported sensitivity of radiology-performed ultrasonography for kidney stone varied widely, ranging from 3% to 98%, depending on whether direct stone visualization was required or whether indirect evidence of stone presence (hydronephrosis) was sufficient.^{11,12} Although radiology-performed ultrasonography is less sensitive for detection of stones than CT, several studies show that it is unlikely to miss stones requiring intervention.¹³⁻¹⁵ For point-of-care ultrasonography, there were 15 articles with grades of evidence 1 (n=4), 2 (n=8), 3 (n=2), and n/a (n=1).

Diagnostic accuracy was based on presence of hydronephrosis rather than direct visualization of stone, and pooled results yielded sensitivity of 70.2% and specificity of 75.4%, although specificity increased to 94.4% when moderate or greater hydronephrosis was used as a criterion.¹⁶⁻¹⁸

CT is accepted as the reference modality for diagnosis of kidney stones, and we did not seek to assess the accuracy of CT for kidney stone; rather, we sought to understand how often CT identified other pathologies and affected management. There were 36 relevant articles addressing alternative findings on CT, with grades of evidence 1 (n=3), 2 (n=9), 3 (n=20), and n/a (n=4) (Table E1, available online at <http://www.annemergmed.com>). The prevalence of alternate findings ranged from 0% to 33%; however, definitions of acute alternate diagnoses varied widely. With consensus definitions (Appendix E1, available online at <http://www.annemergmed.com>), the prevalence of acute, clinically important alternate findings is typically less than 5%. Despite the potential for CT to predict need for intervention, studies have shown little change in rates of



From: Moher D, Liberati A, Tetzlaff J, Altman DG, The PRISMA Group (2009). Preferred Reporting Items for Systematic Reviews and Meta-Analyses: The PRISMA Statement. PLoS Med 6(7): e1000097. doi:10.1371/journal.pmed1000097

Figure. Preferred Reporting Items for Systematic Reviews and Meta-analyses 2009 flow diagram and evidence grading.

admission or intervention with increasing CT use.^{3,4} A secondary analysis of a multicenter randomized trial comparing ultrasonography with CT as an initial imaging modality found no significant difference between timing of urologic intervention based on the initial imaging modality.¹⁹

Although there is controversy in regard to risk of radiation from CT, most practitioners, radiologists, and organizations continue to adhere to the “as low as reasonably achievable” principle for radiation levels in diagnostic imaging. Statements from ACEP, the American College of Radiology, and the American Urological Association recommend using reduced-dose CT.^{8,10,20} Despite these recommendations, in 2011 to 2012 only 2%

of studies for suspected renal colic were performed with a reduced-radiation-dose CT technique, and as of 2015 to 2016, this percentage had increased to only 8%.⁶ There were 50 relevant articles on reduced-radiation-dose CT with evidence levels 1 (n=9), 2 (n=27), 3 (n=10), and n/a (n=4). For ureteral stone identification, sensitivities of reduced-radiation-dose CT range from 90% to 95% and specificities from 97% to 99%.²¹ Reduced-radiation-dose CT is particularly sensitive for larger stones, which are more likely to require intervention.^{22,23}

The level of consensus by round of voting, as well as proportions of imaging modalities recommended, is shown in Table 2. By the final round of voting, the group was able to reach perfect consensus in 15 of 29 vignettes (45%),

Table 2. Consensus level and imaging modality by round in the modified Delphi process.

	Vignettes (out of 29)		
	Round 1, No. (%)	Round 2, No. (%)	Round 3, No. (%)
Perfect	6 (21)	12 (29)	15 (52)
Excellent	3 (10)	6 (21)	8 (28)
Good	11 (38)	6 (21)	3 (10)
Moderate	7 (24)	4 (14)	3 (10)
Not reached	2 (7)	1 (3)	0
No further imaging	13 (45)	13 (45)	13 (45)
Ultrasonography	7 (24)	7 (24)	9 (31)
CT	7 (24)	8 (28)	7 (24)
No consensus	2 (7)	1 (3)	0

with at least moderate consensus in all scenarios. CT continued to be recommended in 7 of 29 scenarios (24%). All vignettes, along with final level of consensus and voting by modality, are shown in [Table 1](#).

LIMITATIONS

Many more permutations of the clinical vignettes were possible. We chose 29 scenarios to represent the best balance of major factors with the least number of scenarios. The scenarios are skewed toward those in which the clinical likelihood of a kidney stone is high according to objective criteria.²⁴ Although we did include scenarios with stone being less likely and found that in these scenarios practitioners were more likely to request CT, there may have been a bias toward assuming these scenarios represented kidney stone and no other diagnosis.

The definition of “consensus” varies across the Delphi process.²⁵ Although a simple majority (5/9) may be considered a low bar for consensus, we did reach a consensus level of at least 8 of 9 in 80% of scenarios. Consensus levels were defined before voting, and we chose to emphasize transparency. The work of this group represents an expert consensus with representation from 3 specialties. Although our process differed from specialty-specific guideline development, we were unable to find an existing process for endorsement by 3 specialty societies and believed that our process represented the best approach for the multispecialty nature of this work.

DISCUSSION

To our knowledge, this article presents the first systematic, multispecialty, evidence-based consensus in regard to imaging in renal colic. We were able to reach

consensus across specialties for specific clinical scenarios in which CT could be avoided. When CT is needed, a reduced-radiation approach should be used.

We reached at least moderate consensus in all scenarios, with perfect or excellent consensus in 80%. Question 1 is the base-case scenario: a 35-year-old man with a history of kidney stones who presents with typical symptoms and adequate pain relief. No respondents favored initial CT for this patient. Although 5 respondents recommended point-of-care ultrasonography, there was perfect consensus that no additional imaging was needed regardless of the presence or absence of hydronephrosis after point-of-care ultrasonography was performed (questions 7 and 8). In the same scenario but without history of stone (question 4), there was perfect consensus for point-of-care ultrasonography as the initial imaging modality.

One respondent recommended reduced-radiation-dose CT regardless of point-of-care ultrasonography result in the scenario in which the patient had no history of stone (question 4). This respondent was an emergency physician and this response is highlighted because it is in line with a common teaching in emergency medicine that every first-time stone requires CT. However, 8 of the 9 members of the group (including all 3 urologists) did not think a CT was required in this young patient with typical symptoms and relief of pain even if it was a first-time stone.

When the clinical presentation of the case was less typical in a patient with a history of stones (question 13), there was still good consensus that ultrasonography would be the best initial modality, although some respondents (2/9) favored CT. This suggests that as the presentation becomes less typical, CT is favored. Performance of point-of-care ultrasonography for a patient with less typical symptoms (questions 14 and 15) altered the recommendation for subsequent CT. Although there was still moderate consensus for no further imaging for a young patient with atypical symptoms and no hydronephrosis (5/9; question 15), the absence of hydronephrosis on point-of-care ultrasonography led 4 of 9 respondents to recommend reduced-radiation-dose CT. Daniels et al¹⁷ likewise suggested that for patients with a moderate likelihood of stone and point-of-care ultrasonography demonstrating hydronephrosis, no further imaging is indicated, whereas absence of hydronephrosis suggests that an alternate diagnosis should be considered.

Questions 2 and 3, 5 and 6, and 17 and 18 included scenarios identical to those of questions 1, 4, and 16, with ages altered to 55 and 75 years. For aged 75 years, regardless of history of stones or presentation, there was good to perfect consensus that CT should be obtained, with reduced-radiation-dose CT favored (questions 3, 6,

and 18). For aged 55 years, when there was a history of a kidney stone and a typical presentation (question 2), there was moderate consensus (5/9) for no imaging, with the remainder of participants (4/9) recommending point-of-care ultrasonography. For a 55-year-old with no history of kidney stone, there was perfect consensus that reduced-radiation-dose CT should be obtained (question 4), with perfect consensus that CT be obtained with a less typical presentation (question 17).

When the base case was varied to the female sex in a young patient with no history of stones (question 12), there was excellent consensus for ultrasonography (8/9), with 6 respondents recommending point-of-care ultrasonography. Two respondents chose radiology-performed ultrasonography (versus none with the male sex), which would be reasonable, particularly if radiology ultrasonography were definitive for stone size and location, allowing avoidance of CT. Radiology-performed ultrasonography may also be diagnostic of pelvic or adnexal pathology that could be present acutely in a female patient.

Even for a young patient with a history of stones and whose symptoms could not be appropriately relieved, reduced-radiation-dose CT was recommended with perfect consensus (question 9). We acknowledge that a short period of observation may be necessary, and if adequate analgesia cannot be achieved, reduced-radiation-dose CT may identify a stone requiring intervention.

There was perfect consensus that for a patient with stent placement for kidney stone, point-of-care ultrasonography was the preferred test (question 29). The presence of hydronephrosis suggests a nonfunctioning stent, whereas in the absence of hydronephrosis with adequate pain control, the patient could be discharged without further imaging. For a patient with pain after lithotripsy, there was good consensus that ultrasonography should be performed, with 5 respondents favoring radiology-performed ultrasonography. The urologists noted that radiology-performed ultrasonography would be more likely to identify a postprocedural hematoma, favoring radiology-performed ultrasonography over point-of-care ultrasonography.

If CT is not initially performed, some patients will require subsequent CT if the stone does not pass spontaneously. This should be explained to patients before discharge (suggested follow-up instructions are shown in [Appendix E5](#), available online at <http://www.annemergmed.com>).

In summary, in accordance with systematic literature review and consensus by a modified Delphi method, we recommend that for younger patients (≈ 35 years), even without a history of stones, CT may be avoided as long as

pain is controlled (perfect consensus). For middle-aged patients (≈ 55 years), we recommend CT if there is no history of kidney stones. For older patients, we recommend CT regardless of history. Pregnant and pediatric patients with a typical presentation should undergo ultrasonography and do not require initial CT if symptoms are relieved. We recommend reduced-radiation-dose CT whenever CT is used for suspected renal colic.

The authors acknowledge the support of ACEP; specifically, Jeremiah Schuur, MD, and Arjun Venkatesh, MD, principal investigators for the ACEP Emergency Quality Network initiative.

Supervising editor: Gregory W. Hendey, MD. Specific detailed information about possible conflict of interest for individual editors is available at <https://www.annemergmed.com/editors>.

Author affiliations: From the Department of Emergency Medicine, Yale University School of Medicine, New Haven, CT (Moore, Shaw); the Department of Emergency Medicine, Washington University in Saint Louis, Saint Louis, MO (Carpenter); the Department of Radiology & Imaging Sciences, Emory University School of Medicine, Atlanta, GA (Heilbrun, Krambeck, Moreno); the Department of Family Medicine, University of Tennessee, Knoxville, TN and the Department of Osteopathic Specialties, Michigan State University, East Lansing, MI (Klauer); Imaging Institute and Glickman Urological and Kidney Institute, Cleveland Clinic, Cleveland, OH (Remer); Duke Clinical Research Institute and the Department of Surgery (Urology), Duke University, School of Medicine Durham, NC (Scales); and the Department of Urology, University of Vermont Medical Center, Burlington, VT.

Author contributions: CLM conceived the study. AL, CLM, EKR, KK, and MS drafted the article. All authors designed the analysis methods and performed data collection. All authors interpreted and analyzed the data, edited the article, and approved the final article for publication. CLM takes responsibility for the paper as a whole.

All authors attest to meeting the four [ICMJE.org](http://www.icmje.org) authorship criteria: (1) Substantial contributions to the conception or design of the work; or the acquisition, analysis, or interpretation of data for the work; AND (2) Drafting the work or revising it critically for important intellectual content; AND (3) Final approval of the version to be published; AND (4) Agreement to be accountable for all aspects of the work in ensuring that questions related to the accuracy or integrity of any part of the work are appropriately investigated and resolved.

Funding and support: By *Annals* policy, all authors are required to disclose any and all commercial, financial, and other relationships in any way related to the subject of this article as per ICMJE conflict of interest guidelines (see www.icmje.org). This work was supported by the Agency for Healthcare Research and Quality grant R18HS023778. Dr. Moore declares grant funds from the Agency for Healthcare Research and Quality and Philips Healthcare, nonfinancial support from BK Medical and GE Healthcare, and is a consultant for American College of Emergency Physicians. Dr.

Krambeck is a consultant for Lumenis and Boston Scientific. Dr. Scales declares grant funds from NIDDK and Allena Pharmaceuticals. Ms. Shaw declares grant funds from the Agency for Healthcare Research and Quality. Dr. Sternberg is a consultant for Bard Endourology.

Publication dates: Received for publication February 27, 2019. Revision received April 12, 2019. Accepted for publication April 18, 2019.

REFERENCES

- Chang H, Dai J, Holt S, et al. National imaging trends for acute kidney stone disease: do renal ultrasounds for nephrolithiasis in the emergency department pave the way to computerized tomography? *J Urol*. 2018;199:e683-e684.
- Fwu C-W, Eggers PW, Kimmel PL, et al. Emergency department visits, use of imaging, and drugs for urolithiasis have increased in the United States. *Kidney Int*. 2013;83:479-486.
- Gottlieb RH, Erturk EN, Sotack JL, et al. CT in detecting urinary tract calculi: influence on patient imaging and clinical outcomes. *Radiology*. 2002;225:441-449.
- Westphalen AC, Hsia RY, Maselli JH, et al. Radiological imaging of patients with suspected urinary tract stones: national trends, diagnoses, and predictors. *Acad Emerg Med*. 2011;18:699-707.
- Smith-Bindman R, Aubin C, Bailitz J, et al. Ultrasonography versus computed tomography for suspected nephrolithiasis. *N Engl J Med*. 2014;371:1100-1110.
- Weisenthal K, Karthik P, Shaw M, et al. Evaluation of kidney stones with reduced-radiation dose CT: progress from 2011-2012 to 2015-2016—not there yet. *Radiology*. 2017;286:581-589.
- Schoenfeld EM, Pekow PS, Shieh MS, et al. The diagnosis and management of patients with renal colic across a sample of US hospitals: high CT utilization despite low rates of admission and inpatient urologic intervention. *PLoS One*. 2017;12:e0169160.
- Coursey CA, Casalino DD, Remer EM, et al. ACR appropriateness criteria acute onset flank pain—suspicion of stone disease. *Ultrasound Q*. 2012;28:227-233.
- American College of Radiology ACR Appropriateness Criteria Acute Onset Flank Pain—Suspicion of Stone Disease (Urolithiasis). 2015. Available at: <https://acsearch.acr.org/docs/69362/narrative>. Accessed May 7, 2019.
- Fulgham PF, Assimos DG, Pearle MS, et al. Clinical effectiveness protocols for imaging in the management of ureteral calculous disease: AUA technology assessment. *J Urol*. 2013;189:1203-1213.
- Hamm M, Wawroschek F, Weckerman D, et al. Unenhanced helical computed tomography in the evaluation of acute flank pain. *Eur Urol*. 2001;39:460-465.
- Abdel-Gawad M, Kadasne R, Anjekar C, et al. Value of color Doppler ultrasound, KUB and urinalysis in diagnosis of renal colic due to ureteral stones. *Int Braz J Urol*. 2014;40:513-519.
- Ekici S, Sinanoglu O. Comparison of conventional radiography combined with ultrasonography versus nonenhanced helical computed tomography in evaluation of patients with renal colic. *Urol Res*. 2012;40:543-547.
- Kobayashi T, Nishizawa K, Watanbe J, et al. Clinical characteristics of ureteral calculi detected by nonenhanced computerized tomography after unclear results of plain radiography and ultrasonography. *J Urol*. 2003;170:799-802.
- Ripollés T, Agramunt M, Errando J, et al. Suspected ureteral colic: plain film and sonography vs unenhanced helical CT. A prospective study in 66 patients. *Eur Radiol*. 2004;14:129-136.
- Wong C, Teitge B, Ross M, et al. The accuracy and prognostic value of point-of-care ultrasound for nephrolithiasis in the emergency department: a systematic review and meta-analysis. *Acad Emerg Med*. 2018;25:684-698.
- Daniels B, Gross CP, Molinaro A, et al. STONE PLUS: evaluation of emergency department patients with suspected renal colic, using a clinical prediction tool combined with point-of-care limited ultrasonography. *Ann Emerg Med*. 2016;67:439-448.
- Herbst MK, Rosenberg G, Daniels B, et al. Effect of provider experience on clinician-performed ultrasonography for hydronephrosis in patients with suspected renal colic. *Ann Emerg Med*. 2014;64:269-276.
- Metzler IS, Smith-Bindman R, Moghadassi M, et al. Emergency department imaging modality effect on surgical management of nephrolithiasis: a multicenter, randomized clinical trial. *J Urol*. 2017;197:710-714.
- Sierzenski PR, Linton OW, Stephen Amis E, et al. Applications of justification and optimization in medical imaging: examples of clinical guidance for computed tomography use in emergency medicine. *Ann Emerg Med*. 2014;63:25-32.
- Niemann T, Kollmann T, Bongartz G. Diagnostic performance of low-dose CT for the detection of urolithiasis: a meta-analysis. *AJR Am J Roentgenol*. 2008;191:396-401.
- Poletti P-A, Platon A, Rutschmann OT, et al. Low-dose versus standard-dose CT protocol in patients with clinically suspected renal colic. *AJR Am J Roentgenol*. 2007;188:927-933.
- Glazer DI, Maturen KE, Cohan RH, et al. Assessment of 1 mSv urinary tract stone CT with model-based iterative reconstruction. *AJR Am J Roentgenol*. 2014;203:1230-1235.
- Moore CL, Bomann S, Daniels B, et al. Derivation and validation of a clinical prediction rule for uncomplicated ureteral stone—the STONE score: retrospective and prospective observational cohort studies. *BMJ*. 2014;348:g2191.
- Boulkedid R, Abdoul H, Loustau M, et al. Using and reporting the Delphi method for selecting healthcare quality indicators: a systematic review. *PLoS One*. 2011;6:e20476.