

Received:  
17 January 2019  
Revised:  
12 April 2019  
Accepted:  
16 April 2019

Cite as: İsmail Çalıkoğlu,  
Görkem Özgen,  
Toygar Toydemir,  
Mehmet Ali Yerdel.  
Iatrogenic cardiac tamponade  
as a mortal complication of  
peri-hiatal surgery. Analysis  
of 30 published cases.  
Heliyon 5 (2019) e01537.  
doi: [10.1016/j.heliyon.2019.e01537](https://doi.org/10.1016/j.heliyon.2019.e01537)



Review Article

# Iatrogenic cardiac tamponade as a mortal complication of peri-hiatal surgery. Analysis of 30 published cases

İsmail Çalıkoğlu, Görkem Özgen, Toygar Toydemir, Mehmet Ali Yerdel\*

*İstanbul Bariatrics and Advanced Laparoscopy Center, Hakkı Yeten Cad., Polat Tower, No: 12, 34343 Fulya-İstanbul, Turkey*

\* Corresponding author.

E-mail address: [yerdel@yerdel.com](mailto:yerdel@yerdel.com) (M.A. Yerdel).

## Abstract

Iatrogenic cardiac tamponade (ICT) is a dreadful complication of peri-hiatal surgery and vast majority occur during a hernia repair. Strikingly, against all warnings, the incidents and related deaths seem to be increasing. The aim of this review is to provide insight on how to prevent and challenge ICT. PubMed search identified 30 distinct ICTs with 10 deaths (33.3%) due to peri-hiatal procedures. Twenty-nine operations were mechanical repairs and laparoscopic anti-reflux surgery was the primary cause (n:18). Graft fixation (n:23) and helical tacks (n:13) were the main offenders. Initial symptom was hypotension affecting 92%. Seven ICTs were only identified at autopsy. All treated patients except one underwent a drainage. Almost all ICTs were caused by injury to the diaphragmatic dome, anterior to hiatus. In conclusion, peri-hiatal surgery-related ICT is extremely fatal. ICT mainly occurs during the repair of a hernia, a benign condition and therefore must be prevented. Graft fixation, around the ante-hiatal diaphragmatic dome must be abandoned. If mesh-augmentation is absolutely necessary, meticulous stitching must be preferred instead of fixators. Persistent hypotension during or following a peri-hiatal operation is an alarming sign of ICT. Increased awareness is mandatory for prevention and survival.

Keywords: Medicine, Surgery, Cardiology

## 1. Introduction

Over the last two decades, increasing number of reports pointed out iatrogenic cardiac tamponade (ICT) as a mortal complication of graft fixation for the repair of peri-hiatal mechanical defects. Repair of hiatal [1, 2, 3, 4, 5, 6, 7, 8, 9, 10, 11, 12, 13, 14, 15], ventral [3, 9, 16, 17] and diaphragmatic hernias [18, 19, 20] with mesh-augmentation resulted in ICT and deaths. ICTs during peri-hiatal surgery unrelated to graft fixation were also reported [13, 21, 22, 23, 24, 25, 26].

The reported mortality is between 37.5-66.6% [9, 12] and the number of incidents seems to increase [2, 3]. This is unacceptable as ICT due to peri-hiatal surgical trauma almost exclusively occurs during the repair of a mechanical defect which is a benign condition.

As a referral center for the surgical treatment of hiatal hernias [27, 28], after confronting with an ICT following laparoscopic anti-reflux surgery [2] (LARS), we conducted an in-depth analysis of the reported cases in peer-reviewed medical journals. The main aim of this review is to emphasize the importance of *awareness* for the prevention and better management of this extremely mortal, but avoidable complication.

## 2. Main text

### 2.1. Materials and methods

#### 2.1.1. Inclusion criteria

All ICT cases that resulted from peri-hiatal surgical trauma published in peer reviewed scientific journals were our subjects. The literature search was carried out using the PubMed-MEDLINE database, combining keywords “cardiac tamponade”, “abdominal surgery”, “hiatal surgery”, “postoperative hernia”, “diaphragmatic hernia”, “ventral herniorraphy”, “fundoplication”, “hiatal hernia”, “paraesophageal hernia”, “nissen”, “toupet”, “heller”, “myotomy”, “achalasia”, “mesh”, “helical tack”, “straight hernia stapler”, “complication”, “pericardiocentesis”, “open pericardial drainage”, “cardiac injury”, “iatrogenic cardiac injury”, “traumatic cardiac tamponade” and “reflux”. No language restriction was used.

#### 2.1.2. Exclusion criteria

Peri-hiatal operations causing rhythm and electrocardiogram changes in the absence of ICT, cases where ICT did not result from the upper abdominal surgery itself,

extra-pericardial reasons causing tamponade, seroma collections in the pericardial sac or reactive pericarditis, and cases in which late pericardial effusions occurred as a consequence of gastro-pericardial fistula or of unknown causes were excluded.

Among 27 articles reporting on ICT due to peri-hiatal surgery, a double publication was found, first by the surgeons [25], then by the anesthetic team [29], and the latter was excluded. Cross-referencing of all patients in 26 articles revealed a case, that was published twice [4, 16] in an irrelevant context. After excluding this case, which was published in a criminology journal [4], 30 distinct ICT cases were analyzed (Fig. 1).

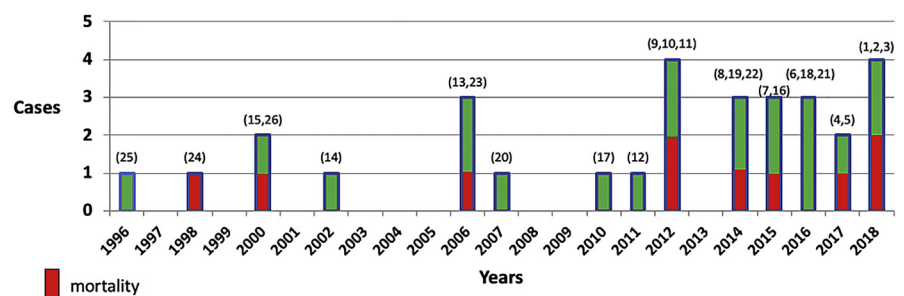
## 2.2. Results

ICT was graft fixation-related in 23 and due to other causes in 7 (Table 1 A-B). Twenty-four cases had laparoscopic surgery. LARS was the leading cause (n:18, 60%).

All ICTs in diaphragmatic [18, 19, 20] and ventral herniorrhaphies [3, 9, 16, 17] occurred because of graft fixation anterior to the hiatal opening. Regarding anti-reflux/hiatoplasties [2, 5, 7, 9, 11, 13], the injury occurred anterior to the hiatal opening except in one [12]. Among graft fixation-related ICTs, the most common cause of injury was helical tack (n:13, 56.5%). Excluding two cases with missing data [4, 9], 17 of 20 (85%) anti-reflux/hiatoplasties were performed in patients with giant hiatal hernias and/or in patients with re-do or complex repairs (Table 1).

The initial symptom in 23 of 25 (92%) patients was persistent hypotension (missing data:5), which varied in severity (i.e., from orthostatic hypotension to cardiac collapse) and became evident intraoperatively or as late as the eighth postoperative week. Echocardiography (EC) and tomography were efficient in diagnosing ICT. Tomography was also able to identify the cause of injury if hyperdense titanium helical tacks were the fixators [2, 6, 11].

ICT could only be identified at autopsy in 7 patients. ICT was diagnosed in 23 and 3 resulted in mortality. In 2 patients, diagnosis was established intraoperatively by



**Fig. 1.** Annual distribution of published cases and mortalities from iatrogenic cardiac tamponade as a result of peri-hiatal surgery. Numbers in parenthesis represent references.

**Table 1.** All reported cases of iatrogenic cardiac tamponade resulting from peri-hiatal surgery.

	Author	Sex	Age	Operation	Fixing method	Initial clinical findings	Timing of diagnosis	Diagnostic method	Treatment (day)	Injured by	Died (day)
A	Heuts [1]	F	73	LARS, giant hernia	PFD	H/T	NR	EC + T	OD (3)	PFD	NA
	Yerdel [2]	F	42	LARS, re-do, giant hernia	HT	H/T	8 h	EC + T	Expectant	HT	NA
	Köckerling [3]	F	65	LARS, giant PEH	SHS	NR	Undiagnosed	Autopsy	None	SHS	(3)
	Stockhausen [4]	F	61	LARS	Suture	Cardiogenic shock	Undiagnosed	Autopsy	None	Suture	(1)
	Lou [5]	F	51	LARS, giant PEH	Staple	H/T	2–3 h	T + EC	ODR (0)	Staple	NA
	Borrie [6]	M	48	OARS + OVHR, re-do	HT	H/T	1 day	EC + T	PC (2) + ODR (3)	HT	NA
	Fernandez [7]	M	46	LARS, giant hernia	SHS	Hypotension, chest pain	48 h	EC + MRI	PC/drain (3)	SHS	NA
	Fernandez [7]	F	62	LARS, giant hernia	SHS	Hypotension, dyspnea	5 days	T	OD (5)	SHS	NA
	Koepfen [8]	F	67	LARS	HT	Cardiogenic shock	Intraoperative	Esophageal EC	ODR (0)	HT	NA
	Frantzides [9]	NR	NR	LARS	HT	NR	Undiagnosed	Autopsy	None	HT	(0)
	Makarevich [10]	F	69	LARS, giant PEH	HT	Cardiogenic shock	3 days	EC	ODR (3)	HT	NA
	Sugumar [11]	F	75	LARS, giant PEH	HT	Chest pain, dyspnea	37 days	EC	OD (40)	HT	NA
	Paz [12]	F	61	LARS	HT	H/T	1 day	EC	PC/drain (1) + OD (1)	HT	NA
	Müller-Stich [13]	M	82	LARS,	HT	Dyspnea	Undiagnosed	Autopsy	None	HT	(2)

*(continued on next page)*

**Table 1.** (Continued)

Author	Sex	Age	Operation	Fixing method	Initial clinical findings	Timing of diagnosis	Diagnostic method	Treatment (day)	Injured by	Died (day)
Thijssens [14]	F	84	giant PEH LARS,	HT	H/T, shock	14 days	EC	PC (14) + ODR (14)	HT	NA
Kemppainen [15]	F	80	giant PEH LARS,	SHS	Unclear	Undiagnosed	Autopsy	None	SHS	(0)
Köckerling [3]	M	52	giant PEH OVHR	AT	NR	2 days	NR	PC (2), died during OD (2)	AT	(2)
Endlich [16]	M	62	LVHR	PFD	Hypotension, dyspnea	1 day	EC	PC (1), died during OD (1)	PFD	(1)
Frantzides [9]	M	42	LVHR	HT	H/T	Undiagnosed	Autopsy	None	HT	(0)
Malmstrom [17]	F	25	LVHR	HT	Hypotension, tachypnea	9 days	EC	PC/drain (9) + ODR (9)	HT	NA
McClellan [18]	F	31	LDHR + re-do gastric bypass	AT	Tachycardia, dyspnea	1 day	EC	PC/drain (1)	AT	NA
Jorgensen [19]	F	79	LDHR	HT	Cardiogenic shock	Undiagnosed	Autopsy	None	HT	(0)
Dapri [20]	F	57	LDHR	HT	NR	2 days	NR	ODR (2)	HT	NA
B Cockbain [21]	M	80	LARS, converted to open, giant PEH	NU	H/T, oliguria	1 day	T	PC/drain (1)	Unclear	NA
Hemetsberger [22]	F	75	LARS + Heller's myotomy	NU	H/T, low hemoglobin	21 days	EC + T + Angiography	PC twice (21) + coil embolization (22)	Suture	NA
Müller-Stich [13]	F	74	OARS, re-do, giant hernia	NA	Hypotension	2–3 h	T	ODR (0)	Suture	NA

(continued on next page)

**Table 1.** (Continued)

Author	Sex	Age	Operation	Fixing method	Initial clinical findings	Timing of diagnosis	Diagnostic method	Treatment (day)	Injured by	Died (day)
Puchakayala [23]	F	71	OARS, re-do Collis-Nissen, giant hernia	NU	H/T, dyspnea	32 h	Esophageal EC	PC (2) + ODR (2)	Unclear	NA
Trastek [24]	M	40	OARS, Uncut Collis-Nissen	NU	H/T	9 h	Clinical + PC	Died during OD (0)	Unclear	(0)
Firoozmand [25]	F	66	LARS, converted to open, giant PEH	NU	Operative hypotension	Intraoperative	Clinical	ODR (0)	Retractor	NA
Neri [26]	M	69	Open gastrectomy /hepatectomy	NU	H/T, dyspnea, chest pain	8 weeks	EC + T	ODR (56)	Suture	NA

AT, absorbable tack; EC, echocardiography; H/T, hypotension and tachycardia; HT, helical tack; LARS, laparoscopic anti-reflux surgery; LDHR, laparoscopic diaphragmatic hernia repair; LVHR, laparoscopic ventral hernia repair; MRI, magnetic resonance imaging; NA, not applicable; NR, not recorded; NU, not used; OARS, open anti-reflux surgery; OD, open drainage; ODR, open drainage and repair; OVHR, open ventral hernia repair; PC, pericardiocentesis; PEH, paraesophageal hernia; PFD, plastic fixing device; SHS, straight hernia staplers; T, tomography.

**Table 2.** Injury status at open drainage and autopsy.

Author	Treatment (day)	Open drainage findings /repair performed	Autopsy findings	Outcome (day)
Heust [1]	OD (3)	No active bleeding/hemostatic patch application to epicardial injury and removal of penetrating fixator	NA	Survived
Köckerling [3]	None/autopsy	NA	Coronary vein tear by EMS stapler	Died (3)
Stockhausen [4]	None/autopsy	NA	Suture injury to myocardium	Died (1)
Lou [5]	ODR (0)	Left circumflex coronary artery tear/ligation	NA	Survived
Borrie [6]	PC (2) + ODR (3)	Posterior descending coronary artery + vein injured by 3 penetrating tacks/sutured and coverage of tacks by bovine patch	NA	Survived
Fernandez [7]	OD (5)	No active bleeding	NA	Survived
Koeppen [8]	ODR (0)	Right ventricular laceration/sutured	NA	Survived
Frantzides [9]	None/autopsy	NA	Myocardial injury by penetrating tacks	Died (0)
Makarevicz [10]	ODR (3)	Posterior descending coronary artery + right ventricle + epicardial vein injured by 2 penetrating tacks/repair of artery, suturing of ventricular and venous tear, coverage of tacks by synthetic vascular patch	NA	Survived
Sugumar [11]	OD (40)	No active bleeding	NA	Survived
Paz [12]	PC/drain (1) + OD (1)	No active bleeding/1 penetrating tack is removed	NA	Survived
Müller-Stich [13]	None/autopsy	NA	Epicardial vascular injury by penetrated tack	Died (2)

*(continued on next page)*

**Table 2.** (Continued)

Author	Treatment (day)	Open drainage findings /repair performed	Autopsy findings	Outcome (day)
Thijssens [14]	PC (14) + ODR (14)	Epicardial laceration by penetrating tacks/ sutured, tacks removed	NA	Survived
Kemppainen [15]	None/autopsy	NA	Coronary vein tear by stapler	Died (0)
Jorgensen [19]	None/autopsy	NA	Right coronary artery injured by a penetrating tack	Died (0)
Dapri [20]	ODR (2)	Coronary artery injury at the diaphragmatic surface/sutured	NA	Survived
Köckerling [3]	PC (2) + ODR (2)	NA/died during OD attempt	4 penetrating tacks, myocardial injury by one	Died (2)
Endlich [16]	PC (1) + OD (1)	1-cm penetration of plastic fixation system into the right ventricle/died during OD attempt	NA	Died (1)
Frantzides [9]	None	NA	Epicardial vascular injury by tacks, 4 tacks seen penetrating	Died (0)
Malmstrom [17]	PC/drain (9) + ODR (9)	Right ventricular laceration by tacks, 5 tacks penetrating pericardium, 2 tacks penetrating pleura/tacks removed - sutured	NA	Survived
Müller-Stich [13]	ODR (0)	Right ventricular laceration/sutured	NA	Survived
Puchakayala [23]	PC (2) + ODR (2)	Coronary artery injury at the diaphragmatic surface, no pericardial opening is seen/ sutured	NA	Survived
Trastek [24]	OD (0)	Coronary vessel laceration/died during OD attempt	NA	Died (0)

(continued on next page)



**Table 2.** (Continued)

Author	Treatment (day)	Open drainage findings /repair performed	Autopsy findings	Outcome (day)
Firoozmand [25]	ODR (0)	Actively bleeding hole at the right ventricle, no pericardial opening is seen/sutured	NA	Survived
Neri [26]	ODR (56)	Suture tear of myocardium at the base of right ventricle/sutured	NA	Survived

NA, not applicable; ODR, open drainage and repair; OD, open drainage; PC, pericardiocentesis.

strong clinical suspicion prompting immediate open pericardial drainage (OD) and both survived.

Among treated 23 patients, a drainage became necessary in 22 (95.6%) and one patient was managed with expectant treatment [2]. Pericardiocentesis (PC) with drain insertion per se was performed in 3 patients and all survived. One other case [22], after 2 PC attempts, was diagnosed with an arterial bleeding by tomographic angiography, and successfully embolized with coil, eliminating the need for an OD, and also survived. Therefore, in 5 of 23 (21.7%) of the treated ICTs, OD was not required and there was no mortality. In 18 of 23 (78.3%) of the patients, OD, either per se (n:11) or in succession after PC, was performed and 3 died. Three patients among 23, who received treatment died, giving a mortality rate of 13%.

Autopsy and OD findings are summarized in Table 2. OD failed to show any active bleeding in 4 of 18 patients, who were simply drained without any repair, and all survived. In 14 patients, active bleeding, resulting either from a vascular (n:5) or myocardial (n:8) tear or both (n:1) was evident during the OD. Five of these vascular injuries affected branches of coronary arteries with venous involvement in two and all survived. All active bleedings during OD were controlled by suture repair. At autopsy, 5 patients had a vascular injury. Including the patient having coil embolization, 7 patients had a proven coronary artery branch tear among 30 ICTs (23.3%). Among mortalities, 6 out of 10 (60%) had a vascular tear as opposed to 6 out of 20 (30%) in survivors.

Ten patients died, giving an overall mortality rate of 33.3%. The mortality of ICT following an anti-reflux/hiatoplasty, diaphragmatic, and ventral hernia repair procedures were; 27.3%, 33.3% and 75% respectively. Among graft fixation-related ICTs, the mortality was 39.1%. In ICTs that were not related to graft fixation, the mortality was 14.2%. Nine of 10 deaths occurred because of graft fixation, and tacks were responsible from 5. All mortalities except 2 resulted from laparoscopic procedures, and 5 occurred within hours after surgery. Among the late 5 deaths occurring 1–3 days after surgery, 3 remained un-diagnosed until the first, second and the third postoperative day, and were only diagnosed at autopsy while other two died on-table during an OD attempt on the first and the second postoperative days. No mortality was observed in 20 patients who survived beyond 3 days after the injury.

### 3. Conclusions

#### 3.1. Discussion

No case of ICT resulting from peri-hiatal surgery was published before 1996. The first reported case was after LARS [25], and 29 cases were reported thereafter, strikingly, in an increasing order (Fig. 1). Approximately 85% of the ICTs were related to

laparoscopic surgery, and LARS was the cause in 60%. Hence, the impact of increased number of laparoscopic peri-hiatal operations and LARS in particular on the rate of ICT is clear.

ICT-related mortality during peri-hiatal operations was reported to be between 37.5-66.6% [9, 12]. The review identified 10 ICT-related deaths among 30 reported cases (33.3%). Interestingly, Frantzides and Welle [9] showed 5 unreported deaths by cross-referencing the US Food and Drug Administration's Manufacturer and User Facility Device Experience (FDA-MAUDE) data with published reports. A recent updated search of the FDA-MAUDE database identified additional 6 unreported deaths [18]. In addition to 10 reported fatalities, 11 unreported deaths suggest higher actual mortality [9, 18]. Twenty-one deaths, all resulting from instrumentation during a hernia repair, is certainly alarming.

Because of extreme mortality and the increasing number of incidents, the importance of prevention cannot be overemphasized. The main constraint comes from the anatomy of the central tendon of the diaphragm, where the heart directly sits on. The risk involving suturing the diaphragm from the abdominal side is known as the thickness of the diaphragm ranges between 1.5-5.4 mm [30]. Under pneumoperitoneum, a paralyzed diaphragm will be thinner [2]. The first warning criticizing the use of helical tack on diaphragm was published in Lancet in 2002 [14]. Tack manufacturers attached a note in 2004, discouraging its use on surfaces where thickness >4 mm could not be ensured [31, 32]. In 2011, they provided more specific warnings by contraindicating their use on diaphragm that is close to pericardium [33]. Nevertheless, "Tack usage must be abandoned in diaphragm" was the first sentence of the discussion in a recent report [19] although this had already been suggested more than a decade ago. However, since 85% of ICTs occurred during the management of complex hiatal hernias or extreme mechanical defects, it is reasonable to assume that the temptation to avoid recurrence, which is evidence-based, was the reason to overlook the possible risks involved when fixing a graft or putting stitches to the diaphragm. Mesh-augmentation was shown to decrease the recurrence rate of complicated/large hiatal hernias in all four randomized trials [34, 35, 36, 37] and in extreme diaphragmatic and ventral hernias, it is a routine. The evidence-based temptation, on the other hand, proved out to be a deadly flaw in at least 21 patients. Therefore, such evidence should not be applied to all peri-hiatal defects as the risk/benefit ratio must be individualized depending on the clinical significance and urgency of the hernia repair in question. Apparently, the diaphragmatic dome is an area where there is no guarantee for the safety of the use of any fixator or a stitch as all caused ICTs and the diaphragm thickness will be the primary determinant of the outcome. Graft fixation was the reason behind the vast majority of the reported ICTs and nearly all deaths would have been prevented if no mesh augmentation was employed. It is also noteworthy that graft fixation-related ICTs were three-fold more mortal compared to ICTs due to other reasons. Therefore, even if there is an absolute need for mesh-

augmentation to repair a vital hernia, extreme caution and avoidance of graft fixation to the central tendon is warranted.

Clearly, this review condemns any temptation to gain a recurrence benefit by mesh fixation around the diaphragmatic dome during LARS. Strikingly, LARS was responsible from 60% of the ICTs, and half of the deaths in this review. LARS is frequently performed for symptomatic relief and should never result in mortality as a result of any specific instrumentation. During LARS, Frantzides and Welle [9] suggested that straight hernia staplers rather than tacks must be used and applied posterior to the hiatus. The review also provided data that almost all injuries occurred around the central tendon, the thinnest part of the diaphragm, anterior to the hiatus. Our recent study provided data, regarding the anatomical vulnerability of the area anterior to the hiatal opening, where the pounding heart sits on the central tendon [2]. The incidence of ICT was 0.076% in 1302 consecutive LARS in our practice [2] but was zero when either no grafting or only posterior grafting was implemented. However, in 43 anteriorly grafted patients, the rate of ICT was 2.3% [2]. Carrying a 2.3% risk of cardiac injury with at least 33.3% mortality, no fixation can be safe in the ante-hiatal diaphragmatic dome and it must be abandoned. Nonetheless, during LARS, U-shaped posterior grafts can still be used, but again with caution, to avoid any fixation anterior to the hiatal opening.

In our analysis, approximately 60% of graft fixation-related and 45% of all ICT cases resulted from a helical tack injury. A survey identified tacks as the second choice for graft fixation following suturing, which were preferred by 23.9% and 56.4% of the participants respectively [38]. Review showed that helical tacks cause more deadly problems compared to most commonly used suturing. Notably, all 11 unreported deaths in FDA-MAUDE data were also caused by tacks [9, 18]. Thus, stitching [10, 20] or the use of staples with less penetration [9, 13] were suggested instead of helical tacks. They are applied under manual pressure against the tissue, causing further thinning down, and their deployment happens in an “all or none” manner with *state-of-the-art* drilling capacity. Helical tacks must be abandoned from use on the central tendon.

An unrecognized injury occurring in a patient under mechanical ventilation was unique to the injuries reported herein. Most cases were extremely challenging; in fact, almost 25% were diagnosed only at autopsy. The immediate postoperative period following a major surgical procedure complicates the diagnosis. The presented patient population with a mean age of 61, undergoing a major procedure in 85% of the occasions, were prone to a variety of more common complications. A tamponade masquerading as an ST segment elevation myocardial infarction [6], others mistreated as pulmonary embolism [13, 14] or myocardial infarction [3] or an ICT first treated invasively as a pneumothorax [25] have been reported.

Half of the deaths occurred several hours after surgery before any imaging could even be attempted. The 33.3% mortality rate also refers to the mortality rate in the first 72 hours following the injury. Patients who were undiagnosed all died, and the mortality rate dramatically decreased to 13% in patients who received treatment. The five late deaths, occurring 1–3 days after the injury, again, underscore the importance of *awareness*, which could have enabled an immediate diagnosis and action. Five late deaths, theoretically, could have been avoided if any imaging had been done in time.

The present review showed that persistent hypotension without an identifiable cause was the only consistent early clinical symptom and occurred intraoperatively in two patients [8, 25]. Both were saved by intraoperative clinical suspicion only, prompt intervention. Hence, *awareness* about the possibility of ICT in any case with persistent hypotension/tachycardia, shortness of breath, chest pain or any hemodynamic instability following the surgical application of graft fixators or stitches to the diaphragm around the hiatal region must be considered vital.

Treatment required a drainage procedure in 95.6%. In contrast to preliminary suggestions [6, 22], OD was inevitable in 78.3% of the patients and was not an absolute necessity for survival. The 0% mortality in 20 patients surviving the third day after trauma, 100% survival with lesser therapies and two-fold less vascular injuries in survivors suggest that a silent clinical course, although rare, is also possible. No mortality is expected in this group. This is not surprising as all injuries are associated with different levels of damage, depending on the depth of myocardial penetration or vascular involvement (Table 2). Therefore, management must certainly be individualized. Once the ICT is confirmed and the patient is stable, the team must be ready for open evacuation while quickly preparing for a PC. The literature does not support the validity of expectant management [2] or coil embolization [21] as the reports were anecdotal experiences. In any unstable patient diagnosed with ICT, an urgent OD will be lifesaving.

In conclusion, the review identified 10 reported mortalities among 30 published ICT cases. Given the fact that 11 more deaths were shown to go unreported, the actual mortality is higher and unknown. Decreasing hernia recurrence by employing mesh augmentation when dealing with defects around the ante-hiatal region warrants reconsideration and this is especially true for LARS. For ventral and extreme diaphragmatic hernias in which, without mesh augmentation, a repair is impossible, only meticulous stitching, instead of any fixators must be used. The development of better products to achieve durable fixation without fixators is clearly needed. In any case with hypotension or hemodynamic instability during or following a perihial upper abdominal procedure, increased *awareness* about ICT and early action will be life-saving.

## Declarations

### Author contribution statement

All authors listed have significantly contributed to the development and the writing of this article.

### Funding statement

This research did not receive any specific grant from funding agencies in the public, commercial, or not-for-profit sectors.

### Competing interest statement

The authors declare no conflict of interest.

### Additional information

No additional information is available for this paper.

### Acknowledgements

The authors thank Ms. Dicle Ekinci for her linguistic help and Sadettin Karacagil M.D., Ph.D. for reviewing the manuscript.

### References

- [1] S. Heuts, W.N.K.A. van Mook, E.J. Belgers, R. Lorusso, Iatrogenic cardiac tamponade after laparoscopic hiatal hernia repair requiring emergency sternotomy, *Eur. J. Cardiothorac. Surg.* 18 (2018).
- [2] M.A. Yerdel, O. Şen, U. Zor, et al., Cardiac tamponade as a life threatening complication of laparoscopic antireflux surgery: the real incidence and 3D anatomy of a heart injury by helical tacks, *J. Laparoendosc. Adv. Surg. Tech.* 28 (2018) 1041–1046.
- [3] F. Köckerling, C. Schug-Pass, R. Bittner, A word of caution: never use tacks for mesh fixation to the diaphragm!, *Surg. Endosc.* 32 (2018) 3295–3302.
- [4] S. Stockhausen, G. Kernbach-Wightton, B. Madea, E. Doberentz, Rare causes of iatrogenic pericardial tamponade – 2 case reports, *Arch. Kriminol.* 239 (2017) 36–44.
- [5] X. Lou, J.C. Vasquez, M.L. Mispireta, J. Delarosa, Cardiac tamponade from coronary artery injury after laparoscopic anti-reflux surgery, *Am. Surg.* 83 (2017) e23–e25.

- [6] A.J. Borrie, Cardiac tamponade: a rare complication of Nissen fundoplication, *ANZ J. Surg.* 88 (2018) e745–e746.
- [7] M.C. Fernandez, M. Diaz, F. Lopez, et al., Cardiac complications after laparoscopic large hiatal hernia repair. Is it related with staple fixation of the mesh? Report of three cases, *Ann Med Surg* 4 (2015) 395–398.
- [8] M. Koeppen, G.P. Gravlee, F. Nasrallah, T. Eckle, Transesophageal echocardiography in the diagnosis of acute pericardial tamponade during hiatal hernia repair, *J. Cardiothorac. Vasc. Anesth.* 28 (2014) 112–114.
- [9] C.T. Frantzides, S.N. Welle, Cardiac tamponade as a life threatening complication in hernia repair, *Surgery* 152 (2012) 133–135.
- [10] W. Makarewicz, Jaworski Ł, M. Bobowicz, et al., Paraesophageal hernia repair followed by cardiac tamponade caused by ProTacks, *Ann. Thorac. Surg.* 94 (2012) e87–e89.
- [11] H. Sugumar, L.G. Kearney, P.M. Srivastava, Pericardial tamponade: a life threatening complication of laparoscopic gastroesophageal surgery, *Heart Lung Circ.* 21 (2012) 237–239.
- [12] Y.E. Paz, J. Vazquez, M. Bessler, Cardiac tamponade as a complication of laparoscopic hiatal hernia repair: case report and literature review, *Cathet. Cardiovasc. Interv.* 78 (2011) 819–821.
- [13] B.P. Müller-Stich, G. Linke, B. Leemann, et al., Cardiac tamponade as a life-threatening complication in antireflux surgery, *Am. J. Surg.* 191 (2006) 139–141.
- [14] K. Thijssens, C. Hoff, J. Meyerink, Tackers on the diaphragm, *Lancet* 360 (2002) 1586.
- [15] E. Kemppainen, T. Kiviluoto, Fatal cardiac tamponade after emergency tension-free repair of a large paraesophageal hernia, *Surg. Endosc.* 14 (2000) 593.
- [16] M. Endlich, W. Schiller, F. Mellert, C. Probst, Implantation of a total abdominal mesh plastic ending up in multiple, lethal right heart injuries, *Interact. Cardiovasc. Thorac. Surg.* 21 (2015) 135–136.
- [17] M.L. Malmstrom, O. Thorlacius-Ussing, Cardiac tamponade as a rare complication in laparoscopic incisional hernia repair, *Hernia* 14 (2010) 421–422.
- [18] J.M. McClellan, D. Nelson, M. Martin, Hemopericardium after laparoscopic perihial procedures: high index of suspicion facilitates early diagnosis and

- successful nonoperative management, *Surg. Obes. Relat. Dis.* 12 (2016) e27–e31.
- [19] J.B. Jørgensen, P.E. Lundbeck, P. Rask, L. Jensen, Cardiac tamponade after laparoscopic operation for a traumatic, *Ugeskr Laeger* 176 (25A) (2014) pii: V12120728.
- [20] G. Dapri, J. Himpens, B. Hainaux, et al., Surgical technique and complications during laparoscopic repair of diaphragmatic hernias, *Hernia* 11 (2007) 179–183.
- [21] A.J. Cockbain, A. Darmalingum, S.P. Mehta, Acute deterioration after emergency paraesophageal hernia repair, *Surgery* 159 (2016) 1691–1692.
- [22] R. Hemetsberger, N. Schulze-Waltrup, H. Heuer, Percutaneous coil embolization of a perforated side branch of the right coronary artery causing a pericardial tamponade 3 weeks after abdominal surgery, *Clin. Res. Cardiol.* 103 (2014) 581–583.
- [23] M.R. Puchakayala, K. Abbey, J. Haft, M.B. Orringer, Delayed pericardial tamponade following transthoracic hiatal hernia repair, *J. Cardiothorac. Vasc. Anesth.* 20 (2006) 245–246.
- [24] V.F. Trastek, C. Deschamps, M.S. Allen, et al., Uncut Collis-Nissen fundoplication: learning curve and long-term results, *Ann. Thorac. Surg.* 66 (1998) 1739–1744.
- [25] E. Firoozmand, M. Ritter, R. Cohen, J. Peters, Ventricular laceration and cardiac tamponade during laparoscopic Nissen fundoplication, *Surg. Laparosc. Endosc.* 6 (1996) 394–397.
- [26] E. Neri, G. Lisi, L. Marchetti, C. Sassi, Iatrogenic right ventricular laceration. Delayed presentation after abdominal surgery, *Tex. Heart Inst. J.* 27 (2000) 302–303.
- [27] K. Tekin, T. Toydemir, M.A. Yerdel, Is laparoscopic antireflux surgery safe and effective in obese patients? *Surg. Endosc.* 26 (2012) 86–95.
- [28] T. Toydemir, G. Çipe, O. Karatepe, M.A. Yerdel, Laparoscopic management of totally intra-thoracic stomach with chronic volvulus, *World J. Gastroenterol.* 21 (2013) 5848–5854.
- [29] J. Farlo, D. Thawgathurai, M. Mikhail, et al., Cardiac tamponade during laparoscopic Nissen fundoplication, *Eur J Anesth* 15 (1998) 246–247.
- [30] R.P. Onders, H. Aiyar, J.T. Mortimer, Characterization of the human diaphragm muscle with respect to the phrenic nerve motor points for diaphragmatic pacing, *Am. Surg.* 70 (2004) 241–247.



- [31] ProTack AutoSuture Single Use Instrument (Package Insert). Norwalk, CT, US, Covidien, 2004.
- [32] Hazard report. Patient injury or death could result from improper use of U.S. Surgical Helical Tacks, *Health Dev.* 33 (2004) 293–295.
- [33] ProTack AutoSuture Single Use Instrument (Package Insert). Mansfield, MA, US, Covidien, 2011.
- [34] C.T. Frantzides, A.K. Madan, M.A. Carlson, G.P. Stavropoulos, A prospective, randomized trial of laparoscopic polytetrafluoroethylene (PTFE) patch repair vs simple cruroplasty for large hiatal hernia, *Arch. Surg.* 137 (2002) 649–652.
- [35] B.K. Oelschlager, C.A. Pellegrini, J. Hunter, Biologic prosthesis reduces recurrence after laparoscopic paraesophageal hernia repair: a multicenter, prospective, randomized trial, *Arch. Surg.* 244 (2006) 481–490.
- [36] F.A. Granderath, U.M. Schweiger, T. Kamolz, et al., Laparoscopic Nissen fundoplication with prosthetic hiatal closure reduces postoperative intra-thoracic wrap herniation: preliminary results of a prospective randomized functional and clinical study, *Arch. Surg.* 140 (2005) 40–48.
- [37] D.I. Watson, S.K. Thompson, P.G. Devitt, et al., Laparoscopic repair of very large hiatal hernia with sutures versus nonabsorbable mesh: a randomized controlled trial, *Ann. Surg.* 261 (2015) 282–289.
- [38] C.T. Frantzides, M.A. Carlson, S. Loizides, et al., Hiatal hernia repair with mesh: a survey of SAGES members, *Surg. Endosc.* 24 (2010) 1017–1024.