IJC Heart & Vasculature 24 (2019) 100413

Contents lists available at ScienceDirect

IJC Heart & Vasculature

journal homepage: http://www.journals.elsevier.com/ijc-heart-and-vasculature

Conventional echocardiographic parameters or three-dimensional echocardiography to evaluate right ventricular function in percutaneous edge-to-edge mitral valve repair (PMVR)

Reinhard J. Sauter [a,b,1,2], Johannes Patzelt [a,b,1,2], Matthias Mezger [a,b], Henry Nording [a,b], Jan-Christian Reil [a,b], Mohammed Saad [a,b], Peter Seizer [c], Juergen Schreieck [c], Peter Rosenberger [d], Harald F. Langer [a,b,*,3], Harry Magunia [d,3]

[a] University Hospital, Department of Cardiology, University Heart Center Luebeck, 23538 Luebeck, Germany
[b] German Center for Cardiovascular Research (DZHK), Partner Site Hamburg/Kiel/Luebeck, 23538 Luebeck, Germany
[c] University Hospital, Department of Cardiology and Cardiovascular Medicine, Eberhard Karls University Tuebingen, 72076 Tuebingen, Germany
[d] University Hospital, Department of Anaesthesiology and Intensive Care Medicine, Eberhard Karls University Tuebingen, 72076 Tuebingen, Germany

ARTICLE INFO

Article history:
Received 25 May 2019
Received in revised form 10 August 2019
Accepted 14 August 2019
Available online 30 August 2019

Keywords:
Mitral regurgitation
Percutaneous mitral valve repair
Echocardiography
3D-echocardiography
RV function
Outcome

ABSTRACT

Introduction: In this study, we evaluated right ventricular (RV) function before and after percutaneous mitral valve repair (PMVR) using conventional echocardiographic parameters and novel 3DE data sets acquired prior to and directly after the procedure.
Patients and methods: Observational study on 45 patients undergoing PMVR at an university hospital.
Results: In the overall collective, the 3D RV-EF before and after PMVR showed no significant change ($p = 0.16$). While there was a significant increase of the fractional area change (FAC, from 23 [19–29] % to 28 [24–33] %, $p = 0.001$), no significant change of the tricuspid annular plane systolic excursion (TAPSE, from 17 ± 6 mm to 18 ± 5 mm (standard deviation), $p = 0.33$) was observed. Regarding patients with a reduced RV-EF (< 35%), a significant RV-EF improvement was observed (from 27 [23–34] % to 32.5 [30–39] % ($p = 0.001$). 71.4% of patients had an improved clinical outcome (improvement in 6-minute walk test and/or improvement in NYHA class of more than one grade), whereas clinical outcome did not improve in 28.6% of patients. Using univariate logistic regression analysis, the post-PMVR RV-EF (OR 1.15: 95% CI 1.02–1.29; $p = 0.02$) and the change in RV-EF (OR 1.13: 95% CI 1.02–1.25; $p = 0.02$) were significant predictors for improved clinical outcome at 6 months follow up.
Conclusion: Thus, RV function may be an important non-invasive parameter to add to the predictive parameters indicating a potential clinical benefit from treatment of severe mitral regurgitation using PMVR.
Published by Elsevier B.V. This is an open access article under the CC BY-NC-ND license (http://creativecommons.org/licenses/by-nc-nd/4.0/).

1. Introduction

The effects of percutaneous mitral valve repair (PMVR) on right heart function and geometry, however, are currently not well characterized. As RV dysfunction is associated with increased morbidity and mortality in various diseases [1–3], the influence of PMVR on the function of the right heart is of great clinical interest. While long-term effects of PMVR have been previously studied [4], little is known about immediate post interventional changes in RV function.

From patient collectives undergoing surgical repair of MR, it is known that two-dimensional (2D) indexes of RV systolic performance decrease during and immediately after cardiac surgery [5]. Moreover, recovery to basal values is often incomplete and an echocardiographic dysfunction can persist even at one year after surgery [5]. Depression of RV function is also reported for other settings of cardiac surgery like coronary artery bypass grafting [6], and worsening of RV function and the magnitude of deterioration have important prognostic implications

Abbreviations: 3DE, 3D-echocardiography; ACE, angiotensin converting enzyme; DMR, degenerative mitral regurgitation; EDV, end-diastolic volume; EF, ejection fraction; ESV, end-systolic volume; FAC, fractional area change; FMR, functional mitral regurgitation; LA, left atrium; LV, left ventricle; LVOT, left ventricular outflow tract; MR, mitral regurgitation; MRI, magnetic resonance imaging; NYHA, New York heart association functional classification; PAMP, pulmonary artery mean pressure; PASP, pulmonary artery systolic pressure; PCWP, pulmonary capillary wedge pressure; PMVR, percutaneous mitral valve repair; RV, right ventricle; TAPSE, tricuspid annular plane systolic excursion; TAVR, transcatheter aortic valve replacement; TEE, transesophageal echocardiography; TTE, transthoracic echocardiography.

* Corresponding author at: Department of Cardiology and Cardiovascular Medicine, University Clinic Luebeck, Ratzeburger Allee 160, 23538 Luebeck, Germany.
E-mail address: harald.langer@uksh.de (H.F. Langer).
[1] Share first authorship.
[2] RV function in PMVR using 3D-echocardiography
[3] Share senior authorship.

https://doi.org/10.1016/j.ijcha.2019.100413
2352-9067/Published by Elsevier B.V. This is an open access article under the CC BY-NC-ND license (http://creativecommons.org/licenses/by-nc-nd/4.0/).

for interventions such as transcatheter aortic valve replacement (TAVR) [7]. A decreased pre-procedural RV function, thus, may be particularly detrimental given the significant hemodynamic changes caused by cardiovascular interventions [8].

Before recent developments in 3D echocardiographic techniques were introduced, the complex shaped RV used to be evaluated by surrogate parameters derived from 2D echocardiography such as fractional area change (FAC), tricuspid annular plane systolic excursion (TAPSE) or tissue Doppler based techniques (tissue Doppler derived systolic excursion of the lateral tricuspid annulus) [9]. Calculation of RV ejection fraction (EF) and estimation of RV volumes was often carried out using cardiac magnetic resonance imaging (MRI) [10]. Nowadays, modern 3D echocardiography-based techniques offer a well validated approach to study the entire RV, especially concerning the determination of RV volumes and RV-EF [11–13]. In other interventional settings such as trans-catheter aortic valve repair (TAVR), it was already demonstrated that RV parameters provide valuable information [7].

So far, little is known about immediate RV geometry and RV function changes caused by the PMVR procedure, although identification of patients, whose RV function will improve after clip deployment, is of utmost clinical interest. Furthermore, only little reliable information is available on how pre-interventional RV impairment affects the clinical outcome of patients undergoing PMVR.

Thus, this study sought to determine the early changes of RV volumes and EF after PMVR and their prognostic value for mid-term outcomes.

2. Material and methods

2.1. Study population

We included 45 patients with severe MR, who underwent PMVR using the MitraClip® system (Abbott Vascular) at the University hospital, Department of Cardiology and Cardiovascular Medicine, University of Tuebingen between July 2015 and April 2016. We assessed invasive hemodynamics and echocardiographic parameters to validate success of the PMVR procedure. For instance, we measured hemodynamic parameters using a Swan Ganz catheter as well as TTE and TEE before and after clip deployment. The study was approved by the local ethics committee (260/2015R) and patients gave informed consent. An interdisciplinary team of interventional cardiologists, cardiac anesthesiologists and cardiac surgeons made the decision for treatment by PMVR based on either the EuroSCORE II [14] or on the presence of specific surgical risk factors not covered in the EuroSCORE II; exclusion criteria for PMVR were as previously described [15]. The patients underwent TEE, TTE and clinical assessment before the intervention to document MR severity, mitral valve morphology and NYHA functional class. Heart failure patients had to be on optimal medical treatment according to current guidelines for at least 3 months prior to PMVR treatment [16].

2.2. Echocardiographic assessment

Echocardiographic assessment was carried out at the beginning and at the end of the procedure to acquire hemodynamic and geometric data using a Philips CX50 machine (X7-2t TEE probe, Philips HealthCare, Hamburg, Germany). Both TTE and TEE were carried out and RV focused 3D datasets were obtained by an experienced echocardiographer. During acquisition, datasets were optimized to obtain clear endocardial borders and high frame rates (12–20 Hz). All datasets were stored digitally. Quantification of RV volumes and function was performed offline using a vendor independent RV function package (4D RV Function 2.0, TomTec Imaging Systems, Unterschleissheim, Germany) by an echocardiographer trained on this software, who was blinded to the PMVR results. End-diastolic volume (EDV), end-systolic volume (ESV) and EF of the RV were calculated. This analysis takes about 5 min per patient on average. MR and reduction of MR were evaluated using TEE at the beginning and at the end of the PMVR procedure. The RV FAC, the PASP and the tricuspid plane systolic excursion (TAPSE) were assessed based on current clinical guidelines [17]. We performed 3D TEE datasets from 57 patients. Because the data quality of 12 patients before and/or after the procedure was not sufficient, we had to exclude those 12 patients. In our residual collective of 45 patients, we received usable echocardiographic PASP-measurements in 29 patients, while the PASP was not derivable in 16 patients. Classification of MR and MR severity at baseline were analyzed according to the current European Association of Echocardiography guidelines [18]. To evaluate the severity of MR post-intervention we used the technique described by Foster et al. [19]. Reduced RV function was defined as an EF below 35% [3].

2.3. Hemodynamic measurements

Hemodynamic measurements were carried out as described previously [20]. Pressure transponders were calibrated to atmospheric pressure at right atrial height. Arterial blood pressure and arterial blood gas sampling were obtained via cannulation of the radial artery. A Swan-Ganz catheter (7F, Edwards Lifesciences, Irvine, USA) was introduced and pulmonary capillary wedge pressure (PCWP) and pulmonary artery pressure (PAP) curves were obtained before and after MitraClip® deployment as well as PA blood samples. Wedge position was confirmed via fluoroscopy and pulmonary capillary blood sampling in comparison to arterial blood sampling was performed.

2.4. PMVR procedure

PMVR was performed either in general anesthesia (GA) or in deep sedation (DS) [20]. Briefly, the MitraClip® device was advanced via the trans-septal route into the left ventricle. After retraction of the device towards the mitral valve plane with the two clip arms extended and careful positioning under fluoroscopic as well as transesophageal two- and three-dimensional echocardiographic guidance, both the anterior and the posterior leaflets were captured. The clip was subsequently closed to coapt the mitral leaflets thereby emulating the surgical double-orifice technique introduced by Alfieri et al. [21] After clip deployment, PCW and PA pressure curves, blood samples and final TEE and TTE measurements were obtained a second time.

2.5. Definition of the improvement of clinical outcome

The improvement of clinical outcome 6 months after PMVR was defined as follows:

- improvement in 6-minute walk test and/or
- improvement in NYHA class of more than one grade, if the walk test was not performed.

2.6. Statistical analysis

We carried out statistical analysis with SPSS (version 24, IBM Deutschland GmbH, Ehningen, Germany) and SAS JMP software (ver. 14.0.0, SAS Institute Inc., Cary, USA). Categorical variables are depicted as absolute numbers or percentages, continuous variables as means ± standard deviation (SD) or median and interquartile ranges (IQR). Normal distribution of variables was checked with the Shapiro-Wilk test. To compare means, the paired *t*-test for was used for normally distributed data. For not normally distributed data, the Wilcoxon signed-rank test was used to compare means. Intergroup comparisons were performed by ANOVA analysis. Matched pairs analyses were carried out to compare baseline to post-PMVR values. Odds ratios were calculated using a univariate logistic regression analysis. The 2-tailed p values were calculated and a value of $p \leq 0.05$ was considered statistically significant.

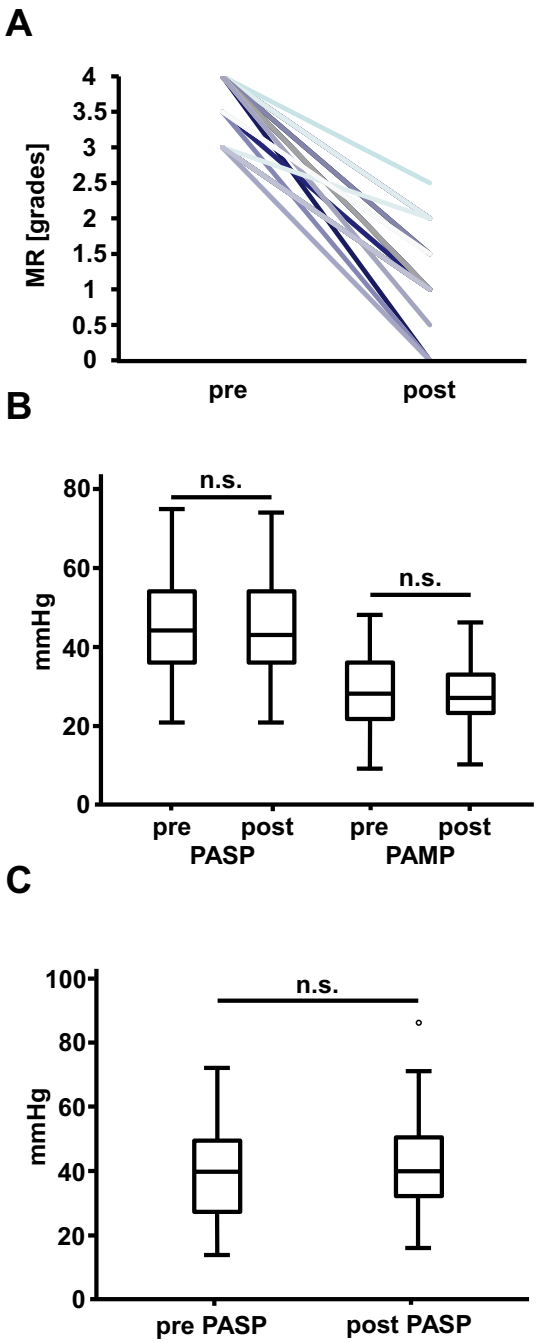

Fig. 1. Effects of percutaneous mitral valve repair (PMVR) on right ventricular pressure parameters in 45 patients with MR not accessible by conventional surgery. (A) Grade of MR pre and post PMVR. (B) PASP and PAMP measured in right heart catheterization before and after PMVR show no significant change before and after PMVR. n.s. = no significant change compared to pre intervention. (C) Echocardiographic PASP before and after PMVR showing no significant change. n.s. = no significant change compared to pre intervention.

3. Results

In this study, we evaluated hemodynamics in 45 patients undergoing PMVR using echocardiographic and invasive parameters. Baseline characteristics for all patients are depicted in Table 1, medical therapy at 6 months after PMVR in Supplemental Table 1. Functional NYHA class III-IV was present in the majority of patients, and there was a high percentage (51.1%) of patients with severely reduced LV-function (≤ 35% EF). Functional MR (FMR) was present in 51.1% of patients, 20.0% had mixed genesis of MR. Coronary artery disease was previously diagnosed in 68.9% of the patients, 62.5% had atrial fibrillation and 35.6% renal insufficiency. Reduction of MR severity to ≤2 post intervention was achieved in 44 (97.8%) patients, 1 patient had a residual MR of 2–3 and no patient had a residual MR ≥ 3 (Fig. 1A). The same proportion of patients achieved a MR severity ≤2 in DMR and FMR.

3.1. PMVR does not influence PASP and PAMP significantly

After the PMVR procedure, we observed no significant change in systolic pulmonary artery pressure (PASP) or the mean pulmonary artery pressure (PAMP). The measurements were carried out both invasively (Fig. 1B) and by echocardiography (Fig. 1C).

3.2. No significant change in RV function is observed after PMVR

Prior to PMVR, we assessed RV function by echocardiography using different established methods. Fig. 2A illustrates the method depicting a 3D model of the RV in diastole and systole, Supplemental movie 1 shows an RV contraction sequence. The received 3D data of the RV at baseline and after PMVR of all 45 patients showed no significant change in RV-EF (from 35 [26–40, interquartile range] % to 35 [30–43] %, Fig. 2B; $p = 0.16$). Likewise, the FAC of the RV showed a small but not statistically significant increase of RV function (Fig. 2C). There was no significant change when comparing the TAPSE pre and post PMVR (Fig. 2D).

Table 1
Baseline patient characteristics. n = 45.

Age [mean, min to max]	75.2 (38 to 90)
Male gender	20 (44.4%)
Coronary heart disease	31 (68.9%)
Atrial fibrillation	28 (62.5%)
Hypertension	34 (75.6%)
Smoker	10 (22.2%)
Hyperlipoproteinemia	24 (53.3%)
Diabetes	10 (22.2%)
NYHA-class – no. (%)	
I	0 (0%)
II	2 (4.4%)
III	27 (60.0%)
IV	16 (35.6%)
6-minute walktest [m]	139 ± 241
Renal insufficiency[a]	16 (35.6%)
Pulmonary hypertension[a]	32 (71.1%)
Euroscore II	11.7 (2 to 57)
MR Vena contracta	6.1 ± 1.6
Etiology of MR	
Functional	23 (51.1%)
Degenerative	13 (28.9%)
Mixed	9 (20.0%)
Medication	
Betablockers	39 (86.7%)
Aldosterone antagonists	22 (48.9%)
ACE inhibitors/sartans	39 (86.7%)
Diuretics	42 (93.3%)
Digitalis	3 (6.7%)
Calcium antagonists	6 (13.3%)
Anticoagulation	27 (60.0%)
LVEF	
≤ 35%	23 (51.1%)
36–50%	8 (17.8%)
> 50%	14 (31.1%)
Right ventricle	
RVEDVI (ml/m^2)	78.7 ± 33.5
EF (%)	33.9 ± 8.3
FAC (%)	28.0 ± 7.2
TAPSE (mm)	18 ± 7

NYHA: New York Heart Association functional classification; MR: mitral regurgitation; ACE: angiotensin converting enzyme; LV: left ventricle; EF: ejection fraction; RVEDVI: right ventricular end-diastolic volume indexed to body surface area; FAC: fractional area change; TAPSE: tricuspid annular plane systolic excursion; Lines with ± include mean/standard deviation.

[a] Definitions as used for EuroScore II.

As confirmation for valid measurements, we could document a significant correlation of the TAPSE acquired by 2D TTE and the RV-EF acquired by 3D-TEE (Suppl. Fig. 1). In line with this finding, we found also a strong correlation between FAC and 3D-RV-EF (Fig. 2E). Interestingly, the groups of LV-EF >50%, 35–50% and lower than 35% do not differ significantly in their RV-EF (n = 45, p = 0.19, 1-way ANOVA, Suppl. Fig. 2). In addition, no significant correlation was observed between the cumulative catecholamine dose and the increase in RV function (Suppl. Fig. 3A). Also, the choice of anesthesia had no significant effect (Suppl. Fig. 4).

3.3. In patients with reduced RV-EF < 35%, RV-EF increases after PMVR

When analyzing the subgroup of patients (n = 21) with reduced RV-EF < 35%, we observed a significant increase of RV-EF from median 27 [IQR 23 to 34] % to median 32.5 [IQR 30 to 39] % (p = 0.001) (Fig. 3A).

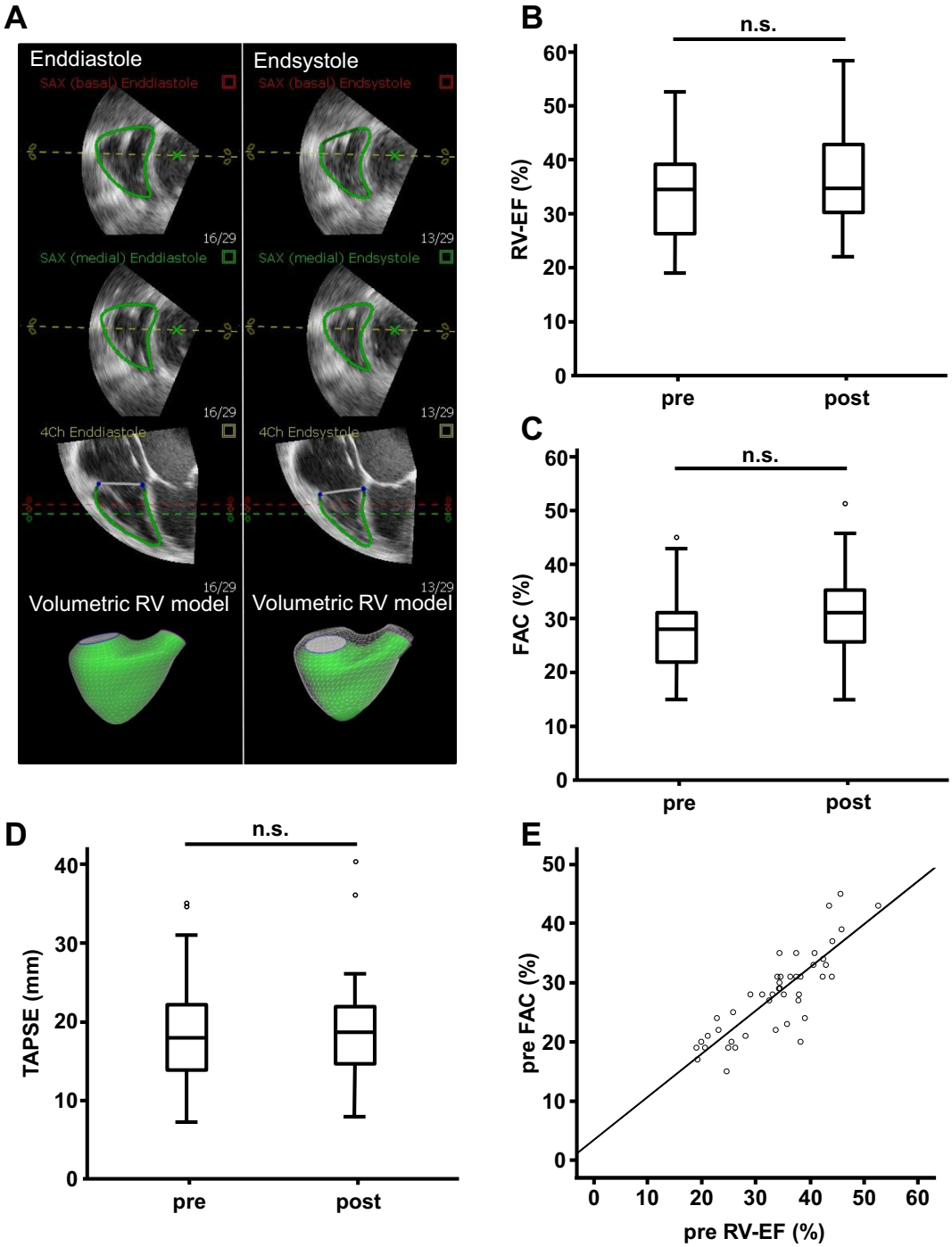

Fig. 2. No significant changes of well-established parameters for RV-Function in the total collective of 45 patients after PMVR. (A) Reconstruction of a right ventricular mesh model using the Tomtec 4D RV function 2.0 software using a focused view of the right ventricle. Left side shows enddiastolic frames, right side shows endsystolic frame. Speckle-tracking-based endocardial border detection of the RV endocardium with a basal and middle short axis view of the RV and a 4-chamber view as well as mesh model of these frames is shown. (B) 3D echocardiographic ejection fraction of the right ventricle (RV-EF) before and after PMVR showing no significant change (n = 45, p = 0.16). (C) Right ventricular fractional area change (FAC) showing no significant change (n = 45, p = 0.13). (D) Tricuspid annular plane systolic excursion (TAPSE) showing no significant change (n = 45, p = 0.96). (E) Correlation between the 3D-RVEF and the FAC before the procedure. According to the Pearson correlation test there is a positive correlation (n = 45, p < 0.001).

Similar to the overall collective, PMVR had no significant influence on the PASP in this subgroup (Supplemental Table 2; Fig. 3B). While there was a significant increase of the FAC (from median 23 [IQR 19 to 29] % to median 28 [IQR 24 to 33] %, p = 0.001, Fig. 3C), no significant change was observed regarding the TAPSE (from 17 ± 6 mm to 18 ± 5 mm, p = 0.33, Fig. 3D). In line with the finding, that RV-EF increases after PMVR significantly in patients with reduced RV-EF<35%, the pulmonary effective arterial elastance Ea decreased after PMVR (n = 22, p = 0.006, Suppl. Fig. 5). No significant correlation between the administered catecholamines and the increase of the RV function could be observed in this subgroup (Suppl. Fig. 3B).

3.4. Predictive value of early RV function change for improvement in clinical outcome 6 months after PMVR

Data on mortality after 6 months were available for all patients. In the studied patient collective, 37 patients (82.2%) were still alive (of which 56.8% patients had reduced RV-EF below 35% and 43.2% patients a RV-EF above 35%). Data on the indicators for improvement in clinical outcome were available in 35 patients. While data pairs for NYHA-class and 6-minute walktest were available in 33 patients, 35 patients could be used for evaluation due to incongruence. 25 patients (71.4%) had an improved clinical outcome, whereas clinical outcome did not improve in 10 patients (28.6%).

In univariate logistic regression analysis, the post-PMVR RV-EF (OR 1.15; 95% CI 1.02–1.23; p = 0.02) and the change in RV-EF (OR 1.13; 95% CI 1.02–1.25; p = 0.02) were significant predictors for improved clinical outcome at 6 months (Fig. 4 and Supplemental Table 3).

3.5. Observer reliability

To assess inter- and intrarater reliability of the 3D analyses, 10 randomly selected datasets were analyzed by the initial investigator and a second investigator blinded to the first results and intraclass correlation coefficients (ICC) between the measurements were calculated. 95% confidence intervals (95% CI) are reported. For the RVEDV, RVESV and the RVEF the estimated interrater reliability was 0.991 (95% CI 0.964 to 0.998), 0.989 (95% CI 0.956 to 0.997) and 0.956 (95% CI 0.833 to 0.989) and the estimated intrarater reliability was 0.997 (95% CI 0.989 to 0.999), 0.997 (95% CI 0.990 to 0.999) and 0.987 (95% CI 0.953 to 0.997), respectively.

4. Discussion

Pre-existent low RV-EF has been identified as a major predictor for the occurrence of postoperative low cardiac output in interventional or surgical disciplines for example in patients undergoing cardiac surgery [8]. Consequently, impaired RV-function may have a significant impact on long-term clinical outcome in patients after surgical or interventional treatment of severe MR.

In this cohort of patients undergoing PMVR and 3DE, we found that RV-function and PASP did not improve after PMVR. Second, 3D-RV function improved in the subgroup with reduced RV-function (at baseline),

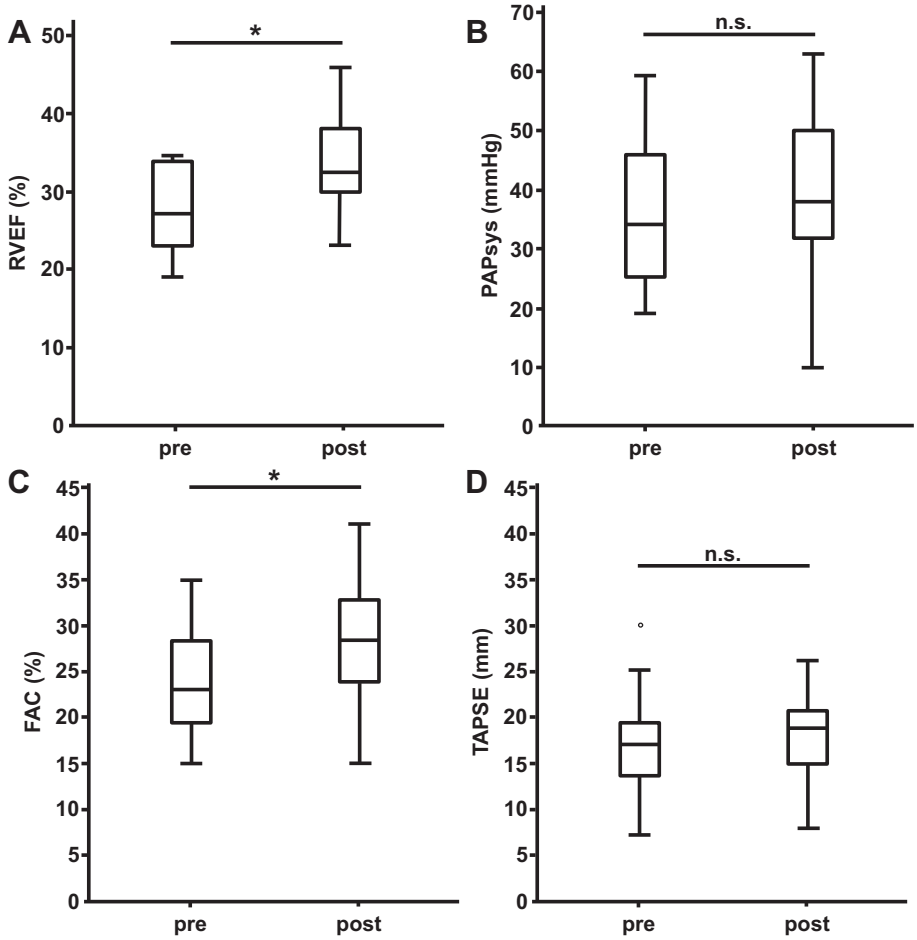

Fig. 3. In patients with reduced RV-EF < 35%, RV-EF increases after PMVR. (A) In patients with reduced right ventricular ejection fraction (RV-EF < 35%) before PMVR, RV-EF increases significantly after PMVR (n = 24, p = 0.001). (B) Echocardiographic PASP before and after PMVR showing no significant change. (n.s. = no significant difference was observed). (C) FAC before and after PMVR is depicted. We observed a significant increase of FAC after PMVR. (n = 24; p = 0.01). (D) TAPSE before and after PMVR showing no significant change. (n = 24, p = 0.33).

which was associated with improved echocardiographic parameters (3D-echocardiographic RV-EF and RV-FAC). Third, post-PMVR RV-EF and the change in RV-EF are predictors for improved clinical outcome at 6 months after the procedure.

There are contradictions in the reports published so far on the influence of the PMVR procedure on right heart function. While in one study 2D echocardiography derived surrogate parameters of RV function such as TAPSE improved after the PMVR procedure [22], another study showed that RV function did not change over time [23]. It is known that TAPSE reflects the baso-apical movement of the tricuspid valve annulus towards the right ventricular apex only. This may be the reason, why TAPSE and FAC do not always match with the correct RV function, especially in patients with an impaired RV-EF [24]. A more recent study using 3D transthoracic echocardiography based techniques showed that RV function improves over time after PMVR due to reverse remodeling [4]. This observation is in line with our findings, and moreover, we found an improved RV-EF immediately after the PMVR procedure in patients with reduced RV-EF at baseline. It has been shown previously that echocardiography-derived 2D parameters like TAPSE and tissue Doppler derived peak systolic velocity of the lateral tricuspid annulus can identify patients with an increased risk of cardiovascular mortality despite a successful PMVR procedure [25–28]. In our rather small patient collective, 12.5% of the patients with reduced RV-EF below 35% have died, whereas in the group of patients with RV-EF above 35%, 23.81% had died within 6 months after the PMVR procedure. This difference was not statistically significant (chi-square = 1.15, p = 0.28).

A recent study has shown, that 1-year outcomes concerning all-cause mortality and hospitalization for heart failure are equal in patients either treated by medical therapy alone or in combination with a PMVR procedure [29]. In that study, 36.8% of patients in the treatment group and 28.9% in the control group were classified as having a NYHA class II heart insufficiency, the median EuroScore II was 6.6% (treatment group) and 5.9% (control group). In contrast, the recently published COAPT trial showed superiority of PMVR over medical therapy concerning the same endpoints [30]. Unfortunately, both studies are lacking profound data on pre-interventional RV function. Our study included patients with a median EuroScore II of 11.7% and only 4.4% of our patients had NYHA class II heart insufficiency thus representing more seriously ill patients. In our patient collective, there was a significant improvement in the 6-minute walk test and the NYHA class six months after the PMVR procedure. Patients presenting with reduced RV-EF below 35% at baseline experienced a significant increase in RV-EF, independent of the periprocedural administered catecholamine dose and independent of the chosen form of anesthesia (deep sedation vs. general anesthesia). Furthermore, we found that the post-PMVR RV-EF and the change in RV-EF are reliable predictors for 6 months clinical outcome.

In contrast to the findings of our study, a previous analysis revealed a decreased PASP after PMVR [20]. The PASP, that was determined in our study, was reduced in absolute numbers but the difference did not reach significance. The current literature is inconclusive regarding PASP changes after PMVR. Previously, it was observed that the mean PASP decreased after PMVR [31], while another study could document no significant change of systolic and mean PA pressure after successful PMVR [32]. These at first view contradictory results demand further and larger studies to finally determine the impact of PMVR on functional parameters at least partially reflecting RV function such as the PASP as well as the predictive value of RV parameters. A profound impact on PMVR long-term outcome is already known for the parameters age and LV-function but RV function might improve the understanding of the different outcomes [33].

4.1. Limitations

Although determination of 3D-RV function will extend our diagnostic tools to monitor hemodynamics and to identify patients at risk for adverse events during or after PMVR, disadvantages of the method have to be considered as well. First of all, we have to acknowledge the

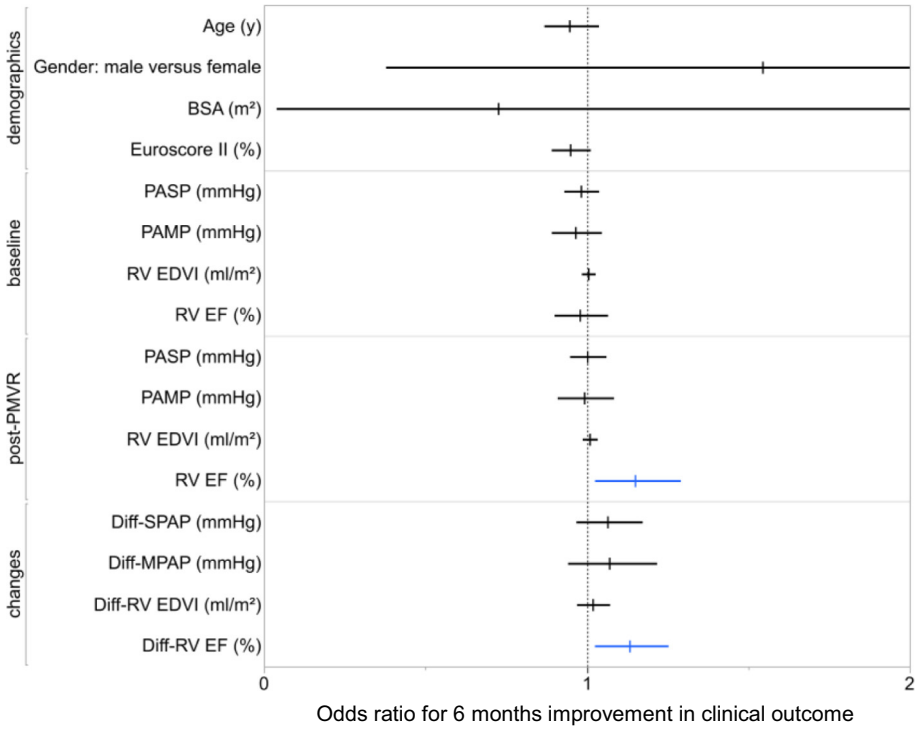

Fig. 4. Predictive value of early RV function change for improvement in clinical outcome 6 months after PMVR. Forrest plot showing the summary measure of the odds ratios (center line) and the 95% confidence intervals (horizontal line) given for improvement in clinical outcome 6 months after PMVR (all patients). The dotted line shows the border of no association. The post-PMVR RV-EF (OR 1.15: 95% CI 1.02–1.29; p = 0.02) and the change in RV-EF (OR 1.15: 95% CI 1.02–1.29; p = 0.02) were significant predictors for improved clinical outcome at 6 months follow up.

limited sample size of this study and the 3D-echocardiographic evaluation of RV function in the context of PMVR will have to be studied in larger trials. Another limitation for frequent use of 3D echocardiography in the daily routine may be that it is not broadly available to clinicians and 3D-derived RV functional assessment is still time-consuming and is not a quick bedside tool.

Considering the small sample size of this study, we waived the analysis of the genesis of impaired RV function. We cannot rule out that extracardiac diseases affecting RV function have influenced our data, because chronic lung disease e.g. was present in 13.3% of patients. Furthermore, peri-procedural settings such as the type of anesthesia and catecholamine doses (general anesthesia versus conscious sedation) [34] could influence RV Function. However, in our analysis, changes in RV function showed no difference between general anesthesia and conscious sedation. Further studies should evaluate, if established prognostic parameters correlate with 3D-RV function.

5. Conclusion

In conclusion, determination of 3D-RV function is a novel tool to improve our understanding of changes in hemodynamics during PMVR on a non-invasive basis. Importantly, future larger studies will have to scrutinize the prognostic value of RV function-based parameters to predict long-term procedure success of PMVR and the net clinical benefit for the critical patient collective undergoing this interventional procedure.

Supplementary data to this article can be found online at https://doi.org/10.1016/j.ijcha.2019.100413.

Funding sources

This study was supported by grants from the German Research Foundation (KFO 274, SFB TR240), the Volkswagen Foundation (Lichtenberg program) and the German Heart Foundation. This work was supported by a grant from the Deutsche Forschungsgemeinschaft (DFG): Grants DFG-INST 2388/71-1 FUGG.

Declaration of competing interest

Dr. H. F. Langer and Dr. P. Seizer were reimbursed for PMVR training courses by Abbott Vascular, otherwise we have no potential conflict of interest to declare.

References

[1] V. Melenovsky, S.J. Hwang, G. Lin, M.M. Redfield, B.A. Borlaug, Right heart dysfunction in heart failure with preserved ejection fraction, Eur. Heart J. 35 (2014) 3452–3462.
[2] H. Magunia, C. Dietrich, H.F. Langer, D. Schibilsky, C. Schlensak, P. Rosenberger, M. Nowak-Machen, 3d echocardiography derived right ventricular function is associated with right ventricular failure and mid-term survival after left ventricular assist device implantation, Int. J. Cardiol. 272 (2018) 348–355.
[3] Y. Nagata, V.C. Wu, Y. Kado, K. Otani, F.C. Lin, Y. Otsuji, K. Negishi, M. Takeuchi, Prognostic value of right ventricular ejection fraction assessed by transthoracic 3d echocardiography, Circ Cardiovasc Imaging 10 (2017).
[4] P. Gripari, G. Tamborini, V. Bottari, F. Maffessanti, M.C. Carminati, M. Muratori, C. Vignati, A.L. Bartorelli, F. Alamanni, M. Pepi, Three-dimensional transthoracic echocardiography in the comprehensive evaluation of right and left heart chamber remodeling following percutaneous mitral valve repair, Journal of the American Society of Echocardiography: Official Publication of the American Society of Echocardiography 29 (2016) 946–954.
[5] M. Zanobini, C. Loardi, P. Poggio, G. Tamborini, F. Veglia, A. Di Minno, V. Myasoedova, L.F. Mammana, R. Biondi, M. Pepi, F. Alamanni, M. Saccocci, The impact of pericardial approach and myocardial protection onto postoperative right ventricle function reduction, J. Cardiothorac. Surg. 13 (2018) 55.
[6] M. Alam, A. Hedman, R. Nordlander, B. Samad, Right ventricular function before and after an uncomplicated coronary artery bypass graft as assessed by pulsed wave doppler tissue imaging of the tricuspid annulus, Am. Heart J. 146 (2003) 520–526.
[7] P.C. Cremer, Y. Zhang, M. Alu, L.L. Rodriguez, B.R. Lindman, A. Zajarias, R.T. Hahn, S. Lerakis, S.C. Malaisrie, P.S. Douglas, P. Pibarot, L.G. Svensson, M.B. Leon, W.A. Jaber, The incidence and prognostic implications of worsening right ventricular function after surgical or transcatheter aortic valve replacement: insights from partner iia, Eur. Heart J. 39 (2018) 2659–2667.
[8] J. Ternacle, M. Berry, T. Cognet, M. Kloeckner, T. Damy, J.L. Monin, J.P. Couetil, J.L. Dubois-Rande, P. Gueret, P. Lim, Prognostic value of right ventricular two-dimensional global strain in patients referred for cardiac surgery, Journal of the American Society of Echocardiography: Official Publication of the American Society of Echocardiography 26 (2013) 721–726.
[9] L.G. Rudski, W.W. Lai, J. Afilalo, L. Hua, M.D. Handschumacher, K. Chandrasekaran, S.D. Solomon, E.K. Louie, N.B. Schiller, Guidelines for the echocardiographic assessment of the right heart in adults: a report from the American Society of Echocardiography endorsed by the European Association of Echocardiography, a registered branch of the European Society of Cardiology, and the Canadian Society of Echocardiography, Journal of the American Society of Echocardiography: Official Publication of the American Society of Echocardiography 23 (2010) 685–713 (quiz 786-688).
[10] M. Focardi, M. Cameli, S.F. Carbone, A. Massoni, R. De Vito, M. Lisi, S. Mondillo, Traditional and innovative echocardiographic parameters for the analysis of right ventricular performance in comparison with cardiac magnetic resonance, Eur. Heart J. Cardiovasc. Imaging 16 (2015) 47–52.
[11] J.B. Park, S.P. Lee, J.H. Lee, Y.E. Yoon, E.A. Park, H.K. Kim, W. Lee, Y.J. Kim, G.Y. Cho, D.W. Sohn, Quantification of right ventricular volume and function using single-beat three-dimensional echocardiography: a validation study with cardiac magnetic resonance, Journal of the American Society of Echocardiography: Official Publication of the American Society of Echocardiography 29 (2016) 392–401.
[12] D. Medvedofsky, K. Addetia, A.R. Patel, A. Sedlmeier, R. Baumann, V. Mor-Avi, R.M. Lang, Novel approach to three-dimensional echocardiographic quantification of right ventricular volumes and function from focused views, Journal of the American Society of Echocardiography: Official Publication of the American Society of Echocardiography 28 (2015) 1222–1231.
[13] D. Muraru, V. Spadotto, A. Cecchetto, G. Romeo, P. Aruta, D. Ermacora, C. Jenei, U. Cucchini, S. Iliceto, L.P. Badano, New speckle-tracking algorithm for right ventricular volume analysis from three-dimensional echocardiographic data sets: validation with cardiac magnetic resonance and comparison with the previous analysis tool, Eur. Heart J. Cardiovasc. Imaging 17 (2016) 1279–1289.
[14] S.A.M. Nashef, F. Roques, L.D. Sharples, J. Nilsson, C. Smith, A.R. Goldstone, U. Lockowandt, Euroscore ii, Eur. J. Cardiothorac. Surg. 41 (2012) 734–745.
[15] J. Patzelt, Y. Zhang, P. Seizer, H. Magunia, A. Henning, V. Riemlova, T.A. Patzelt, M. Hansen, M. Haap, R. Riessen, H. Lausberg, T. Walker, J. Reutershan, C. Schlensak, C. Grasshoff, D.I. Simon, P. Rosenberger, J. Schreieck, M. Gawaz, H.F. Langer, Effects of mechanical ventilation on heart geometry and mitral valve leaflet coaptation during percutaneous edge-to-edge mitral valve repair, JACC. Cardiovascular interventions. 9 (2016) 151–159.
[16] P. Ponikowski, A.A. Voors, S.D. Anker, H. Bueno, J.G.F. Cleland, A.J.S. Coats, V. Falk, J.R. Gonzalez-Juanatey, V.P. Harjola, E.A. Jankowska, M. Jessup, C. Linde, P. Nihoyannopoulos, J.T. Parissis, B. Pieske, J.P. Riley, G.M.C. Rosano, L.M. Ruilope, F. Ruschitzka, F.H. Rutten, P. van der Meer, 2016 esc guidelines for the diagnosis and treatment of acute and chronic heart failure, Revista espanola de cardiologia (English Ed.) 69 (2016) 1167.
[17] R.M. Lang, L.P. Badano, V. Mor-Avi, J. Afilalo, A. Armstrong, L. Ernande, F.A. Flachskampf, E. Foster, S.A. Goldstein, T. Kuznetsova, P. Lancellotti, D. Muraru, M.H. Picard, E.R. Rietzschel, L. Rudski, K.T. Spencer, W. Tsang, J.U. Voigt, Recommendations for cardiac chamber quantification by echocardiography in adults: an update from the american society of echocardiography and the european association of cardiovascular imaging, Journal of the American Society of Echocardiography: Official Publication of the American Society of Echocardiography 28 (2015) 1–39 e14.
[18] P. Lancellotti, L. Moura, L.A. Pierard, E. Agricola, B.A. Popescu, C. Tribouilloy, A. Hagendorff, J.L. Monin, L. Badano, J.L. Zamorano, European Association of E. European association of echocardiography recommendations for the assessment of valvular regurgitation. Part 2: mitral and tricuspid regurgitation (native valve disease), European journal of echocardiography: the Journal of the Working Group on Echocardiography of the European Society of Cardiology 11 (2010) 307–332.
[19] E. Foster, H.S. Wasserman, W. Gray, S. Homma, M.R. Di Tullio, L. Rodriguez, W.J. Stewart, P. Whitlow, P. Block, R. Martin, J. Merlino, H.C. Herrmann, S.E. Wiegers, F.E. Silvestry, A. Hamilton, A. Zunamon, K. Kraybill, I.L. Gerber, S.G. Weeks, Y. Zhang, T. Feldman, Quantitative assessment of severity of mitral regurgitation by serial echocardiography in a multicenter clinical trial of percutaneous mitral valve repair, Am. J. Cardiol. 100 (2007) 1577–1583.
[20] J. Patzelt, Y. Zhang, H. Magunia, R. Jorbenadze, M. Droppa, M. Ulrich, S. Cai, H. Lausberg, T. Walker, T. Wengenmayer, P. Rosenberger, J. Schreieck, P. Seizer, M. Gawaz, H.F. Langer, Immediate increase of cardiac output after percutaneous mitral valve repair (pmvr) determined by echocardiographic and invasive parameters: Patzelt: increase of cardiac output after pmvr, Int. J. Cardiol. 236 (2017) 356–362.
[21] O. Alfieri, F. Maisano, M. De Bonis, P.L. Stefano, L. Torracca, M. Oppizzi, G. La Canna, The double-orifice technique in mitral valve repair: a simple solution for complex problems, J. Thorac. Cardiovasc. Surg. 122 (2001) 674–681.
[22] C. Giannini, A.S. Petronio, M. De Carlo, F. Guarracino, L. Conte, F. Fiorelli, A. Pieroni, V. Di Bello, Integrated reverse left and right ventricular remodelling after mitraclip implantation in functional mitral regurgitation: an echocardiographic study, Eur. Heart J. Cardiovasc. Imaging 15 (2014) 95–103.
[23] A.C. van Riel, K. Boerlage-van Dijk, R.H. de Bruin-Bon, M. Araki, K.T. Koch, M.M. Vis, P.G. Meregalli, R.B. van den Brink, J.J. Piek, B.J. Mulder, J. Baan Jr., B.J. Bouma, Percutaneous mitral valve repair preserves right ventricular function, J. Am. Soc. Echocardiogr. 27 (2014) 1098–1106.
[24] W.A. Helbing, H.G. Bosch, C. Maliepaard, S.A. Rebergen, R.J. van der Geest, B. Hansen, J. Ottenkamp, J.H. Reiber, A. de Roos, Comparison of echocardiographic methods with magnetic resonance imaging for assessment of right ventricular function in children, Am. J. Cardiol. 76 (1995) 589–594.
[25] C. Giannini, F. Fiorelli, A. Colombo, M. De Carlo, S.H. Weisz, E. Agricola, C. Godino, F. Castriota, P. Golino, A.S. Petronio, Right ventricular evaluation to improve survival

outcome in patients with severe functional mitral regurgitation and advanced heart failure undergoing mitraclip therapy, Int. J. Cardiol. 223 (2016) 574–580.

[26] C. Godino, A. Salerno, M. Cera, E. Agricola, G. Fragasso, I. Rosa, M. Oppizzi, A. Monello, A. Scotti, V. Magni, M. Montorfano, A. Cappelletti, A. Margonato, A. Colombo, Impact and evolution of right ventricular dysfunction after successful mitraclip implantation in patients with functional mitral regurgitation, Int. J. Cardiol. Heart Vasc. 11 (2016) 90–98.

[27] H. Kaneko, M. Neuss, J. Weissenborn, C. Butter, Prognostic significance of right ventricular dysfunction in patients with functional mitral regurgitation undergoing mitraclip, Am. J. Cardiol. 118 (2016) 1717–1722.

[28] R. Osteresch, K. Diehl, M. Kühl, E. Fiehn, J. Schmucker, T. Backhaus, A. Fach, H. Wienbergen, R. Hambrecht, Impact of right heart function on outcome in patients with functional mitral regurgitation and chronic heart failure undergoing percutaneous edge-to-edge-repair, J. Interv. Cardiol. 31 (2018) 916–924.

[29] J.F. Obadia, D. Messika-Zeitoun, G. Leurent, B. Iung, G. Bonnet, N. Piriou, T. Lefevre, C. Piot, F. Rouleau, D. Carrie, M. Nejjari, P. Ohlmann, F. Leclercq, C. Saint Etienne, E. Teiger, L. Leroux, N. Karam, N. Michel, M. Gilard, E. Donal, J.N. Trochu, B. Cormier, X. Armoiry, F. Boutitie, D. Maucort-Boulch, C. Barnel, G. Samson, P. Guerin, A. Vahanian, N. Mewton, Investigators M-F, Percutaneous repair or medical treatment for secondary mitral regurgitation, N. Engl. J. Med. 379 (2018) 2297–2306.

[30] G.W. Stone, J. Lindenfeld, W.T. Abraham, S. Kar, D.S. Lim, J.M. Mishell, B. Whisenant, P.A. Grayburn, M. Rinaldi, S.R. Kapadia, V. Rajagopal, I.J. Sarembock, A. Brieke, S.O. Marx, D.J. Cohen, N.J. Weissman, M.J. Mack, Transcatheter mitral-valve repair in patients with heart failure, N. Engl. J. Med. 379 (2018) 2307–2318.

[31] O. Gaemperli, P. Biaggi, R. Gugelmann, M. Osranek, J.J. Schreuder, I. Buhler, D. Surder, T.F. Luscher, C. Felix, D. Bettex, J. Grunenfelder, R. Corti, Real-time left ventricular pressure-volume loops during percutaneous mitral valve repair with the mitraclip system, Circulation 127 (2013) 1018–1027.

[32] R.J. Siegel, S. Biner, A.M. Rafique, M. Rinaldi, S. Lim, P. Fail, J. Hermiller, R. Smalling, P.L. Whitlow, H.C. Herrmann, E. Foster, T. Feldman, D. Glower, S. Kar, E. Investigators, The acute hemodynamic effects of mitraclip therapy, J. Am. Coll. Cardiol. 57 (2011) 1658–1665.

[33] H. Kaneko, M. Neuss, T. Schau, J. Weissenborn, C. Butter, Impact of left ventricular systolic dysfunction on the outcomes of percutaneous edge-to-edge mitral valve repair using mitraclip, Heart Vessel. 31 (2016) 1988–1996.

[34] J. Patzelt, M. Ulrich, H. Magunia, R. Sauter, M. Droppa, R. Jorbenadze, A.S. Becker, T. Walker, R.S. von Bardeleben, C. Grasshoff, P. Rosenberger, M. Gawaz, P. Seizer, H.F. Langer, Comparison of deep sedation with general anesthesia in patients undergoing percutaneous mitral valve repair, J. Am. Heart Assoc. 6 (2017).