Operative Techniques in
Sports Medicine

Arthroscopic Allograft Procedure for Restoring Humeral Head Defects

Jonathan J. Streit, MD, Yousef Shishani, MD, and Reuben Gobezie, MD

Treatment of focal osteochondral defects of the humeral head poses a challenge to orthopedic surgeons. Patients with this kind of pathology often present with loss of function and pain. Smaller osteochondral defects of the humeral head are often missed as a source of the patient's pain and are usually incidentally reported at the time of surgery. Good outcomes have been reported with open surgical techniques for the treatment of focal osteochondral defects. Smaller defects are usually more difficult to manage due to restrictions and limitations in the surgical approaches and techniques needed to access the affected area in order to properly assess the defect. This article describes a pioneered all-arthroscopic surgical technique for the treatment of focal osteochondral defects of the humeral head lesions.
Oper Tech Sports Med 27:102-106 **© 2019 Elsevier Inc. All rights reserved.**

KEYWORDS **Focal humeral head defects, arthroscopic resurfacing, osteochondral allograft**

Focal osteochondral defects of the humeral head may result from acute or repetitive trauma, damage from prior surgical procedures, or avascular necrosis, and often result in severe limitation of function in an otherwise active patient population.[1-5] Osteochondral defects of the humeral head may fail to be recognized as a source of a patient's pain when they are small, and often articular cartilage damage is noted incidentally at the time of arthroscopy, with Outerbridge grade II-IV lesions being reported at 5%-17% in the literature.[6] The humeral head articular cartilage is 1.2-1.3 mm thick in the central portion of the humeral head, and less than 1 mm thick peripherally,[5] making it prone to damage. Although large defects have historically been treated by open surgical techniques with good success, smaller pain-generating defects have been more difficult to manage due to problems accessing the area without significant surgical morbidity. Surgeon experience and patient expectations make this a difficult problem to manage effectively.

Open surgical techniques to address humeral head defects with allograft have been described, with variable success rates.[7] These techniques describe transplantation of osteochondral allograft using size- and radius-matched grafts with press-fit impaction, with or without adjunctive fixation devices. Recent advances in surgical implants have made the use of allograft less popular among some surgeons, as some defects may be effectively managed with metal resurfacing. However, allograft transplantation for defects of irregular shape or abnormal position remains a good surgical option with literature to support its use. Specifically, instability of the shoulder with large Hill-Sachs impaction fracture of the posterior humeral head has been treated successfully with bulk allograft transplantation when remplissage techniques are insufficient to fill the defect. Saltzman et al described defects of greater than 40% of the articular surface as being amenable to open allograft transplantation using size-matched fresh-frozen humeral or femoral head allograft.[8] We currently use this technique as an open procedure for restoring bone to the posterior humeral head in cases of large Hill-Sachs lesions in a young, active patient.

Subtle instability or repetitive injury to the shoulder may result in smaller osteochondral defects of the humeral head that are more difficult to localize or treat. These defects may result in painful crepitus and restricted motion in a young patient population, causing limitation of function in work and recreation. Many of these patients have been evaluated by other sports medicine specialists or orthopaedic surgeons, and radiographic imaging may be normal. Magnetic resonance imaging (MRI) is often used to diagnose or make treatment planning decisions, but imaging has been shown to

Cleveland Shoulder Institute, Cleveland, OH.
Address reprint requests to Reuben Gobezie, MD, Cleveland Shoulder Institute, 3755 Orange Pl, #101, Beachwood, OH 44122. E-mail: yousef@clevelandshoulder.com

 https://doi.org/10.1053/j.otsm.2019.03.009
1060-1872/© 2019 Elsevier Inc. All rights reserved.

miss osteochondral lesions of the humeral head often (60% accuracy and 87% sensitivity),[7] and arthroscopy is considered to be the gold standard for diagnosis. Other treatment options, including conservative management with corticosteroid injections, physical therapy, and activity modification, should be considered as a first-line treatment before operative management.

Other treatment options for small osteochondral defects have been met with limited success. Arthroscopic debridement and capsular release may be used to smooth cartilage defects and release capsular contractures, providing pain relief and better mechanical function. The procedure may reduce contact pressures, but does not prevent further deterioration of the joint.[9] Also, it has been shown that the procedure does not work well for patients with osteochondral lesions greater than 2 cm^2.[10] Arthroscopic microfracture has produced some good outcomes for unipolar lesions of the humeral head,[11] and a study of these procedures analyzed at reoperation did show filling of the defect with fibrocartilage.[12] However, because no accepted gold standard treatment exists for the treatment of these lesions, the plan must be tailored to the individual patient. In selected patients, we have found that the use of an arthroscopic resurfacing technique using fresh humeral head allograft may be appropriate to restore function and reduce pain while allowing for accelerated recovery.

Indications

Arthroscopic allograft treatment of humeral head defects is used to treat focal defects of the humeral head that are thought to be the cause of shoulder pain in younger, active patients for whom partial metal resurfacing or shoulder hemiarthroplasty would otherwise be considered. This procedure conserves bone and preserves the integrity of the subscapularis tendon, allowing for early motion of the shoulder and faster return to function for this active patient population. In many cases, patients are selected for the procedure after previous arthroscopy or MRI has identified the lesion and all other etiologies of shoulder pain, including infection, have been ruled out. Older patients in whom anatomic total shoulder arthroplasty would be reasonable are not selected for the procedure. In many cases, these patients have had multiple operations and desire a return to full activities in their job and recreational activities.

Technique

The technique for arthroscopic osteochondral allograft resurfacing of the humeral head utilizes a transhumeral portal for retrograde reaming of the small defects after localization with the arthroscope. The technique described in this manuscript deals specifically with arthroscopic resurfacing of the humeral head to treat unipolar lesions.

We perform arthroscopic humeral head resurfacing as an outpatient procedure under general anesthesia with the patient in the beach chair position. Interscalene block is administered prior to surgery for postoperative pain control. Standard diagnostic arthroscopy is performed using a posterior portal and an anterior working portal is created in the rotator interval. The rotator interval is completely resected with a shaver to create a working space. Accessory portals may be necessary to perform adjunctive portions of the procedure as well. Due to the nature of the condition being treated, biceps tenotomy or tenodesis is often necessary and should be performed first. Depending on the size of the graft to be used, the rotator interval portal will be extended to allow passage of the graft and associated instrumentation. An arthroscopic aiming device, (Fig. 1) similar to that used in anterior cruciate ligament reconstruction, is used to localize the transhumeral portal and to then pass a guidepin through the center of the defect (Fig. 2). Once the pin position is determined to be satisfactory, the surgeon must create the lateral transhumeral portal using careful dissection, as the portal is often in close proximity to the axillary nerve. A cannulated reamer is then advanced over the guide pin and through the humeral head articular surface. A small metal cannula is then passed through the humeral head (Fig. 3) to allow for easy passage of a retrograde reamer. Depending on the size of the defect, the appropriate diameter is selected and passed through the anterior working portal to connect with the reamer barrel that is inserted through the transhumeral cannula under direct arthroscopic visualization. The

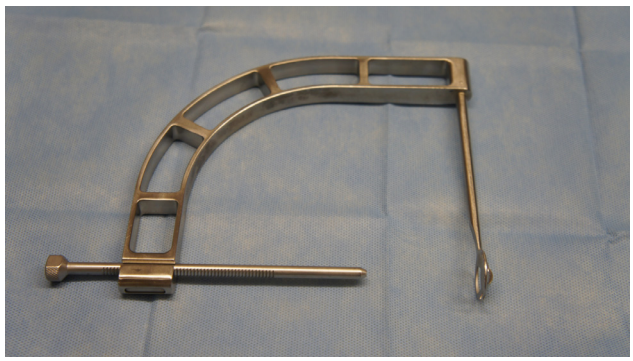

Figure 1 Arthroscopic osteochondral resurfacing of the humeral head utilizes a guide similar to that used for anterior cruciate ligament (ACL) reconstruction to localize the lesion on the humeral head.

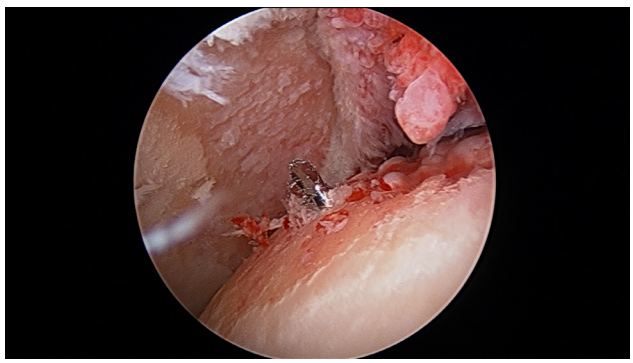

Figure 2 A guide pin is drilled from lateral to medial through the humeral head using a transhumeral approach.

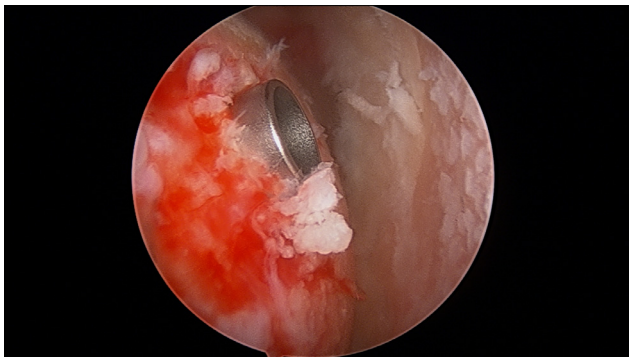

Figure 3 The transhumeral portal is placed by over-reaming the guide pin, allowing easy access to the glenohumeral joint throughout the procedure.

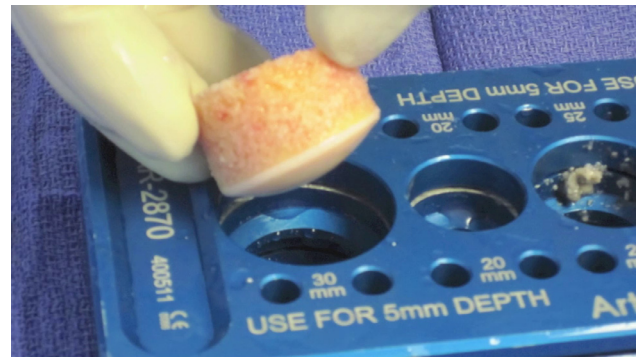

Figure 6 A coring reamer has been used to harvest a section of the allograft humeral head.

reamer is then run in a forward direction while pulling the reamer laterally to create a uniform defect of known size and depth in the humeral head articular surface (Fig. 4).

Once the size of the defect created by the reamer is known, we harvest the osteochondral graft from our fresh cadaveric humeral head specimen (Fig. 5) using an Osteochondral Allograft Transfer System platform (Arthrex, Naples, FL). Size matching of the patient is attempted using known measurements taken from the preoperative MRI or CT scan. Most defects treated with this technique are 15-25 mm in diameter (Fig. 6). A coring reamer is used to take the graft, and the thickness is trimmed with an oscillating saw to a standard 5 mm (Fig. 7). A small hole is made centrally with a drill for passage of a suture, and a knot is tied on the articular side (Fig. 8). This will allow passage of the graft into the joint and into the reamed defect as the suture is pulled from medial to lateral through the transhumeral portal.

Attention is then turned back to the shoulder, and a nitinol wire is passed from lateral to medial through the transhumeral sleeve, and pulled out through the rotator interval portal. The suture attached to the graft is then passed back through the

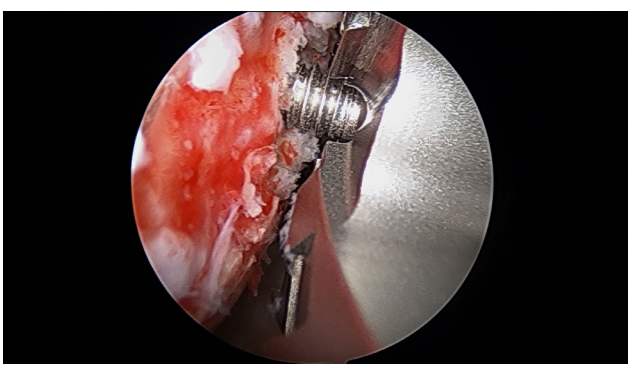

Figure 4 The humeral head is reamed in a retrograde fashion using a reamer that is assembled in the joint under direct visualization.

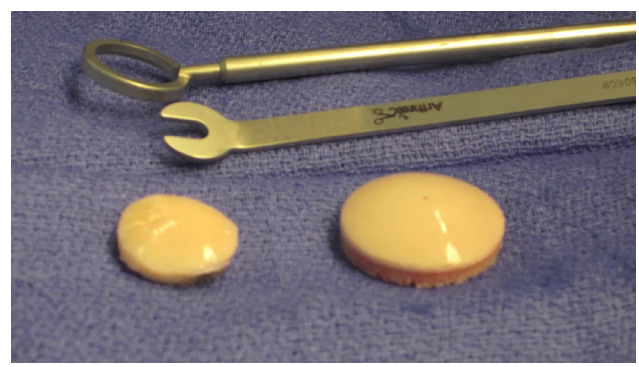

Figure 7 The humeral head allograft plug is trimmed to a thickness of 5 mm prior to implantation.

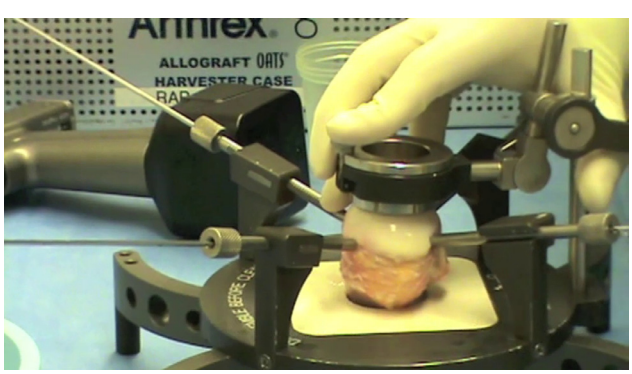

Figure 5 An Osteochondral Allograft Transfer System (OATS) platform is used to harvest fresh osteochondral allograft for the procedure.

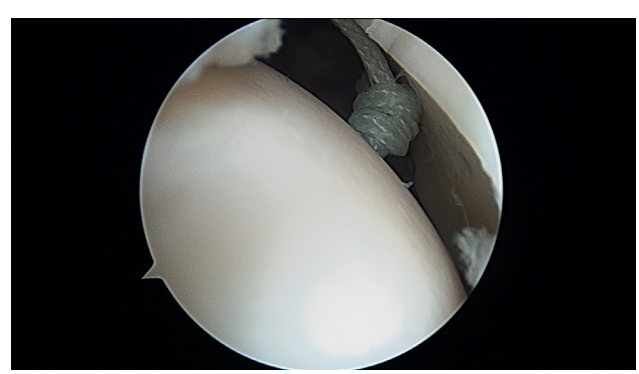

Figure 8 The humeral head allograft plug is shuttled into the joint using a suture and pulled from medial to lateral and into position using the transhumeral portal.

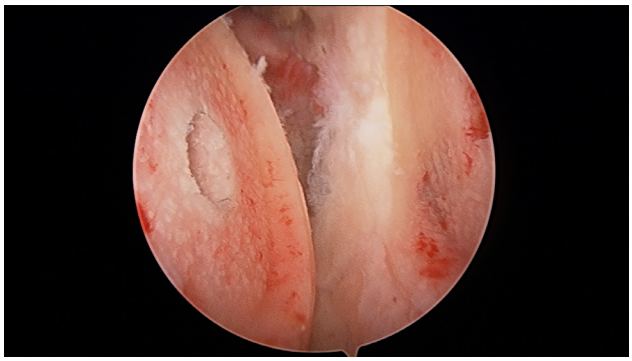

Figure 9 Bipolar lesions of the humerus and glenoid can be treated using this technique as well, with anterograde reaming of the glenoid accomplished using the transhumeral portal.

shoulder and out the lateral transhumeral portal. The osteochondral graft is provisionally positioned over the reamed area, and a small impactor or fingertip pressure is used to fully seat the graft. The knotted end of the suture is then pulled out the anterior portal to remove the suture. The graft may be further compressed using gentle rotational and overhead motion of the shoulder under direct visualization. Portals are then closed using absorbable suture, and the patient is immobilized in a sling for comfort. Gentle passive motion is begun within the first week after surgery, and rehabilitation may proceed according to the comfort of the patient, as no repair of the rotator cuff is necessary with this procedure.

In some cases, glenoid resurfacing of smaller defects is also necessary, and this may be accomplished using the same transhumeral portal in an anterograde fashion (Fig. 9). The results of bipolar osteochondral resurfacing have been variable, with some young patients returning to a high level of function.

Surgeons interested in attempting this technique should note that arthroscopic resurfacing of the humeral head with allograft necessitates a good understanding of arthroscopic anatomy and portal placement. Our technique uses standard portals, including a posterior viewing portal and a standard anterior portal within the rotator interval. The technique relies upon the use of an additional, transhumeral portal which must be placed under direct visualization due to the proximity of the axillary nerve. The axillary nerve is generally considered not to be at risk with standard arthroscopic portals of the shoulder, as standard portals do not need to be made outside the safe zone of 5 cm from the edge of the acromion. However, the variable anatomy has been described by Burkhead et al[13] and the lateral portal for this procedure must be made considerably more distal than is standard due to the need to approach the humeral articular surface at the correct angle using a guide. Careful dissection through the deltoid muscle is essential when using this technique.

Outcomes

The literature regarding outcomes following humeral head resurfacing of small defects is limited at the present time. Also, the pathology encountered at surgery is variable, making a uniform analysis difficult. Our minimum 2-year data (mean 30.8 months) examined a cohort of 20 patients of mean age 49.6 years who underwent allograft resurfacing of both the humerus and glenoid.[14] American Shoulder and Elbow Surgeons Shoulder Score (ASES) score improved from 37.6 to 68.9 ($P < 0.001$), Visual Analogue Scale (VAS) pain score improved from 6.1 to 3.4 ($P = 0.0006$), active forward elevation improved from 109 to 142 ($P = 0.0014$), active external rotation improved from 33 to 42 ($P = 0.12$) and internal rotation remained unchanged at the level of L4. Half of patients (10/20) were satisfied with their outcome, and 3 underwent conversion to anatomic total shoulder arthroplasty. Of note, 65% of these patients had a Walch type B glenoid, and the cohort had undergone a mean of 3 prior shoulder procedures, making this a very challenging population. Average humeral graft coverage by MRI was 22%, and no graft resorption was noted at final follow-up.

Conclusion

Arthroscopic resurfacing of small humeral head defects is a tool available to surgeons when treating selected cases of focal osteochondral defects. The short-term outcomes of the procedure are variable and data are limited, but good outcomes in some young patients make this a continued area of active clinical research.

References

1. Good CR, Shindle MK, Kelly BT, et al: Glenohumeral chondrolysis after shoulder arthroscopy with thermal capsulorrhaphy. Arthroscopy 23:797.e1-797.e5, 2007. https://doi.org/10.1016/j.arthro.2007.03.092
2. Levine WN, Clark AMJ, D'Alessandro DF, et al: Chondrolysis following arthroscopic thermal capsulorrhaphy to treat shoulder instability: A report of two cases. JBJSA 87:616-621, 2005. https://doi.org/10.2106/JBJS.D.02158
3. Lu Y, Edwards RB III, Nho S, et al: Thermal chondroplasty with bipolar and monopolar radiofrequency energy: Effect of treatment time on chondrocyte death and surface contouring. Arthroscopy 18:779-788, 2002. https://doi.org/10.1053/jars.2002.32840
4. Ryan A, Bertone AL, Kaeding CC, et al: The effects of radiofrequency energy treatment on chondrocytes and matrix of fibrillated articular cartilage. Am J Sports Med 31:386-391, 2017. https://doi.org/10.1177/03635465030310031001
5. Elser F, Dewing CB, Millett PJ: Chondral and osteochondral lesions of the humerus: Diagnosis and management. Op Tech Sports Med 16:178-186, 2008. https://doi.org/10.1053/j.otsm.2008.12.005
6. Paley KJ, Jobe FW, Pink MM, et al: Arthroscopic findings in the overhand throwing athlete: Evidence for posterior internal impingement of the rotator cuff. Arthroscopy 16:35-40, 2000. https://doi.org/10.1016/S0749-8063(00)90125-7
7. Seidl AJ, Kraeutler MJ: Management of articular cartilage defects in the glenohumeral joint. J Am Acad Orthop Surg 26:e230-e237, 2018. https://doi.org/10.5435/JAAOS-D-17-00057
8. Saltzman BM, Riboh JC, Cole BJ, et al: Humeral head reconstruction with osteochondral allograft transplantation. Arthroscopy 31:1827-1834, 2015. https://doi.org/10.1016/j.arthro.2015.03.021
9. Richards DP, Burkhart SS: Arthroscopic debridement and capsular release for glenohumeral osteoarthritis. Arthroscopy 23:1019-1022, 2007. https://doi.org/10.1016/j.arthro.2006.11.016
10. Cameron BD, Galatz LM, Ramsey ML, et al: Non-prosthetic management of grade IV osteochondral lesions of the glenohumeral

joint. J Shoulder Elb Surg 11:25-32, 2002. https://doi.org/10.1067/mse.2002.120143
11. Millett PJ, Huffard BH, Horan MP, et al: Outcomes of full-thickness articular cartilage injuries of the shoulder treated with microfracture. Arthroscopy 25:856-863, 2009. https://doi.org/10.1016/j.arthro.2009.02.009
12. Snow M, Lennard F: Microfracture of chondral lesions of the glenohumeral joint. Int J Shoulder Surg 2:72, 2008. https://doi.org/10.4103/0973-6042.44142
13. Burkhead WZ Jr, Scheinberg RR, Box G: Surgical anatomy of the axillary nerve. J Shoulder Elb Surg 1:31-36, 1992. https://doi.org/10.1016/S1058-2746(09)80014-1
14. Gobezie R, Shishani Y, Flocken J, et al: Two year results of all arthroscopic resurfacing of the glenohumeral joint with fresh osteochondral allograft: A prospective study. J Shoulder Elb Surg 25:e166, 2016. https://doi.org/10.1016/j.jse.2015.11.018