Magnetic Resonance Imaging 57 (2019) 285–292

Contents lists available at ScienceDirect

Magnetic Resonance Imaging

journal homepage: www.elsevier.com/locate/mri

Original contribution

Diagnostic efficacy of MRI for pre-operative assessment of ovarian malignancy in endometrial carcinoma: A decision tree analysis

Xiaojuan Xu[a], Nan Li[b], Yan Chen[a], Han Ouyang[a], Xinming Zhao[a], Jing Zhou[c,*]

[a] Department of Diagnostic Imaging, National Cancer Center/Cancer Hospital, Chinese Academy of Medical Sciences and Peking Union Medical College, Beijing, China
[b] Research Center of Clinical Epidemiology, Peking University Third Hospital, Beijing, China
[c] Department of Gynecology, The Central Hospital of Karamay, Xinjiang, Uyghur Autonomous Region, China

ARTICLE INFO

Keywords:
Endometrial carcinoma
Ovarian neoplasms
Magnetic resonance imaging
Decision tree

ABSTRACT

Aim: Accurate preoperative assessment of ovarian malignancy in endometrial carcinoma helps in determining the decision to preserve the ovaries in individualized treatment. This study adopted decision tree method to evaluate the diagnostic efficiency of pelvic MRI and clinical data of patients for preoperative identification of endometrial carcinoma-combined ovarian malignancy (EC-OM).

Material and methods: This retrospective study included a total of 801 patients, and postoperative pathological examinations identified 58 EC-OM group and 743 endometrial carcinoma cases without ovarian malignancy (EC group). Diagnostic efficiency of pelvic MRI in EC-OM was calculated by comparing the clinical data and imaging features of patients in the two groups. Decision tree analysis was performed to screen out associative indexes and establish a diagnostic model for EC-OM.

Results: Pelvic MRI showed that, EC-OM group showed deeper invasion into the myometrium, and higher percentages of patients with cervical or cornual involvement, or metastasis of lymph nodes or peritoneum than EC group ($P = 0.00$). Preoperative pelvic MRI showed a sensitivity of 51.72% and a specificity of 99.87% when detecting ovarian malignancy in endometrial carcinoma. Decision tree model obtained a sensitivity of 89.66%, with an AUC (area under ROC curve) of 0.949 (95% CI 0.906, 0.993, $P < 0.001$).

Conclusion: Decision tree analysis based on pelvic MRI and clinical data of patients showed that the detection rate of ovarian malignancy could be increased for patients with endometrial carcinoma.

1. Introduction

Endometrial carcinoma is one of the major gynecologic malignant tumors of female. It is commonly seen in postmenopausal women, and accounts for only 20% in premenopausal patients [1]. Endometrial carcinoma has the highest incidence among all gynecologic malignancies of female in some European and American countries [2]. With the rapid development of social economy, and constant increase of living standards as well as change in the diet structure, a rising trend in the incidence of endometrial carcinoma is experienced in China, even exceeded the prevalence of cervical cancer in some areas [3]. Also, the age of disease onset is trending younger, as 13.5% of patients with endometrial carcinoma are below 40 years [4]. However, due to early clinical symptoms, > 70% of patients are diagnosed at stage I and the 5-year survival was over 90% [5].

According to the FIGO (International Federation of Gynecology and Obstetrics) surgical staging of endometrial carcinoma, a standard operation includes total hysterectomy plus bilateral adnexectomy plus pelvic/abdominal para-aortic lymphadenectomy. This could achieve complete removal of the lesion, and would help to determine staging as well as postoperative adjuvant therapies. But latrogenic menopause caused by ovariectomy might cause serious adverse effects on the quality of life of young patients with long-term survival after standard operation [6]. The international consensus on treatments of endometrial carcinoma has put forwarded individualized and comprehensive treatment schemes for patients according to their tumor staging, degree of differentiation, age, fertility, and physiological needs [7–10]. Therefore, accurate preoperative assessment of ovarian malignancy, including metastasis or synchronous endometrial and ovarian carcinoma, would help in achieving the above targets. Pelvic MRI with

Abbreviations: DCE, dynamic contrast enhancement; DTI, diffusion tensor imaging; DWI, diffusion weighted imaging; EC, endometrial cancer; EC-OM, endometrial carcinoma-combined ovarian malignancy; MRS, magnetic resonance spectrum; ROC, receiver operating characteristics

* Corresponding author.
E-mail address: zhou_gyn@126.com (J. Zhou).

https://doi.org/10.1016/j.mri.2018.12.008
Received 31 July 2018; Received in revised form 17 October 2018; Accepted 19 December 2018
0730-725X/ © 2018 Published by Elsevier Inc.

multi-parametric techniques has been widely used in the diagnosis and preoperative staging of endometrial carcinoma, and the accuracy of staging can reach up to 82.1% [11]. Present studies on endometrial carcinoma largely focused on determining the depth of myometrial infiltration, lymph node metastasis, and the degree of tissue differentiation [12]. But no study till date has reported imaging-involved diagnosis of ovarian malignancy found in endometrial carcinoma. Due to small size of the ovary and less morphological and physiological changes, ovarian malignancy is hardly detected during the early phase by imaging examinations. Decision tree analysis is a mathematical algorithm and modeling method, which has been extensively used in various fields of research due to its advantages in data classification and mining. As for medical imaging, decision tree analysis could help to fully analyze the imaging features and clinical data of patients, thereby establishing diagnostic models and improve the diagnostic capacity of diseases [13].

Hence, this paper uses decision tree analysis to establish a diagnostic model based on the pelvic MRI and clinical data of patients, thus exploring the application value of this method in preoperative diagnosis of endometrial carcinoma combined with ovarian malignancy.

2. Materials and methods

2.1. Patient inclusion and clinical data

This retrospective and non-interventional study has been approved by the Ethics Committee of our hospital (No. NCC2016 YQ-03), and all patients signed informed content before undergoing examination. Clinical data of patients receiving treatment for endometrial carcinoma in the hospital between January 2011 and September 2016 were collected via the medical record inquiry system of the hospital. Inclusion criteria and study population was presented in Fig. 1. A total of 1109 patients were collected, and 801 patients met the inclusion criteria and were included in this study. After operation, by post-surgical histopathology, 58 patients had confirmed endometrial cancer with ovarian malignancy (the EC-OM group, including 46 with ovarian metastatic carcinoma and 12 with ovarian primary synchronous carcinoma), and 743 patients were confirmed to have endometrial cancer without ovarian malignancy (EC group). Clinical data of patients were collected, including age at onset and the levels of serum tumor markers (CA125, CA199 and CEA) at 2 weeks before surgery.

2.2. Imaging examination

Pelvic MRI was performed by using MR scanner with phased array body coils (GE Signa Excite HD 3.0 T, Waukesha, WI, USA). Parameters for plain scanning mainly included axial FSE T1WI (TR = 620 ms, TE = 8.2 ms), T2WI with fat suppression (using frequency selective fat saturation method, TR = 5000 ms, TE = 106.6 ms, layer thickness = 5 mm, layer spacing = 1 mm), axial T2WI with a small field of view at high resolution (TR = 5400 ms, TE = 130 ms, FOV = 26 cm, NEX = 4, layer thickness = 4 mm, layer spacing = 0.4 mm), and axial SE-EPI DWI (TR = 5500 ms, TE = 62.7 ms, layer thickness = 5 mm, layer spacing = 1 mm, b = 0 mm^2/s and 800 mm^2/s). Dynamic contrast enhancement (DCE) scanning was done by injecting gadopentetate dimeglumine (Magnevist, Bayer Pharmaceuticals) into the upper limb vein by using a high-pressure syringe, with a flow rate at 2.5 ml/s and a total dose of 0.2 mmol/kg body weight. A total of 15 phases were obtained post-drug injection with a time interval of 15 s in the sagittal plane, followed by a delayed phase of isotropy axial scanning.

2.3. Image analysis and assessment

All imaging data were blindly reviewed by two radiologists who had experience in gynecological tumor imaging for 13 and 6 years. The two radiologists were unaware of the clinical or pathological data of the patients. Standardized training was performed before reviewing the image in order to ensure the consistency of assessment as much as possible. Observation of endometrial lesions mainly included depth of myometrial infiltration, involvement of parametrium, cervix or cornua, and the conditions of pelvic lymph nodes as well as peritoneal carcinomatosis. Lymph node metastasis was diagnosed if the swelling lymph nodes short diameter exceeded 0.8 cm, high signals in b = 800 mm^2/s DW images were detected, or inhomogeneous enhancement and central

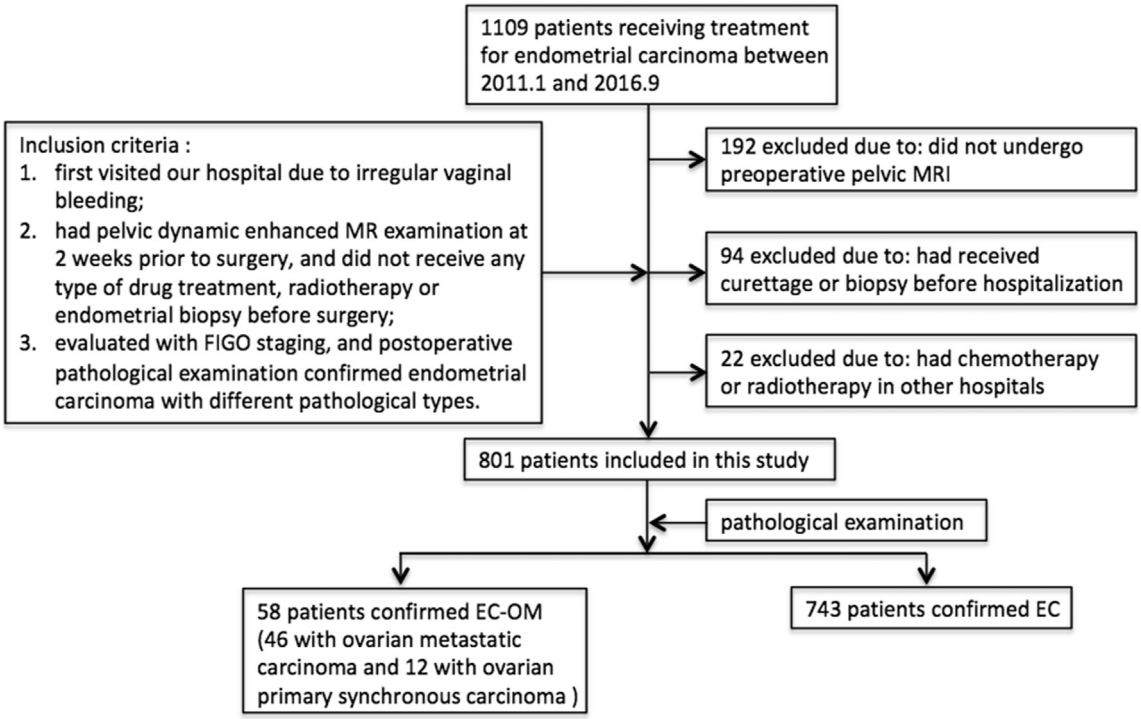

Fig. 1. Flowchart of study population.

	Morphology	Edge	MR signals	Peritoneum nodules or ascites
Considered benign	round or oval	clear	low on T1WI and uniform medium or high on T2WI; no enhancement or homogeneous enhancement; definite fat or ossification signals	negative
Possibility of benign > 50%	round or oval	clear	low on T1WI and uniform medium or high on T2WI; a slightly inhomogeneous enhancement; cystic masses combined with uniform papillary nodules, or solid masses with uniform texture.	negative
Not sure	lobules	part is unclear	low on T1WI and inhomogeneous on T2WI; cystic lesions with irregular solid papillary structures; high on DWI; inhomogeneous enhancement in the solid parts	negative
Possibility of malignant > 50%	irregular	unclear	low on T1WI and mixed heterogeneous with high on T2WI; high on DWI and heterogeneous enhancement in solid parts.	could see
Considered malignant	irregular, cystic or solid	unclear	low on T1WI and mixed heterogeneous with high on T2WI; high on DWI and heterogeneous enhancement in solid parts.	positive

Fig. 2. Five-stage classifications of adnexa masses evaluated by MRI.

necrosis were identified on DCE and delayed phase sequences. Adnexa masses were evaluated and classified into five stages from benign to malignant by our common experience (Fig. 2).

2.4. Surgical and pathological data

All patients were staged according to the FIGO2009 criteria [14], and underwent standard staging operation. Pathological examination was performed by a physician with 25 years of experience in gynecologic tumor pathology department. The pathological type of endometrial carcinoma, degree of tissue differentiation, depth of myometrial infiltration, involvement of parametrium, cervix or cornua, and the conditions of pelvic lymph nodes as well as peritoneal carcinomatosis were observed and recorded in addition to the FIGO staging of patients. Those ovarian tumors were also recorded according to their pathological types and tissue differentiation degrees [15].

2.5. Statistical analysis

Statistical analysis was performed using SPSS 21.0 software (IBM Corp., Armonk, NY, USA). Intergroup comparison was made by independent-sample *t*-test or Mann-Whitney *U* test. Intergroup comparison of categorical variables was made by single-factor χ^2 test. Diagnostic efficacy of preoperative pelvic MRI and surgical exploration was evaluated by diagnostic test. Preoperative information (age, serum tumor markers and MRI characteristic) was used to construct a classification tree using Pearson chi-squared interaction detection (CHAID) methodology. If the target was a binary variable, it refers to the final diagnosis as ovarian malignancy. Adjustments were as follows: considering the finite sample size, the minimum number of cases for parent nodes was n = 40 and child nodes was n = 20. The significance level for splitting nodes was set to $\alpha = 0.05$ by applying classical Bonferroni correction to avoid α error accumulation. Tenfold cross-validation was applied to assess the generalizability of the classification model. For estimation of general diagnostic accuracy, the area under the receiver operating characteristics (ROC) curve was calculated.

The consistency of evaluations made by two physicians on preoperative images was measured by Kappa test. K values < 0.2 indicate poor consistency, K within 0.21–0.4 indicates low consistency, K within 0.41–0.6 indicates moderate consistency, K within 0.61–0.8 indicates high consistency, and K > 0.8 indicates very good consistency. For all tests and comparisons, $P < 0.05$ was defined as statistical significance.

3. Results

3.1. Comparison of clinical and pathological features of patients in two groups

Of the 801 patients with endometrial carcinoma, 7.2% (58/801) were found with ovarian malignancy, including 5.7% (46/801) with metastatic ovarian carcinoma and 1.5% (12/801) with primary ovarian carcinoma. In patients under 50 years, ovarian malignancy occupied 12.8% (10/78) of all endometrial carcinoma cases. Age distribution and levels of serum tumor markers of endometrial cancer with ovarian malignancy (EC-OM) and endometrial cancer (EC) groups are shown in Table 1. Normality test suggested normal distribution of patient's age. The mean age of EC-OM patients was 56.1 ± 6.8 years, and that of EC patients was 56.8 ± 9.0 years, with no statistical significance between the two groups ($t = 0.6$, $P = 0.6$). The levels of three serum tumor markers did not fit the normal distribution, so they were compared by independent-sample Mann-Whitney *U* test. The results showed that the patients in the two groups were significantly different in all three serum tumor markers, and the values for EC-OM group were significantly higher than the EC group ($P < 0.05$ for all comparisons). Also, significant differences were identified between the two groups in their pathological types, tissue differentiation degrees, and FIGO staging results. To be specific, 93.1% of tumors in the EC group had a pathological type of endometrioid carcinoma, while only 62.1% of tumors in the EC-OM group belonged to this type. The mean size of malignant tumors in the EC-OM group was 3.2 ± 2.1 cm. In the EC-OM group, 46 cases had metastatic carcinoma, and 12 had synchronous primary carcinomas in the ovary and uterus. The latter of which were all

Table 1
Clinical and histological characteristics: EC-OM group vs. EC group.

		EC-OM group	EC group	*P*
Age[a] (years)		56.1 ± 6.8	56.8 ± 9.0	0.58
Tumor marker[b]	CA125 (U/ml)	71.67 (8.24–2271.00)	18.55 (4.23–968.50)	< 0.01
	CA199 (U/ml)	32.99 (0.60–2568.00)	15.51 (0.60–1526.00)	< 0.01
	CEA (ng/ml)	1.93 (0.35–48.53)	1.57 (0.20–34.54)	0.03
Histologic subtype	Endometrioid type	36(62.1%)	692 (93.1%)	0.00
	Non-endometrioid type	22 (37.9%)	51 (6.9%)	
Tumor grade	1	22 (37.93%)	136 (18.30%)	0.00
	2	23 (39.66%)	403 (54.24%)	
	3	6 (10.34%)	187 (25.17%)	
	N/A[c]	7 (12.07%)	17 (2.29%)	
Stage	I	10 (17.24%)	606 (81.56%)	0.00
	II	4 (6.90%)	82 (11.04%)	
	III	35 (60.34%)	51 (6.86%)	
	IV	9 (15.52%)	4 (5.38%)	

[a] Mean ± SD.
[b] Median (range).
[c] N/A, not available in non-endometrioid type.

endometrioid carcinomas.

3.2. Comparison of pelvic MRI characteristics in EC-OM and EC groups of patients

Comparison of pelvic MRI characteristics of the EC-OM and EC groups was shown in Table 2. Review of the two radiologists showed high consistency, with a K value of 0.7 and a 95% CI (0.6, 0.8). Compared to the patients in EC group, EC-OM group patients had higher percentages of cervical and cornual involvement, pelvic lymph node enlargement, and peritoneal carcinomatosis ($P < 0.05$ for all comparisons), but no significant difference was identified in terms of parametrial involvement (1.7% vs 0.4%, $P = 0.3$). The percentage of superficial myometrial infiltration and serosa infiltration in the EC-OM group was 44.8% (26/58) and 29.3% (17/58), respectively, and the corresponding values in the EC group was 51.6% (383/743) and 1.2% (9/743). In the EC-OM group, 34 patients (34/58, 58.6%) were identified with adnexal masses, while patients in the EC group had a significantly lower ($P < 0.01$) number, which was only 54 (54/743, 7.3%, Fig. 3).

3.3. Assessment of diagnostic efficiency of pelvic MRI and surgical exploration in endometrial carcinoma with ovarian malignancy

Table 3 showed the diagnostic efficiency of malignant ovarian tumors by preoperative pelvic MRI. A total of 34 and 54 cases with adnexal masses were identified by pelvic MRI, respectively from the EC-OM and EC groups. MRI-undetected lesions, "considered benign" lesions, and "possibility of benign > 50%" lesions were considered as negative determinations, and taking lesions "not sure", "possibility of malignant > 50%" and "considered malignant" as positive determination. The sensitivity of preoperative MRI detection was 51.7% (30/58), the specificity was 99.9% (742/743), the accuracy was 96.4% (772/801), the missed diagnose rate was 48.3% (28/58), and the misdiagnosed rate was 0.1% (1/743). By reviewing the surgical records, results revealed that 33 patients from the EC-OM group were identified with ovarian malignancy during operation, and 25 were not identified. However, no patients were found with ovarian malignancy during operation in the EC group. Surgical exploration had a sensitivity of 56.9% (33/58) and a specificity of 100.0% (743/743) in identifying ovarian malignancy.

Table 2
Pelvic MRI characteristics: EC-OM group vs. EC group.

		EC-OM group		EC group		χ^2	*P*
		Patients (no.)	%	Patients (no.)	%		
Myometrial invasion	Normal	1	1.72%	25	3.36%	139.20	0.00
	Limited to endometrium	3	5.17%	161	21.67%		
	< 1/2 myometrium	26	44.83%	383	51.55%		
	≥1/2 myometrium	11	18.97%	165	22.21%		
	Full thickness	17	29.31%	9	1.21%		
Parametrium extension	No	57	98.28%	740	99.60%	1.89	0.26
	Yes	1	1.72%	3	0.40%		
Cervical extension	No	39	67.24%	643	86.54%	15.84	0.00
	Yes	19	32.76%	100	13.46%		
Cornua uteri involvement	No	14	24.14%	743	100.00%	596.42	0.00
	Yes	44	75.86%	0	0.00%		
Adnexal mass	No	24	41.38%	689	92.73%	74.82	0.00
	Yes	34	58.62%	54	7.27%		
	Benign	0	0.00%	47	87.04%		
	Benign > 50%	4	11.76%	6	11.11%		
	Not sure	1	2.94%	1	1.85%		
	Malignant > 50%	3	8.82%	0	0.00%		
	Malignant	26	76.47%	0	0.00%		
Lymph node metastasis	No	40	68.97%	711	95.69%	65.67	0.00
	Yes	18	31.03%	32	4.31%		
Peritoneum metastasis	No	48	82.76%	739	99.46%	116.41	0.00
	Yes	10	17.24%	4	0.54%		

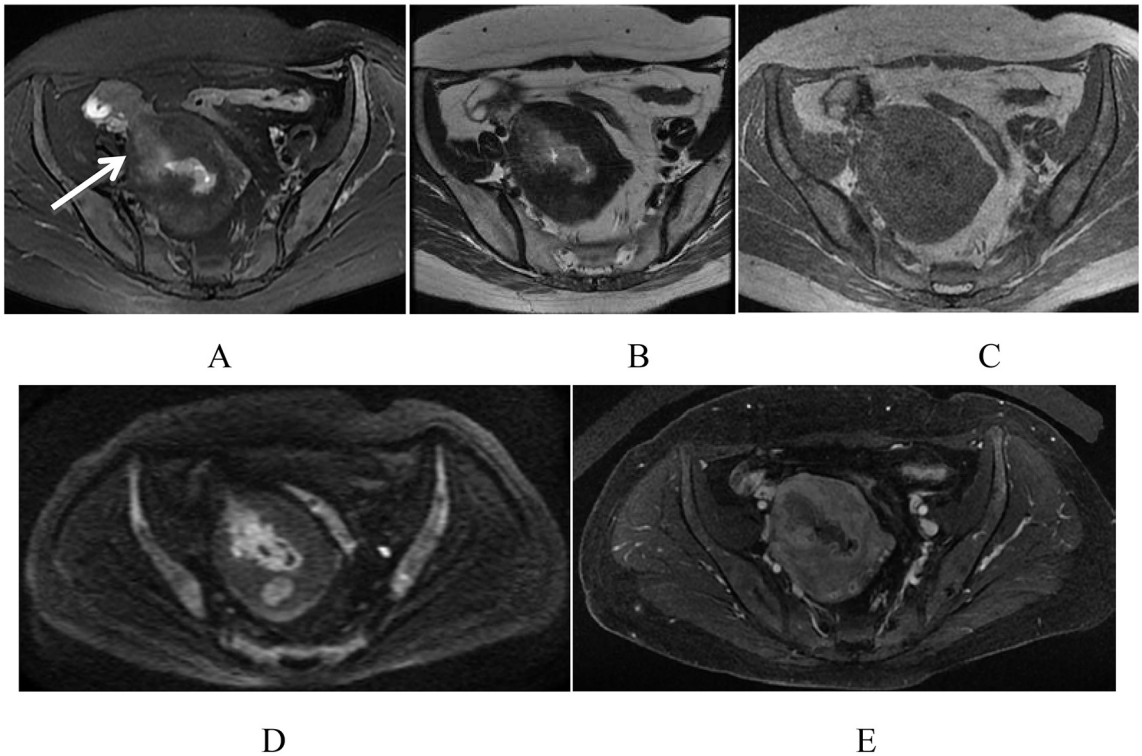

Fig. 3. A 49-year-old woman with grade 2 endometrioid cancer with right adnexal metastasis. Axial T2-weighted fat-suppressed (A) and small field of view (FOV) high resolution axial T2-weighted (B) images demonstrated an intermediate T2 signal intensity mass invading into the full thickness myometrium, right cornua uteri involvement and no boundary to the right adnexal mass (white arrow). Axial T1-weighted images (C) showed nearly iso-intensity change. Axial DWI images (D) showed restricted diffusion, and high signal intensity of the lesion. Post-enhanced LAVA axial image (E) presented tumor with less enhancement than the adjacent myometrium and enhancement of right adnexal mass.

Table 3
Cross tab of pelvic MRI in adnexal masses.

			EC-OM group	EC group	Patients (no.)
Adnexal masses	Yes		34	54	88
		Benign	0	47	
		Benign > 50%	4	6	
		Not sure	1	1	
		Malignant > 50%	3	0	
		Malignant	26	0	
	No		24	689	713
Total			58	743	801

3.4. Establishment of the decision tree model

CHAID tree demonstrated three ramifications with 4 terminal nodes, retaining 3 out of 15 initial criteria (Fig. 4): cornua uteri (images with noninvolved vs. images with involved), attachment mass (images without mass vs. images with mass), CA125 (below or equal to 29.1 U/ml or missing vs. over 29.1 U/ml). Taking the path of cut point 0–2 and the decision path of cut point 1-4-6, a total of 52 cases with ovarian malignancy could be identified prior to operation, with a sensitivity of 89.7% (52/58), a specificity of 98.4% (731/743), and an accuracy of 97.8% (783/801). The overall diagnostic accuracy (area under the ROC curve, AUC) was 0.95 (95% CI 0.91, 0.99, $P < 0.001$, Fig. 5).

4. Discussion

Endometrial carcinoma with ovarian malignancy includes ovarian metastatic carcinomas and synchronous primary carcinomas in uterus and ovaries. It was reported that, 3.1% of all endometrial carcinoma patients are combined with primary ovarian carcinoma, and this percentage was increased to 9.4% in patients under 50 years [16]. However, as for ovarian metastasis of endometrial carcinoma, different studies reported varied incidences ranging from 4.7% to 7.98% [17–19]. Our study showed that 7.2% of endometrial carcinoma patients are combined with ovarian malignancy (12.8% in patients under 50 years old). Of them, 5.7% cases are with ovarian metastasis, and 1.5% are with primary ovarian carcinoma. For ovarian metastasis of endometrial carcinoma and synchronous primary carcinomas, the common understanding regarding them is that the two had different prognosis (the latter has better prognosis and lower recurrence rate [20]), onset age and symptoms, lymph metastasis as well as degree of tissue differentiation. However, preoperative identification remained extremely difficult, and their diagnosis still depended on postoperative pathology [21–23]. In clinical practice, the two diseases did not affect the selection of surgical methods for endometrial carcinoma, and thus they were analyzed together in this study.

In recent years, the quality of life of tumor patients has drawn increasing attention. As for young patients with early-stage endometrial carcinoma, it is still controversial on whether the ovary should be retained in order to avoid the adverse effects caused by surgical menopause [6–10]. From one aspect, the FIGO criteria suggested bilateral ovariectomy to eliminate malignant lesions that are missed by preoperative imaging or intraoperative exploration [9,10]. According to the previous reports, about 0.8% of endometrial carcinoma patients had occult ovarian metastasis that can be identified only by pathological examination [24]. In our study, the rate of missed diagnosis by preoperative pelvic MRI was 48.3% when detecting combined ovarian malignancies, and intra-operative exploration identified only 3 more lesions, and there were still 43.1% of malignant carcinomas being missed. In addition, resection of bilateral ovaries could reduce the recurrence of endometrial carcinoma caused by estrogen stimulation, and also lower the risk of combined ovarian carcinoma or ovarian

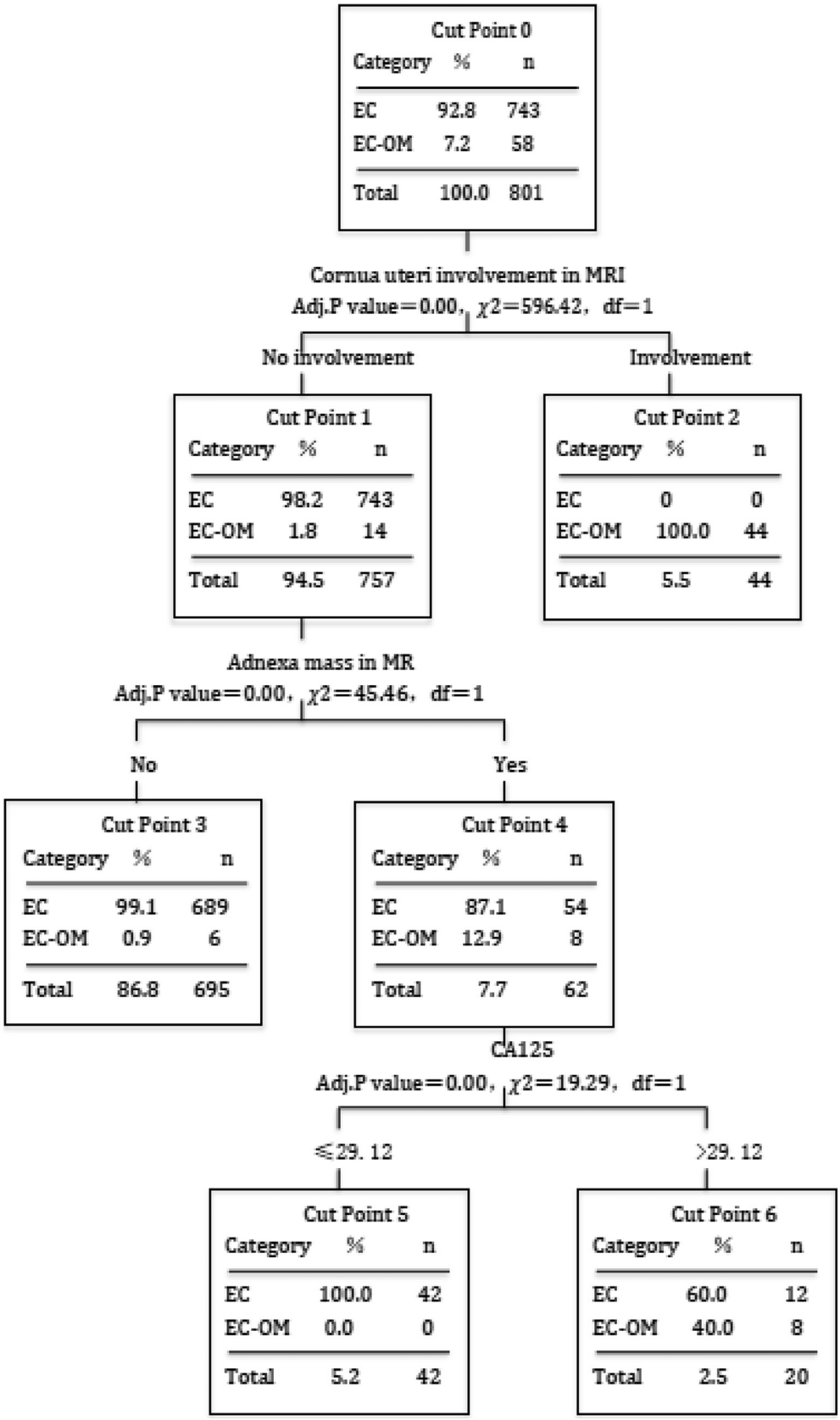

Fig. 4. Decision tree model of endometrial cancer with ovarian malignant tumor.

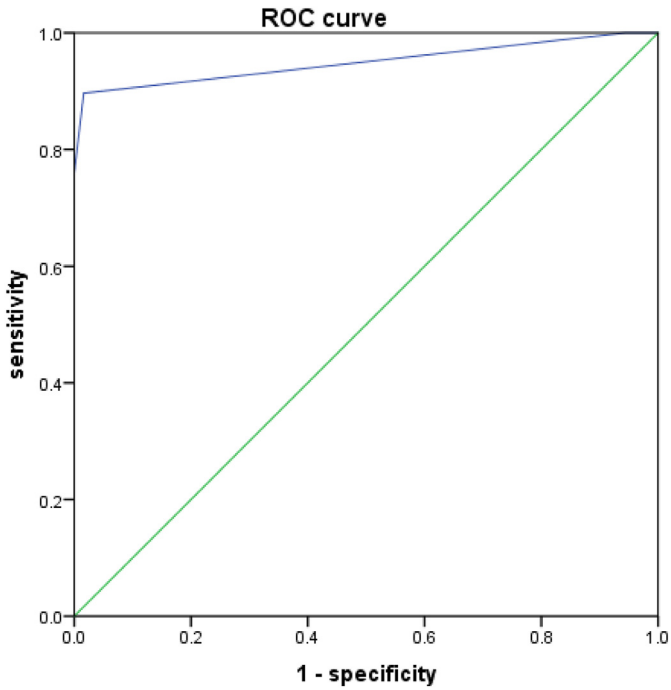

Fig. 5. ROC of the decision tree model.

metastasis [5]. However, for young patients with early stage of endometrial carcinoma, early resection of bilateral ovaries brings menopause-associated symptoms, and increases the risk of cardiovascular diseases, type II diabetes, osteoporosis, fracture, cognitive impairment, and other diseases [6]. In this study, among patients under 50 years, only 12.8% had malignant lesions in the ovary, and the remaining 87.2% were without ovarian malignancy, and performing bilateral ovariectomy would significantly affect their quality of life. Therefore, accurate assessment on the co-existed ovarian malignancy by clinical or imaging data is of great importance to guide treatment.

Our study found that for endometrial carcinoma-combined ovarian malignancy, preoperative pelvic MRI had a sensitivity of 51.7%, which was far below its specificity, and when combined with surgical exploration, the detection rate was only 56.9%. This indicates that 43.1% of the lesions are occult carcinomas that can hardly be identified by preoperative imaging or surgical exploration. We adopted decision tree method to screen clinical and imaging data of patients, and used cornual involvement, adnexal masses and serum CA125 as three indexes to guide diagnostic decision. By using this decision tree model, patients were diagnosed as endometrial carcinoma with ovarian malignancy if preoperative pelvic MRI identified cornual involvement, or MRI identified adnexal masses but not cornual involvement, and patients had a CA125 $>$ 29.1 U/m. Based on this decision-making policy, a total of 52 endometrial cancer patients were identified with ovarian malignancy. The sensitivity reached 89.7%, which significantly exceeded pelvic MRI and reduced the rate of misdiagnosis.

Our study has few limitations. As a retrospective analysis, our study included only patients from one hospital during the 6-year period, and excluded those who did not meet the inclusion criteria. This might cause bias in sample selection. Also, the 5-stage classification of adnexal masses observed during pelvic MRI was designed by us, and certain deviation might exist due to lack of a unified standard. Lastly, despite of the large size of included samples, the number of EC-OM patients was still small due to low incidence. Thus, further studies with expanded sample sizes are still needed to investigate.

In conclusion, endometrial carcinoma patients with ovarian malignancy are different from those without ovarian malignancy in serum tumor marker levels as well as preoperative pelvic MRI observations of the depth of myometrial infiltration, involvement of cervix and cornua, and conditions of pelvic lymph nodes as well as peritoneal carcinomatosis. Preoperative pelvic MRI has a high specificity, but low sensitivity in detecting ovarian malignancy. By taking cornual involvement, adnexal masses and serum CA125 as diagnostic indexes, the diagnostic accuracy of decision tree model of endometrial carcinoma with ovarian malignancy was increased. This in turn could help young patients who are willing to preserve ovaries to choose a suitable treatment plan.

Acknowledgement

We would also like to thank colleagues from the Department of Pathology for their participation in pathological examination and case reviewing.

Conflict of interest

The author declares no conflict of interest.

References

[1] Kinjyo Y, Kudaka W, Ooyama T, Inamine M, Nagai Y, Aoki Y. Ovarian preservation in young women with endometrial cancer of endometrioid histology. Acta Obstet Gynecol Scand 2015;94(4):430–4.
[2] Siegel R, Naishadham D, Jemal A. Cancer statistics, 2013. CA Cancer J Clin 2013;63(1):11–30.
[3] Chen W, Zheng R, Zhang S, Zeng H, Zuo T, Xia C, et al. Cancer incidence and mortality in China in 2013: an analysis based on urbanization level. Chin J Cancer Res 2017;29(1):1–10.
[4] Wei KR, Chen WQ, Zhang SW, Zheng RS, Wang YN, Liang ZH. Epidemiology of uterine corpus cancer in some cancer registering areas of China from 2003–2007. Zhonghua Fu Chan Ke Za Zhi 2012;47(6):445–51.
[5] Li L, Wu L, Zhang R, Zhang G, Li N, Li X, et al. Clinical analysis of ovarian preservation for stage I endometrial carcinomas in women aged 40 years and younger. Zhonghua Fu Chan Ke Za Zhi 2014;49(4):260–4.
[6] Rodriguez-Wallberg KA, Oktay K. Options on fertility preservation in female cancer patients. Cancer Treat Rev 2012;38(5):354–61.
[7] Wright JD. Take 'em or leave 'em: management of the ovaries in young women with endometrial cancer. Gynecol Oncol 2013;131(2):287–8.
[8] Group SGOCPECW, Burke WM, Orr J, Leitao M, Salom E, Gehrig P, et al. Endometrial cancer: a review and current management strategies: part II. Gynecol Oncol 2014;134(2):393–402.
[9] Sun C, Chen G, Yang Z, Jiang J, Yang X, Li N, et al. Safety of ovarian preservation in young patients with early-stage endometrial cancer: a retrospective study and meta-analysis. Fertil Steril 2013;100(3):782–7.
[10] Laurelli G, Di Vagno G, Scaffa C, Losito S, Del Giudice M, Greggi S. Conservative treatment of early endometrial cancer: preliminary results of a pilot study. Gynecol Oncol 2011;120(1):43–6.
[11] Zamani F, Goodarzi S, Hallaji F, Zamiri A, Deilami T, Malek M, et al. Diagnostic value of pelvic MRI for assessment of the depth of myometrial invasion and cervical involvement in endometrial cancer: comparison of new versus old FIGO staging. Iran J Radiol 2012;9(4):202–8.
[12] Hameeduddin A, Sahdev A. Diffusion-weighted imaging and dynamic contrast-enhanced MRI in assessing response and recurrent disease in gynaecological malignancies. Cancer Imaging 2015;15:3.
[13] Xi Y, Yuan Q, Zhang Y, Madhuranthakam AJ, Fulkerson M, Margulis V, et al. Statistical clustering of parametric maps from dynamic contrast enhanced MRI and an associated decision tree model for non-invasive tumour grading of T1b solid clear cell renal cell carcinoma. Eur Radiol 2018;28(1):124–32.
[14] Pecorelli S. Revised FIGO staging for carcinoma of the vulva, cervix, and endometrium. Int J Gynaecol Obstet 2009;105(2):103–4.
[15] Silverberg R, Kurman R, Nogales F. Tumors of the uterine corpus. In: Tavassoli F, Devilee P, editors. Tumours of the breast and female genital organs. World Health Organization classification of tumours. Pathology & genetics. Lyon: IACR Press Inc.; 2003. p. 217–58.
[16] AlHilli MM, Dowdy SC, Weaver AL, St Sauver JL, Keeney GL, Mariani A, et al. Incidence and factors associated with synchronous ovarian and endometrial cancer: a population-based case-control study. Gynecol Oncol 2012;125(1):109–13.
[17] Wang CJ, Chao A, Yang LY, Hsueh S, Huang YT, Chou HH, et al. Fertility-preserving treatment in young women with endometrial adenocarcinoma: a long-term cohort study. Int J Gynecol Cancer 2014;24(4):718–28.
[18] Lee TS, Lee JY, Kim JW, Oh S, Seong SJ, Lee JM, et al. Outcomes of ovarian preservation in a cohort of premenopausal women with early-stage endometrial cancer: a Korean Gynecologic Oncology Group study. Gynecol Oncol 2013;131(2):289–93.
[19] Wright JD, Jorge S, Tergas AI, Hou JY, Burke WM, Huang Y, et al. Utilization and outcomes of ovarian conservation in premenopausal women with endometrial cancer. Obstet Gynecol 2016;127(1):101–8.
[20] Song T, Seong SJ, Bae DS, Suh DH, Kim DY, Lee KH, et al. Synchronous primary

cancers of the endometrium and ovary in young women: a Korean gynecologic oncology group study. Gynecol Oncol 2013;131(3):624–8.
[21] Makris GM, Manousopoulou G, Battista MJ, Salloum I, Chrelias G, Chrelias C. Synchronous endometrial and ovarian carcinoma: a case series. Case Rep Oncol 2017;10(2):732–6.
[22] Wu RC, Veras E, Lin J, Gerry E, Bahadirli-Talbott A, Baras A, et al. Elucidating the pathogenesis of synchronous and metachronous tumors in a woman with endometrioid carcinomas using a whole-exome sequencing approach. Cold Spring Harb Mol Case Stud 2017;3(6).
[23] Parra-Herran C, Lerner-Ellis J, Xu B, Khalouei S, Bassiouny D, Cesari M, et al. Molecular-based classification algorithm for endometrial carcinoma categorizes ovarian endometrioid carcinoma into prognostically significant groups. Mod Pathol 2017;30(12):1748–59.
[24] Lin KY, Miller DS, Bailey AA, Andrews SJ, Kehoe SM, Richardson DL, et al. Ovarian involvement in endometrioid adenocarcinoma of uterus. Gynecol Oncol 2015;138(3):532–5.