Advances in Clinical Radiology 1 (2019) 43–54
ADVANCES IN CLINICAL RADIOLOGY

Four-Dimensional Flow Magnetic Resonance Imaging in Cardiothoracic Imaging

Bradley D. Allen, MD, MS[a,*], Nicholas S. Burris, MD[b], Pamela J. Lombardi, MD[c], Christopher J. Francois, MD[a]

[a]Department of Radiology, University of Wisconsin School of Medicine and Public Health, 600 Highland Avenue, Madison, WI 53792-3252, USA; [b]Department of Radiology, University of Michigan School of Medicine, Taubman Center, B1-141, 1500 East Medical Center Drive, Ann Arbor, MI 48109-5030, USA; [c]Department of Radiology, Northwestern University Feinberg School of Medicine, NMH/Arkes Family Pavilion Suite 800, 676 North Saint Clair Street, Chicago, IL 60611, USA

KEYWORDS

• 4D flow • Phase-contrast MRI • MR angiography • Thoracic aorta • Congenital heart disease

KEY POINTS

- Four-dimensional (4D) flow magnetic resonance imaging (MRI) provides noninvasive, volumetric hemodynamic assessment of cardiovascular disease.
- Thoracic aortic disease, pulmonary hypertension, multiple cardiomyopathies, and congenital heart disease have all been evaluated with 4D flow MRI.
- Advanced hemodynamic characterization may play a role in improved risk stratification and treatment monitoring in multiple cardiovascular disease, including aortic dissection and diastolic dysfunction.
- Decreased 4D flow scan time (now 5–8 minutes), and improved postprocessing tools, now allow for implementation in standard clinical workflows.

INTRODUCTION

Noninvasive hemodynamic assessment of the heart and great vessels plays a crucial role in diagnosis and risk stratification of patients with cardiovascular and pulmonary disease. Echocardiography, cardiac magnetic resonance imaging (CMR), and time-resolved magnetic resonance angiography (MRA) have been the primary clinical modalities used for exploring cardiovascular hemodynamics, but each modality has key limitations. Time-resolved, 3-dimensional phase-contrast magnetic resonance imaging (4D flow MRI) has been used as a research tool for several decades. This technique allows for quantitative blood flow assessment in a 3D volume covering the heart and great vessels in a single acquisition [1]. The pulse sequence has recently been developed as a product for most major MRI vendors for incorporation into clinical workflows. This review provides details on the 4D flow pulse sequence and postprocessing approaches, discusses areas of current clinical applications, and describes future applications in 4D flow imaging of the chest.

Disclosures: Dr. Burris received Scholar Grant (RSCH 1801) from Radiological Society of North America (RSNA).

*Corresponding author, *E-mail address:* bdallen@northwestern.edu

https://doi.org/10.1016/j.yacr.2019.04.002
2589-8744/19/ © 2019 Elsevier Inc. All rights reserved.

SIGNIFICANCE

Phase-Contrast Magnetic Resonance Imaging

Two-dimensional phase-contrast MRI (2D PC-MRI) is a technique for evaluating the velocity of flowing blood and is commonly used in cardiovascular MRI [2]. PC-MRI is a rapid, spoiled gradient-echo acquisition that generates phase-encoded images by first acquiring a standard magnitude image followed by a flow-sensitive acquisition and subtracting the phase component of the raw data between the 2 datasets. The flow-sensitive image incorporates a bipolar gradient along the spatial direction of interest (usually through-plane), and flowing spins along this direction acquire a phase shift that is proportional to velocity, while static spins acquire no phase shift. In cardiovascular imaging, these data are acquired in a segmented fashion that requires multiple heartbeats to create approximately 20 phases covering the cardiac cycle, which allows for assessment of velocity over time. This technique generates a time-resolved velocity map with signal intensity proportional to velocity (Fig. 1). When placing a region of interest over a vessel or structure at each cardiac phase, flow rate and net, forward, and regurgitant flow can be calculated.

Four-Dimensional Flow Magnetic Resonance Imaging

Acquisition

Four-dimensional flow MRI expands on the 2D PC-MRI approach to acquire velocity data in a volume of interest rather than a 2D plane. The 4 dimensions of "4D flow" are the velocity measurements along the 3 spatial dimensions and time (see Fig. 1). Although 2D PC-MRI is acquired in a single breath hold of 10 to 15 seconds, the increased spatial and temporal data collected with 4D flow imaging requires a free-breathing, respiratory-gated acquisition. Using current acceleration approaches, scan time is on the order of 5 to 8 minutes

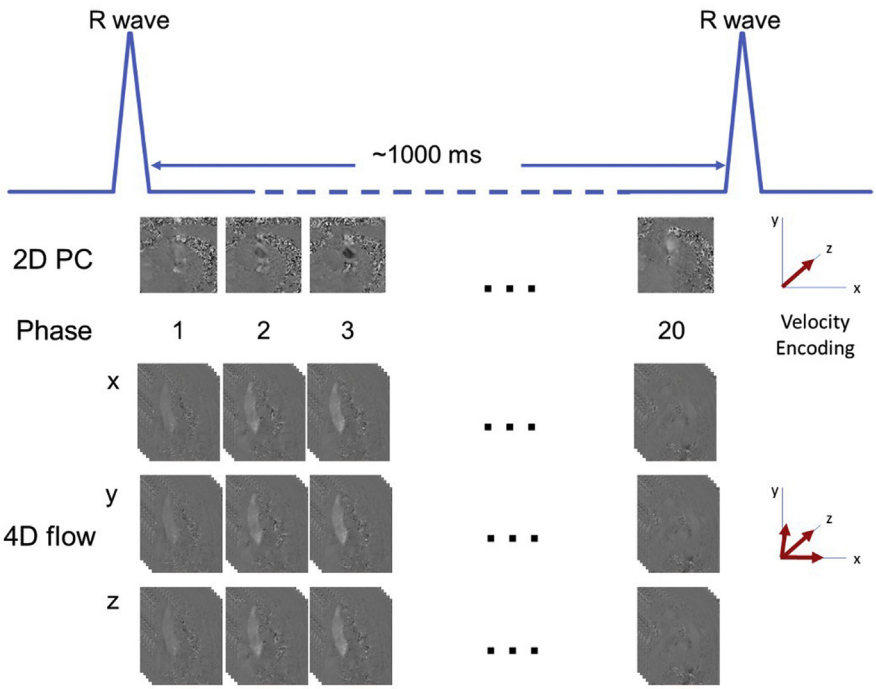

FIG. 1 Comparison of 2D PC and 4D flow MRI acquisitions. Both techniques are segmented and gated to the cardiac cycle. Two-dimensional PC requires an approximately 10-second breath hold per plane, whereas 4D flow is free-breathing and gated to the respiratory cycle. Each approach acquires approximately 20 phases between R-R intervals for a temporal resolution of approximately 40 to 50 ms. Two-dimensional PC generally only measures velocity in the through-plane direction (z-axis) of a single 2D plane. Four-dimensional flow acquires velocities in a 3D volume, and velocities are measured along each of the x, y, and z axes.

for applications in the chest. Key advantages and disadvantages of 4D flow MRI are summarized in Box 1.

Multiple user selected parameters can impact image quality and velocity measurements in PC-MRI. The most important user selected parameters are spatial resolution, temporal resolution, and velocity sensitivity. For spatial resolution, it is necessary to have at least 5 voxels covering the vessel of interest. Velocity encoding (VENC) defines the peak velocity that will be measured. Typical VENC settings are ~150 cm/s, which means that any velocity more than 150 cm/s will be aliased. The VENC should be set just above the highest expected peak velocity to limit velocity aliasing. However, setting VENC too high results in decreased velocity-to-noise ratio, which reduces sensitivity to low velocities. The Society of Cardiovascular Magnetic Resonance 4D flow CMR Consensus Statement provides thorough guidance on selecting pulse sequence parameters for most 4D flow applications [1].

Postprocessing and visualization

Postprocessing and visualization of 4D flow MRI requires specialized software, and multiple vendors now provide dedicated 4D flow postprocessing platforms. Several corrections are generally performed to optimize viewing and quantification of velocity data including Maxwell, eddy current, and gradient nonlinearity corrections, as well as phase unwrapping, which can correct small degrees of velocity aliasing within the data set [1].

There are multiple ways to visualize velocity information within the volume of interest. The easiest way to get a qualitative assessment of bulk flow and velocity is through time-resolved velocity maximal intensity projections (MIPs) that project the maximal velocity of each voxel into the viewing plane at each phase. Velocity particle tracing simulates releasing small particles into the flow field and following their path over time. Velocity streamlines allow for full-velocity field visualization at each phase of the cardiac cycle, and velocity vectors also can be overlaid to better visualize magnitude and direction of flow [1].

Velocity and flow quantification

The most powerful advantage of 4D flow MRI is the ability to assess velocity and flow data anywhere within the acquired volume retrospectively after acquisition, whereas 2D PC-MRI requires prospective plane placement at the time of acquisition. Quantification planes can be placed at the region(s) of interest in the 4D flow postprocessing software and regions of interest placed around the vessel or structure of interest in each cardiac phase. This analysis will produce flow and velocity curves similar to 2D PC-MRI analysis. Multiple studies have shown good correlation between velocity and flow data acquired with 4D flow and 2D PC-MRI [3–17]. Additional advanced postprocessing, such as wall shear stress (WSS), kinetic energy, and flow stasis, also can be derived from velocity data (Box 2) [18–22].

BOX 1
Key advantages and disadvantages of Four-Dimensional (4D) Flow Magnetic Resonance Imaging (MRI) relative to 2D Phase-Contrast (PC)-MRI

Advantages
- Retrospective analysis plane placement within acquisition volume
- Measure velocity in all 3 spatial dimensions
- Visualization of multidirectional flow features
- Assess internal consistency of flow measurements

Disadvantages
- Additional scan time of 5 to 8 minutes
- Postprocessing time of 20 to 40 minutes

Data from Dyverfeldt P, Bissell M, Barker AJ, et al. 4D flow cardiovascular magnetic resonance consensus statement. J Cardiovasc Magn Reson 2015;17(1):72.

BOX 2
Hemodynamic parameters commonly evaluated with 4D flow MRI

Standard Parameters
- Velocity
- Flow
- Regurgitant fraction

Advanced parameters
- Wall shear stress
- Kinetic energy
- Turbulent kinetic energy
- Energy dissipation
- Differential flow analysis
- Flow angle
- Flow displacement
- Pulse wave velocity

Data from Dyverfeldt P, Bissell M, Barker AJ, et al. 4D flow cardiovascular magnetic resonance consensus statement. J Cardiovasc Magn Reson 2015;17(1):72.

Artifacts and potential pitfalls

Key artifacts that can be seen in 4D flow MRI include velocity aliasing, which is related to incorrect VENC settings, spatial aliasing related to incorrect field of view, reduced Signal-to-noise ratio (SNR) related to field inhomogeneities or coil malfunction, and motion/segmentation artifacts that are often related to respiratory navigator settings or patient arrythmia. The net effect of these artifacts is a reduction in both image quality and a degradation of velocity/flow quantification. Care should be taken at the time of acquisition to minimize the impact of these artifacts within the region of interest.

Pitfalls associated with 4D flow MRI often can be avoided by clearly defining the imaging parameters of interest and optimizing the scan appropriately. In general, 4D flow should be optimized for the highest spatial and temporal resolution that is feasible given additional constraints, namely scan time. One method to evaluate overall quantitative performance of a given 4D flow acquisition is a simple check of the conservation of mass principle in various vascular territories; for example, in the absences of valvular disease, flow through aortic valve and pulmonic valve should be equivalent and the sum of flows in the left and right pulmonary artery should equal flow in the main pulmonary artery [1]. When specific indications are being pursued, trade-offs should be considered. For example, advanced hemodynamic characterization parameters, such as kinetic energy, require high temporal resolution to fully characterize the temporal changes in velocity. Evaluation of smaller vessels, as in pediatric patients, or WSS assessment require higher spatial resolution for better delineation of vessel wall boundaries and adequate resolution of the vessel lumen. Postprocessing is also a source of potential errors in 4D flow imaging. Postprocessing platforms may need to be optimized to handle acquisitions from different MRI vendors and should be discussed with the postprocessing software company at the time of purchase. In addition, various postprocessing platforms allow for various phase-offset and background correction, and inconsistent application of these techniques may impact direct comparison between quantitative parameters of interest.

Clinical Applications

Thoracic aorta disease

Aortic disease has been a leading topic of research in the field of 4D flow MRI in large part because the aorta has favorable size and velocity characteristics for MRI flow imaging, while also providing a noninvasive alternative to traditional catheter-based measurements. In healthy individuals, 4D flow has identified age-related and gender-related differences in aortic blood flow characteristics [23]. Four-dimensional flow has also been extensively used to examine abnormal blood flow in a variety of aortic pathologies (eg, aortic aneurysm, coarctation, and dissection) to better understand how abnormal blood flow contributes to disease.

Bicuspid aortic valve and related aortopathy. Bicuspid aortic valve (BAV) and associated ascending aortopathy is likely the most widely studied application of 4D flow MRI (Fig. 2) [24–36]. This disease is interesting because there is debate as to the nature of the aortopathy with some evidence supporting an associated connective tissue abnormality leading to aortic dilation, whereas other data suggest the aortic dilation is driven by the hemodynamic abnormality associated with BAV stenosis [37]. Four-dimensional flow MRI has been used to study the outflow jet features, such as velocity and outflow angle, as well as jet impingement on the aorta wall [33,34,38–40]. Guzzardi and colleagues [41] demonstrated that regions of increased WSS correspond with histopathologically confirmed extracellular matrix dysregulation and elastic fiber degeneration in the ascending aorta of patients with BAV. This study suggests that valve-related hemodynamics are a contributing factor in the development of aortopathy in patients with BAV. WSS also has been used as a marker to explore the impact of beta-blocker therapy on aortopathy progression in patients with BAV [25].

Aortic coarctation. Aortic coarctation, a congenital narrowing of the distal aortic arch, traditionally relies on invasive pressure measurement to assess severity of stenosis and inform the need for repair, with a pressure gradient greater than 20 mm Hg across the stenosis indicating the need for repair. Four-dimensional flow MRI has been used to noninvasively assess the hemodynamics consequences of coarctation by depicting disorganized post-stenotic flow patterns and providing an assessment of increased collateral flow, an indirect measure of coarctation severity, while also avoiding the variability of manual 2D PC plane placement [8]. Several studies have demonstrated a strong correlation between invasive catheter pressure measurements and noninvasive pressure estimations based on 4D flow MRI [42–45].

Pulmonary hypertension

Four-dimensional flow derived hemodynamic parameters of interest in pulmonary hypertension include

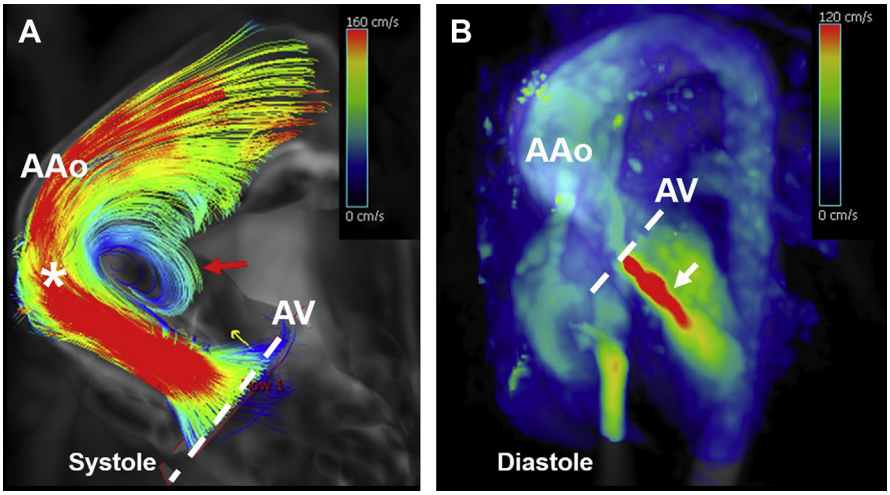

FIG. 2 Four-dimensional flow MRI (**A**) velocity streamlines and (**B**) velocity MIP in a 13-year-old boy with BAV and aortic insufficiency (AI). (**A**) A high-velocity systolic jet impinges (*asterisk*) on the anterolateral wall of the ascending aorta (AAo) with significant helical flow (*red arrow*). The mid ascending aorta is dilated to 4.0 cm (*z*-score: 9.4). The aortic valve (AV) was not stenotic and this high-velocity flow is likely secondary to flow acceleration in the setting of large-volume AI. (**B**) In diastole, the AI jet is visually striking (*white arrow*) and quantification yielded moderate AI with a regurgitant fraction = 37%.

main pulmonary artery velocity and flow, vortical and retrograde flow, pulse wave velocity, and WSS. Additional cardiac parameters that can better characterize the severity Pulmonary hypertension (PH) include tricuspid valve regurgitant fraction and right ventricle kinetic energy [46]. Using 4D flow for PH assessment, Reiter and colleagues [47] demonstrated that vortices were present in the main pulmonary artery (MPA) of patients with PH, and the period of existence of the vortex correlated with mean pulmonary artery pressures (mPAP). A follow-up study in a cohort of 145 patients with suspected PH confirmed that a vortex forms in the MPA at mPAP >16 mm Hg and the vortex duration increases linearly with increasing mPAP [48]. Schäfer and colleagues [49] demonstrated a strong negative correlation between decreased 4D flow–derived MPA WSS and increased PVR ($\rho = -0.74$, $P<.001$) and additional markers of PH, including mPAP and measures of stiffness.

Intracardiac hemodynamic evaluation

Multiple studies have investigated abnormal intracardiac flow in the setting of valvular abnormalities and cardiomyopathies. Abnormal flow patterns in 4D flow MRI have been associated with valvular abnormalities and ventricular and atrial dysfunction [50].

Aortic stenosis. Aortic valve stenosis (AS), similar to coarctation, relies on evaluation of transvalvular pressure gradients to guide clinical management. Four-dimensional flow has an emerging role in assessment of AS given its ability to avoid error related to off-axis interrogation plane leading to underestimation of flow velocities with both 2D PC and echocardiography. Unlike standard imaging techniques, elevations in viscous and turbulent energy loss can be measured among patients with AS by 4D flow and may allow for a more complete assessment of the hemodynamic and energetic stress placed on the left ventricle [51,52].

Hypertrophic cardiomyopathy. In certain variants of hypertrophic cardiomyopathy, the combination of systolic anterior motion of the mitral valve and septal thickening can dynamically obstruct the left ventricular (LV) outflow tract (LVOT) and result in increased systolic LVOT pressure gradients. Four-dimensional flow MRI has demonstrated the presence of helical flow in hypertrophic cardiomyopathy and an increased central velocity jet caused by outflow obstruction [53]. Altered flow patterns in patients with hypertrophic cardiomyopathy also were accompanied by increased peak systolic LVOT pressure gradients that correlated with increased viscous energy loss

and elevated myocardial fibrosis, as measured by extracellular volume fraction [54].

Atrial fibrillation. Risk-stratifying patients' stroke risk and need for anticoagulation in patients with atrial fibrillation (AF) can be challenging. Several groups have studied patients with AF with 4D flow [55–59]. Stasis mapping using 4D flow MRI identifies voxel-wise regions of sluggish flow in a volume of interest. In a study by Markl and colleagues [59] applying this technique in the left atrium of patients with AF, atrial 4D flow MRI demonstrated impaired but highly variable flow dynamics, stasis, and velocities in the left atrium and left atrial appendage. This study also found a large fraction of patients with AF presented with atrial flow dynamics in the normal range despite elevated clinical risk CHA_2DS_2-VASc score.

Congenital cardiovascular disease

Complex congenital heart disease (CHD) often requires comprehensive, multimodality imaging using echocardiography, computed tomography (CT), and MRI for complete preoperative characterization as well as posttreatment monitoring [60]. The complex anatomic and hemodynamic alterations associated with complex CHD can make noninvasive hemodynamic evaluation with Doppler echocardiography or 2D PC-MRI challenging. In addition to ventricular function and volume quantification, additional hemodynamic descriptors are important for surgical planning and treatment evaluation. Examples in CHD include evaluation of valvular function, the ratio of pulmonary (Qp) to systemic (Qs) blood flow (Qp:Qs) to quantify the hemodynamic impact of intracardiac and extracardiac shunts (Fig. 3), assessing blood flow to pulmonary arteries in pulmonary artery stenoses or following Fontan repair (Figs. 4 and 5), and assessing pulmonary vascular resistance [1,60]. Valverde and colleagues [13] demonstrated reduced MRI acquisition times for 4D flow MRI relative to 2D PC-MRI (12:34 minutes vs 17:28 minutes, $P<.01$) in patients with palliated single ventricle heart physiology, which is an important consideration, as most patients with CHD require MRI under anesthesia.

Shunt evaluation. The Qp:Qs ratio is a common indication for CHD hemodynamic assessment and an

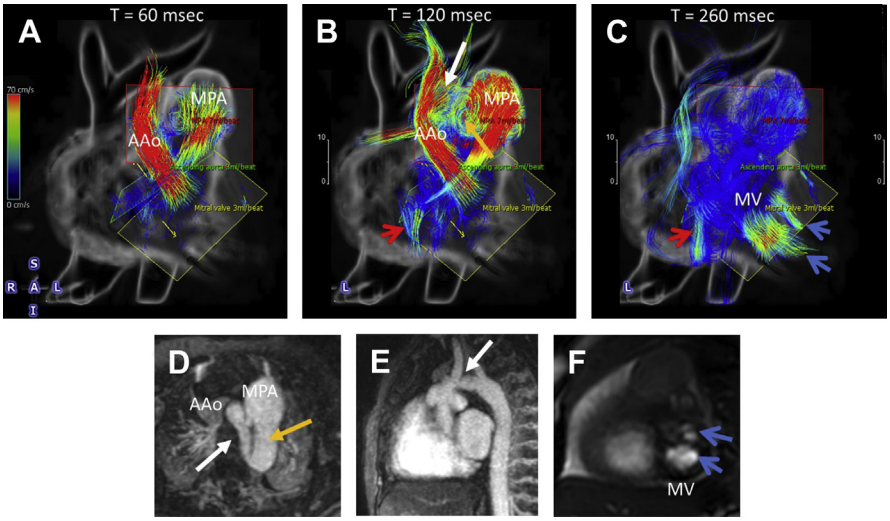

FIG. 3 Four-dimensional flow MRI in a 2-day-old boy with multiple congenital heart defects including double-outlet mitral valve (MV, *blue arrowheads*), patent foramen ovale (PFO, *red arrowheads*), hypoplastic left aortic arch (*white arrow*), and large patent ductus arteriosus (PDA, *yellow arrow*). The top row demonstrates 4D flow streamlines visualized in the anterior orientation in (**A**) early systole, (**B**) mid systole, and (**C**) mid diastole, which shows outflow through the ascending aorta (AAo) and main pulmonary artery (MPA), inferiorly directed flow just through the PFO from left atrium to right atrium, helical flow in the PDA, and 2 distinct flow jets through the MV from left atrium to LV. Contrast-enhanced MRA MIPs in the (**D**) axial and (**E**) sagittal oblique orientations. (**F**) The steady-state free precession image demonstrates the double-outlet MV en face. The RV outflow was 7 mL and the LV outflow and MV inflow were measured at 3 mL, all with 4D flow MRI. The calculated Qp:Qs ratio is 2.3, consistent with a left to right shunt.

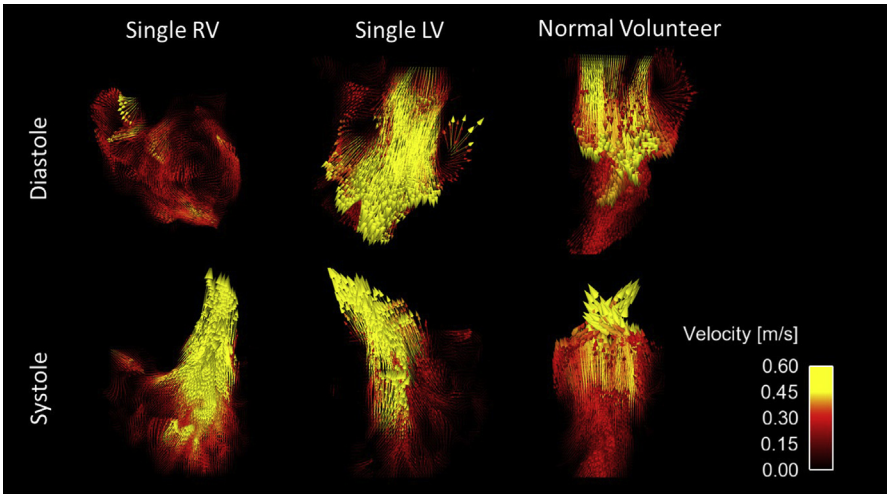

FIG. 4 Four-dimensional flow MRI intraventricular vector velocity maps in patients with CHD with single RV and single LV physiology, as well as a normal biventricular volunteer. Intraventricular velocities and flow features are unique in each patient group and may help detect changes in ventricular function in patients with single ventricle before changes in ejection fraction or volumes. (*Courtesy of* D. Rutkowski and A. Roldán-Alzate, PhD, Madison, WI.)

important parameter for assessing hemodynamic significance of shunts and need for surgical intervention. Multiple studies have shown 4D flow performs well in shunt assessment [7,61]. Chelu and colleagues [61] showed good agreement of 4D flow measured Qp:Qs with stroke volume estimates. Moreover, 20 patients with atrial septal defects (ASDs) in this study were able to have flow across the ASD directly measured with 4D flow. Direct versus Qp:Qs measurement of shunt flow showed excellent correlation ($\rho = 0.96$); however, direct measurement underestimated shunt volume by $\sim$0.6 L/min.

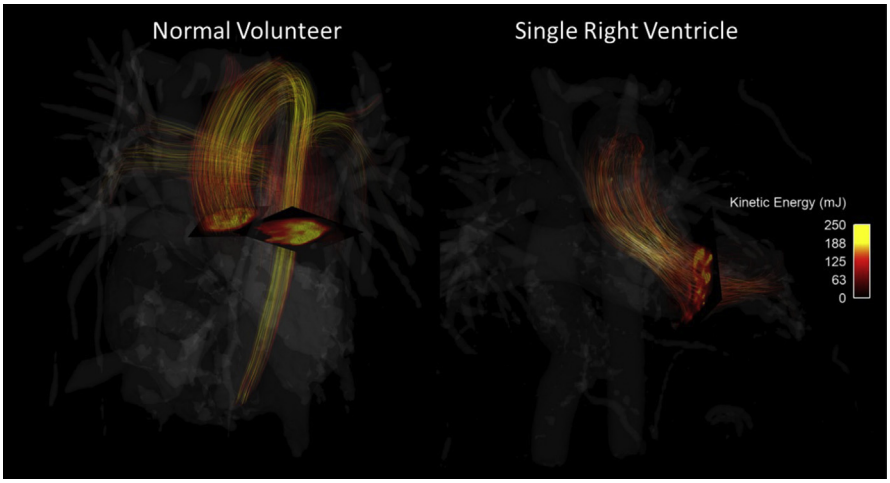

FIG. 5 Kinetic Energy (KE) streamlines during peak systole in a healthy volunteer and patients with single RV. KE can be derived from velocity and is an advance hemodynamic parameter that may be useful in characterizing flow features in many cardiovascular diseases. (*Courtesy of* D. Rutkowski and A. Roldán-Alzate, PhD, Madison, WI.)

Ventricular function. Intraventricular kinetic energy (KE) is an emerging tool measured with 4D flow that may play a role in early characterization of ventricular dysfunction in CHD. Right ventricular (RV) and LV function are important markers of risk in patients with repaired Tetralogy of Fallot (rToF) and need for reintervention. Sjoberg and colleagues [62] recently showed patients with rToF and pulmonary regurgitation (PR) with preserved LV global function have decreased LV systolic peak KE compared with controls and RV diastolic peak KE is increased in patients compared with controls related to PR. The same group has evaluated KE in patients after Fontan repair and found decreased KE in the LV of patients, which may reflect impaired ventricular filling [63], whereas Kamphuis and colleagues [64] showed ventricular energy loss due to viscous dissipation is increased in patients with Fontan repair and disproportionate to KE.

FUTURE DIRECTIONS

Aortic Dissection

Aortic dissection is an anatomically complex disease characterized by aortic blood flowing in 2 adjacent channels, the true lumen (TL) and false lumen (FL), separated by a pliable dissection membrane, which itself contains multiple holes (ie, "fenestrations") of varying size and number creating pathways for blood to enter and exit the false lumen. Although standard cross-sectional imaging techniques allow for anatomic definition, they provide minimal information about blood flow and have limited accuracy for identifying fenestrations that affect the hemodynamics of the FL [65]. Four-dimensional flow MRI is an ideal technique to evaluate dissection, as it allows for both direct visualization and quantification of blood flow in the TL and FL, as well as dynamic motion of the dissection flap throughout the cardiac cycle [66,67]. Four-dimensional flow has been shown to yield reproducible

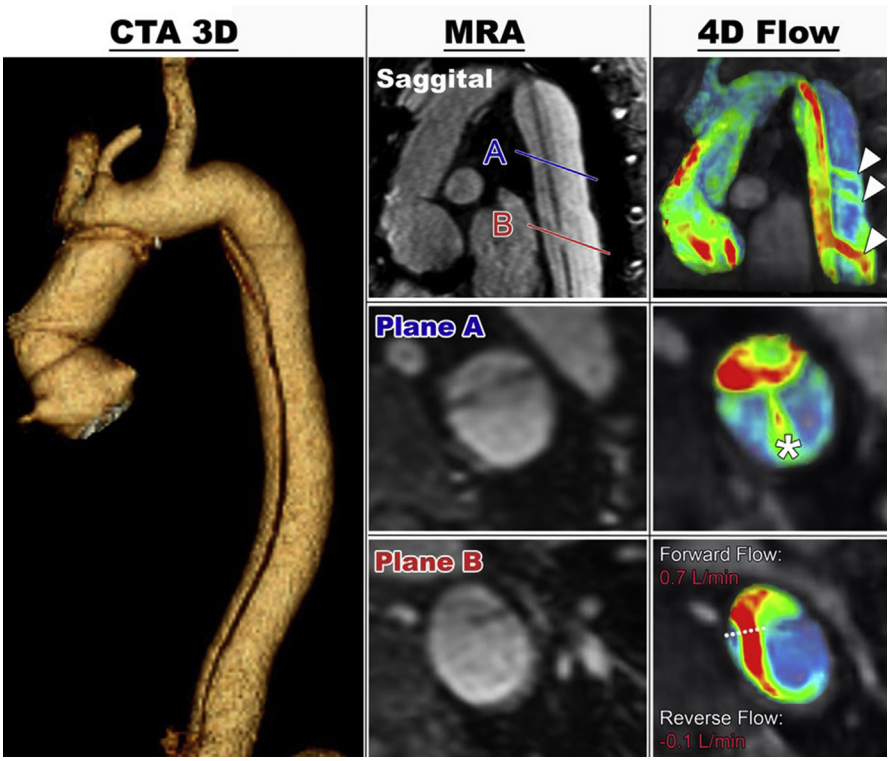

FIG. 6 Four-dimensional flow provides advanced visualization and hemodynamic characterization of patients with type B aortic dissection. Three-dimensional CTA and standard MRA provides an anatomic characterization of the patient with type B aortic dissection. Four-dimensional flow MRI allows for visualization of flow across fenestrations (asterisk, arrowheads) in the dissection flap and quantitative measurements of forward and reverse flow at these locations. This analysis may provide additional surgical planning or risk-stratification information.

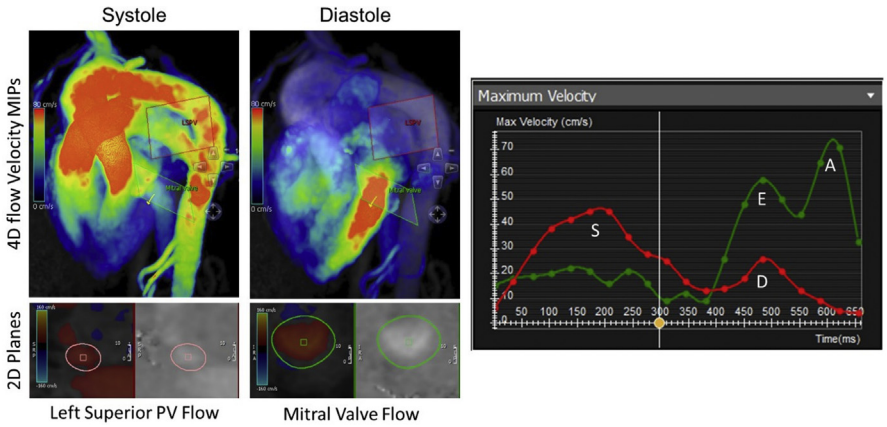

FIG. 7 Diastolic dysfunction evaluation with 4D flow MRI. Using the velocity MIPs, 2D planes can be placed at the level of the mitral valve (*green*) and left superior pulmonary vein (PV, *green*). Oval regions of interest placed over the regions of flow in these planes throughout the cardiac cycle all for quantification of the maximum velocity curves over time (*green curve*: mitral valve velocity, *red curve*: left superior PV velocity). In this patient, there is reversal of the normal ratio of E/A velocities at the mitral valve with normal systolic (S) and diastolic (D) flow ratios at the left superior PV. This combination suggests grade 1 (mild) diastolic dysfunction.

flow measurements in dissection patients compared with 2D PC [68], and dual-VENC technique can be applied to visualize both high-velocity and low-velocity blood flow features [69]. In addition, small dissection flap fenestrations that would otherwise be difficult to identify with conventional CT angiography (CTA)/MRA, can be more readily appreciated due to the flow jets that they create (Fig. 6) [70]. Four-dimensional flow has several potential uses in the clinical assessment of patients with aortic dissection, including presurgical planning and postsurgical monitoring of hemodynamics in patients undergoing endovascular repair [69] and 4D flow–based biomarkers of risk to guide patient selection for prophylactic endovascular repair. A recent 4D flow study of patients with chronic type B dissection demonstrated that the degree of retrograde flow at the proximal entry tear was significantly higher among patients with progressive FL growth, and that the entry tear regurgitant fraction was correlated with FL growth rate [71–73].

Diastolic Dysfunction

Diastolic dysfunction and heart failure with preserved ejection fraction is an increasingly recognized cause of heart failure [74]. The underlying pathophysiology results in stiffening and impaired relaxation of the myocardium with characteristic elevated LV filling pressures. Usual echocardiographic assessment of diastolic dysfunction can include measurement of the passive and active mitral inflow velocities (E and A waves, respectively) that reflect LV pressures, the mitral valve plane velocity (e′), which is a measure of myocardial relaxation, and pulmonary vein velocities that reflect left atrial pressures [75]. Characterization of the myocardium using late gadolinium enhancement or myocardial T1 and T2 mapping can help characterize ischemic and nonischemic causes of diastolic dysfunction [76]. Combining these tools with comprehensive 4D flow hemodynamic assessment including mitral valve and pulmonary vein flows and mitral valve tracking has the potential to provide a single-modality assessment of diastolic dysfunction (Fig. 7) [50]. Additional novel applications with 4D flow using flow visualization and quantification of LV KE and vorticity have all been shown to correlate with diastolic dysfunction and may provide additional markers of diagnosis and risk stratification [77–79].

SUMMARY

Four-dimensional flow MRI can provide comprehensive hemodynamic characterization of cardiovascular disease. As a result of advances in accelerated image acquisition, full covering of the heart and great vessels is now feasible in 5 to 8 minutes. Dedicated postprocessing software and high processor speeds have made real-time clinical implementation possible. As training and experience grows, the role of 4D flow MRI in cardiovascular disease diagnosis, risk stratification, and treatment monitoring will continue to increase.

REFERENCES

[1] Dyverfeldt P, Bissell M, Barker AJ, et al. 4D flow cardiovascular magnetic resonance consensus statement. J Cardiovasc Magn Reson 2015;17(1):72.

[2] Nayak KS, Nielsen JF, Bernstein MA, et al. Cardiovascular magnetic resonance phase contrast imaging. J Cardiovasc Magn Reson 2015;17:71.

[3] Brix L, Ringgaard S, Rasmusson A, et al. Three dimensional three component whole heart cardiovascular magnetic resonance velocity mapping: comparison of flow measurements from 3D and 2D acquisitions. J Cardiovasc Magn Reson 2009;11:3.

[4] Carlsson M, Toger J, Kanski M, et al. Quantification and visualization of cardiovascular 4D velocity mapping accelerated with parallel imaging or k-t BLAST: head to head comparison and validation at 1.5 T and 3 T. J Cardiovasc Magn Reson 2011;13:55.

[5] Eriksson J, Carlhall CJ, Dyverfeldt P, et al. Semi-automatic quantification of 4D left ventricular blood flow. J Cardiovasc Magn Reson 2010;12:9.

[6] Frydrychowicz A, Wieben O, Niespodzany E, et al. Quantification of thoracic blood flow using volumetric magnetic resonance imaging with radial velocity encoding: in vivo validation. Invest Radiol 2013;48(12): 819–25.

[7] Hanneman K, Sivagnanam M, Nguyen ET, et al. Magnetic resonance assessment of pulmonary (QP) to systemic (QS) flows using 4D phase-contrast imaging: pilot study comparison with standard through-plane 2D phase-contrast imaging. Acad Radiol 2014;21(8):1002–8.

[8] Hope MD, Meadows AK, Hope TA, et al. Clinical evaluation of aortic coarctation with 4D flow MR imaging. J Magn Reson Imaging 2010;31(3):711–8.

[9] Hsiao A, Alley MT, Massaband P, et al. Improved cardiovascular flow quantification with time-resolved volumetric phase-contrast MRI. Pediatr Radiol 2011;41(6): 711–20.

[10] Nordmeyer S, Riesenkampff E, Crelier G, et al. Flow-sensitive four-dimensional cine magnetic resonance imaging for offline blood flow quantification in multiple vessels: a validation study. J Magn Reson Imaging 2010;32(3): 677–83.

[11] Nordmeyer S, Riesenkampff E, Messroghli D, et al. Four-dimensional velocity-encoded magnetic resonance imaging improves blood flow quantification in patients with complex accelerated flow. J Magn Reson Imaging 2013; 37(1):208–16.

[12] Stalder AF, Russe MF, Frydrychowicz A, et al. Quantitative 2D and 3D phase contrast MRI: optimized analysis of blood flow and vessel wall parameters. Magn Reson Med 2008;60(5):1218–31.

[13] Valverde I, Nordmeyer S, Uribe S, et al. Systemic-to-pulmonary collateral flow in patients with palliated univentricular heart physiology: measurement using cardiovascular magnetic resonance 4D velocity acquisition. J Cardiovasc Magn Reson 2012;14:25.

[14] van der Hulst AE, Westenberg JJ, Kroft LJ, et al. Tetralogy of fallot: 3D velocity-encoded MR imaging for evaluation of right ventricular valve flow and diastolic function in patients after correction. Radiology 2010;256(3): 724–34.

[15] Wentland AL, Grist TM, Wieben O. Repeatability and internal consistency of abdominal 2D and 4D phase contrast MR flow measurements. Acad Radiol 2013; 20(6):699–704.

[16] Zaman A, Motwani M, Oliver JJ, et al. 3.0T, time-resolved, 3D flow-sensitive MR in the thoracic aorta: impact of k-t BLAST acceleration using 8- versus 32-channel coil arrays. J Magn Reson Imaging 2015;42(2): 495–504.

[17] Bollache E, van Ooij P, Powell A, et al. Comparison of 4D flow and 2D velocity-encoded phase contrast MRI sequences for the evaluation of aortic hemodynamics. Int J Cardiovasc Imaging 2016;32(10):1529–41.

[18] Barker AJ, Ooij P, Bandi K, et al. Viscous energy loss in the presence of abnormal aortic flow. Magn Reson Med 2014;72:620–8.

[19] Markl M, Wallis W, Brendecke S, et al. Estimation of global aortic pulse wave velocity by flow-sensitive 4D MRI. Magn Reson Med 2010;63:1575–82.

[20] Zajac J, Eriksson J, Dyverfeldt P, et al. Turbulent kinetic energy in normal and myopathic left ventricles. J Magn Reson Imaging 2015;41:1021–9.

[21] van Ooij P, Potters WV, Nederveen AJ, et al. A methodology to detect abnormal relative wall shear stress on the full surface of the thoracic aorta using four-dimensional flow MRI. Magn Reson Med 2015; 73(3):1216–27.

[22] van Ooij P, Powell AL, Potters WV, et al. Reproducibility and interobserver variability of systolic blood flow velocity and 3D wall shear stress derived from 4D flow MRI in the healthy aorta. J Magn Reson Imaging 2016;43(1): 236–48.

[23] Garcia J, van der Palen RLF, Bollache E, et al. Distribution of blood flow velocity in the normal aorta: effect of age and gender. J Magn Reson Imaging 2018;47(2):487–98.

[24] Allen BD, Barker AJ, Carr JC, et al. Time-resolved three-dimensional phase contrast MRI evaluation of bicuspid aortic valve and coarctation of the aorta. Eur Heart J Cardiovasc Imaging 2012;30:30.

[25] Allen BD, Markl M, Barker AJ, et al. Influence of beta-blocker therapy on aortic blood flow in patients with bicuspid aortic valve. Int J Cardiovasc Imaging 2016; 32(4):621–8.

[26] Barker AJ, Markl M, Burk J, et al. Bicuspid aortic valve is associated with altered wall shear stress in the ascending aorta. Circ Cardiovasc Imaging 2012;5(4):457–66.

[27] Binter C, Gotschy A, Sundermann SH, et al. Turbulent kinetic energy assessed by multipoint 4-dimensional flow magnetic resonance imaging provides additional information relative to echocardiography for the determination of aortic stenosis severity. Circ Cardiovasc Imaging 2017;10(6) [pii:e005486].

[28] Bissell MM, Hess AT, Biasiolli L, et al. Aortic dilation in bicuspid aortic valve disease: flow pattern is a major contributor and differs with valve fusion type. Circ Cardiovasc Imaging 2013;6(4):499–507.
[29] Burris NS, Dyverfeldt P, Hope MD. Ascending aortic stiffness with bicuspid aortic valve is variable and not predicted by conventional parameters in young patients. J Heart Valve Dis 2016;25(3):270–80.
[30] den Reijer PM, Sallee D 3rd, van der Velden P, et al. Hemodynamic predictors of aortic dilatation in bicuspid aortic valve by velocity-encoded cardiovascular magnetic resonance. J Cardiovasc Magn Reson 2010;12:4.
[31] Entezari P, Schnell S, Mahadevia R, et al. From unicuspid to quadricuspid: influence of aortic valve morphology on aortic three-dimensional hemodynamics. J Magn Reson Imaging 2013;21(10):24498.
[32] Garcia J, Barker AJ, Collins JD, et al. Volumetric quantification of absolute local normalized helicity in patients with bicuspid aortic valve and aortic dilatation. Magn Reson Med 2017;78(2):689–701.
[33] Hope MD, Hope TA, Meadows AK, et al. Bicuspid aortic valve: four-dimensional MR evaluation of ascending aortic systolic flow patterns. Radiology 2010;255:53–61.
[34] Mahadevia R, Barker AJ, Schnell S, et al. Bicuspid aortic cusp fusion morphology alters aortic three-dimensional outflow patterns, wall shear stress, and expression of aortopathy. Circulation 2014;129(6):673–82.
[35] Piatti F, Pirola S, Bissell M, et al. Towards the improved quantification of in vivo abnormal wall shear stresses in BAV-affected patients from 4D-flow imaging: benchmarking and application to real data. J Biomech 2017;50:93–101.
[36] van Ooij P, Potters WV, Collins J, et al. Characterization of abnormal wall shear stress using 4D flow MRI in human bicuspid aortopathy. Ann Biomed Eng 2015;43(6):1385–97.
[37] Yassine NM, Shahram JT, Body SC. Pathogenic mechanisms of bicuspid aortic valve aortopathy. Front Physiol 2017;8:687.
[38] Hope MD, Sigovan M, Wrenn SJ, et al. MRI hemodynamic markers of progressive bicuspid aortic valve-related aortic disease. J Magn Reson Imaging 2014;40(1):140–5.
[39] Garcia J, Barker AJ, Murphy I, et al. Four-dimensional flow magnetic resonance imaging-based characterization of aortic morphometry and haemodynamics: impact of age, aortic diameter, and valve morphology. Eur Heart J Cardiovasc Imaging 2016;17(8):877–84.
[40] Girdauskas E, Rouman M, Disha K, et al. Aortopathy in patients with bicuspid aortic valve stenosis: role of aortic root functional parameters. Eur J Cardiothorac Surg 2016;49(2):635–43 [discussion 643–4].
[41] Guzzardi DG, Barker AJ, van Ooij P, et al. Valve-related hemodynamics mediate human bicuspid aortopathy: insights from wall shear stress mapping. J Am Coll Cardiol 2015;66(8):892–900.
[42] Mirzaee H, Henn T, Krause MJ, et al. MRI-based computational hemodynamics in patients with aortic coarctation using the lattice Boltzmann methods: clinical validation study. J Magn Reson Imaging 2017;45(1):139–46.
[43] Riesenkampff E, Fernandes JF, Meier S, et al. Pressure fields by flow-sensitive, 4D, velocity-encoded CMR in patients with aortic coarctation. JACC Cardiovasc Imaging 2014;7(9):920–6.
[44] Goubergrits L, Riesenkampff E, Yevtushenko P, et al. MRI-based computational fluid dynamics for diagnosis and treatment prediction: clinical validation study in patients with coarctation of aorta. J Magn Reson Imaging 2015;41(4):909–16.
[45] Donati F, Figueroa CA, Smith NP, et al. Non-invasive pressure difference estimation from PC-MRI using the work-energy equation. Med Image Anal 2015;26(1):159–72.
[46] Reiter U, Reiter G, Fuchsjager M. MR phase-contrast imaging in pulmonary hypertension. Br J Radiol 2016;89(1063):20150995.
[47] Reiter G, Reiter U, Kovacs G, et al. Magnetic resonance-derived 3-dimensional blood flow patterns in the main pulmonary artery as a marker of pulmonary hypertension and a measure of elevated mean pulmonary arterial pressure. Circ Cardiovasc Imaging 2008;1(1):23–30.
[48] Reiter G, Reiter U, Kovacs G, et al. Blood flow vortices along the main pulmonary artery measured with MR imaging for diagnosis of pulmonary hypertension. Radiology 2015;275(1):71–9.
[49] Schäfer M, Kheyfets VO, Schroeder JD, et al. Main pulmonary arterial wall shear stress correlates with invasive hemodynamics and stiffness in pulmonary hypertension. Pulm Circ 2016;6(1):37–45.
[50] Crandon S, Elbaz MSM, Westenberg JJM, et al. Clinical applications of intra-cardiac four-dimensional flow cardiovascular magnetic resonance: a systematic review. Int J Cardiol 2017;249:486–93.
[51] Barker AJ, Roldan-Alzate A, Entezari P, et al. Four-dimensional flow assessment of pulmonary artery flow and wall shear stress in adult pulmonary arterial hypertension: results from two institutions. Magn Reson Med 2015;73(5):1904–13.
[52] Dyverfeldt P, Hope MD, Tseng EE, et al. Magnetic resonance measurement of turbulent kinetic energy for the estimation of irreversible pressure loss in aortic stenosis. JACC Cardiovasc Imaging 2013;6:64–71.
[53] Allen BD, Choudhury L, Barker AJ, et al. Three-dimensional haemodynamics in patients with obstructive and non-obstructive hypertrophic cardiomyopathy assessed by cardiac magnetic resonance. Eur Heart J Cardiovasc Imaging 2015;16(1):29–36.
[54] van Ooij P, Allen BD, Contaldi C, et al. 4D flow MRI and T1-mapping: assessment of altered cardiac hemodynamics and extracellular volume fraction in hypertrophic cardiomyopathy. J Magn Reson Imaging 2016;43(1):107–14.

[55] Cibis M, Lindahl TL, Ebbers T, et al. Left atrial 4D blood flow dynamics and hemostasis following electrical cardioversion of atrial fibrillation. Front Physiol 2017;8:1052.
[56] Fluckiger JUI, Goldberger JJ, Lee DC, et al. Left atrial flow velocity distribution and flow coherence using four-dimensional FLOW MRI: a pilot study investigating the impact of age and pre- and postintervention atrial fibrillation on atrial hemodynamics. J Magn Reson Imaging 2013;38(3):580–7.
[57] Lee DC, Markl M, Ng J, et al. Three-dimensional left atrial blood flow characteristics in patients with atrial fibrillation assessed by 4D flow CMR. Eur Heart J Cardiovasc Imaging 2016;17(11):1259–68.
[58] Markl M, Carr M, Ng J, et al. Assessment of left and right atrial 3D hemodynamics in patients with atrial fibrillation: a 4D flow MRI study. Int J Cardiovasc Imaging 2016;32(5):807–15.
[59] Markl M, Lee DC, Furiasse N, et al. Left atrial and left atrial appendage 4D blood flow dynamics in atrial fibrillation. Circ Cardiovasc Imaging 2016;9(9):e004984.
[60] Prakash A, Powell AJ, Geva T. Multimodality noninvasive imaging for assessment of congenital heart disease. Circ Cardiovasc Imaging 2010;3(1):112–25.
[61] Chelu RG, Horowitz M, Sucha D, et al. Evaluation of atrial septal defects with 4D flow MRI—multilevel and inter-reader reproducibility for quantification of shunt severity. MAGMA 2018;32(2):269–79.
[62] Sjoberg P, Bidhult S, Bock J, et al. Disturbed left and right ventricular kinetic energy in patients with repaired tetralogy of Fallot: pathophysiological insights using 4D-flow MRI. Eur Radiol 2018;28(10):4066–76.
[63] Sjöberg P, Heiberg E, Wingren P, et al. Decreased diastolic ventricular kinetic energy in young patients with fontan circulation demonstrated by four-dimensional cardiac magnetic resonance imaging. Pediatr Cardiol 2017;38(4):669–80.
[64] Kamphuis VP, Elbaz MSM, van den Boogaard PJ, et al. Disproportionate intraventricular viscous energy loss in Fontan patients: analysis by 4D flow MRI. Eur Heart J Cardiovasc Imaging 2019;20(3):323–33.
[65] Dillon-Murphy D, Noorani A, Nordsletten D, et al. Multi-modality image-based computational analysis of haemodynamics in aortic dissection. Biomech Model Mechanobiol 2016;15(4):857–76.
[66] Francois CJ, Markl M, Schiebler ML, et al. Four-dimensional, flow-sensitive magnetic resonance imaging of blood flow patterns in thoracic aortic dissections. J Thorac Cardiovasc Surg 2013;145(5):1359–66.
[67] Birjiniuk J, Timmins LH, Young M, et al. Pulsatile flow leads to intimal flap motion and flow reversal in an in vitro model of type B aortic dissection. Cardiovasc Eng Technol 2017;8(3):378–89.
[68] de Beaufort HW, Shah DJ, Patel AP, et al. Four-dimensional flow cardiovascular magnetic resonance in aortic dissection: assessment in an ex vivo model and preliminary clinical experience. J Thorac Cardiovasc Surg 2019;157(2):467–76.e1.
[69] Sherrah AG, Callaghan FM, Puranik R, et al. Multi-velocity encoding four-dimensional flow magnetic resonance imaging in the assessment of chronic aortic dissection. Aorta (Stamford) 2017;5(3):80–90.
[70] Allen BD, Rahsepar A, Baker AJ, et al. 4D flow MRI improves dissection flap fenestration detection in Type B aorta dissection. 27th Annual Meeting and Exhibition of the Internation Society of Magnetic Resonance in Medicine. Paris, France, June 16–21, 2018.
[71] Burris NS, Patel HJ, Hope MD. Retrograde flow in the false lumen: marker of a false lumen under stress? J Thorac Cardiovasc Surg 2019;157(2):488–91.
[72] Rudenick PA, Segers P, Pineda V, et al. False lumen flow patterns and their relation with morphological and biomechanical characteristics of chronic aortic dissections. Computational model compared with magnetic resonance imaging measurements. PLoS One 2017;12(1):e0170888.
[73] Sailer AM, van Kuijk SM, Nelemans PJ, et al. Computed tomography imaging features in acute uncomplicated Stanford type-B aortic dissection predict late adverse events. Circ Cardiovasc Imaging 2017;10(4) [pii: e005709].
[74] Krittanawong C, Kukin ML. Current management and future directions of heart failure with preserved ejection fraction: a contemporary review. Curr Treat Options Cardiovasc Med 2018;20(4):28.
[75] Nagueh SF, Smiseth OA, Appleton CP, et al. Recommendations for the evaluation of left ventricular diastolic function by echocardiography: an update from the American Society of Echocardiography and the European Association of Cardiovascular Imaging. Eur Heart J Cardiovasc Imaging 2016;17(12):1321–60.
[76] Adam RD, Shambrook J, Flett AS. The prognostic role of tissue characterisation using cardiovascular magnetic resonance in heart failure. Card Fail Rev 2017;3(2):86–96.
[77] Schafer M, Humphries S, Stenmark KR, et al. 4D-flow cardiac magnetic resonance-derived vorticity is sensitive marker of left ventricular diastolic dysfunction in patients with mild-to-moderate chronic obstructive pulmonary disease. Eur Heart J Cardiovasc Imaging 2018;19(4):415–24.
[78] Crandon S, Westenberg JJM, Swoboda PP, et al. Impact of age and diastolic function on novel, 4D flow CMR biomarkers of left ventricular blood flow kinetic energy. Sci Rep 2018;8(1):14436.
[79] Svalbring E, Fredriksson A, Eriksson J, et al. Altered diastolic flow patterns and kinetic energy in subtle left ventricular remodeling and dysfunction detected by 4D flow MRI. PLoS One 2016;11(8):e0161391.