Skeletal Radiology (2019) 48:29–45
https://doi.org/10.1007/s00256-018-3008-3

REVIEW ARTICLE

Fragility fractures of the proximal femur: review and update for radiologists

Kimia Khalatbari Kani[1] · Jack A. Porrino[2] · Hyojeong Mulcahy[3] · Felix S. Chew[3]

Received: 6 March 2018 / Revised: 10 June 2018 / Accepted: 14 June 2018 / Published online: 29 June 2018
© ISS 2018

Abstract

Proximal femoral fragility fractures are common and result in significant morbidity and mortality along with a considerable socioeconomic burden. The goals of this article are to review relevant proximal femoral anatomy together with imaging, classification, and management of proximal femoral fragility fractures, and their most common complications. Imaging plays an integral role in classification, management and follow-up of proximal femoral fragility fractures. Classification of proximal femoral fragility fractures is primarily based on anteroposterior hip radiographs. Pertinent imaging features for each category of proximal femoral fractures that would guide management are: differentiating nondisplaced from displaced femoral neck fractures, distinguishing stable from unstable intertrochanteric fractures, and determining the morphology and comminution of subtrochanteric fractures. Treatment of proximal femoral fragility fractures is primarily surgical with either arthroplasty or internal fixation. Intramedullary nailing is used in the treatment of some types of proximal femoral fragility fractures and may be associated with unique complications that become evident on postoperative follow-up radiographs.

Keywords Hip fracture · Proximal femur fracture · Fragility fracture · Femoral neck fracture · Intertrochanteric fracture · Subtrochanteric fracture · Sliding hip screw · Intramedullary nail · Cephalomedullary nail

Introduction

Osteoporosis is the most common chronic metabolic bone disease and is characterized by increased bone fragility. Osteoporosis is a silent disease until it becomes complicated by a fragility fracture [1]. Fragility fractures are fractures that result from mechanical forces that would not ordinarily result in a fracture [2]. The World Health Organization has quantified this low-energy trauma as forces equivalent to a fall from a standing height or less. Fragility fractures typically involve the proximal femur, distal radius and vertebral bodies. Proximal femoral fragility fractures typically result from a lateral ground level fall with impact on the greater trochanter.

Proximal femoral fragility fractures are common and result in significant morbidity and mortality along with considerable socioeconomic burden [3, 4]. Each year over 300,000 people are hospitalized for proximal femoral fragility fractures in the USA [5]. As the population ages, the number of proximal femoral fractures (PFFs) will continue to increase. Worldwide, by the year 2050, the total number of PFFs is expected to surpass 6 million [6].

The classification of PFFs is based on imaging (primarily radiography). Imaging also plays an integral role in management decisions and the post-surgical follow-up of PFFs. In this article, we review pertinent proximal femoral anatomy together with imaging, classification, and management of proximal femoral fragility fractures, and their most common complications.

✉ Kimia Khalatbari Kani
kimia.kani@umm.edu

[1] Department of Radiology, University of Maryland School of Medicine, Baltimore, MD, USA

[2] Department of Radiology, University of Washington, 4245 Roosevelt Way NE, Box 354755, Seattle, WA 98105, USA

[3] Radiology and Biomedical Imaging, Yale School of Medicine, New Haven, CT 98105, USA

Anatomy

Anatomical subdivisions of the proximal femur

The proximal femur is divided into the following anatomical zones, which are used to describe PFFs: femoral head, femoral neck, intertrochanteric region, and subtrochanteric region. Proximal femoral fragility

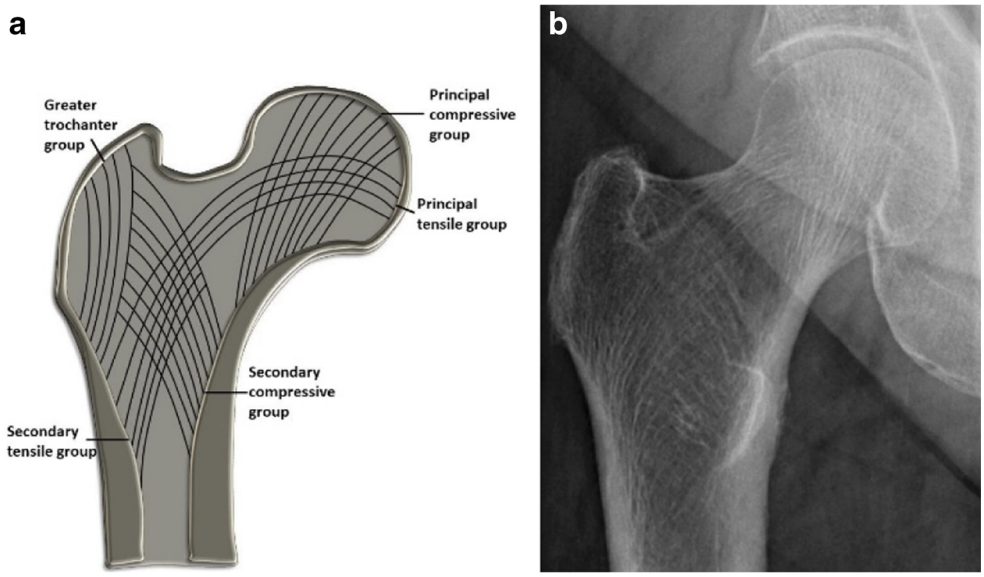

Fig. 1 Proximal femoral trabeculations. **a** Illustration and **b** anteroposterior hip radiograph in a 91-year-old woman

fractures occur most commonly in the femoral neck and intertrochanteric region (each region accounts for approximately 45% of fractures) and less commonly (approximately 10% of cases) in the subtrochanteric region [7]. Proximal femoral fractures are also categorized as intracapsular or extracapsular.

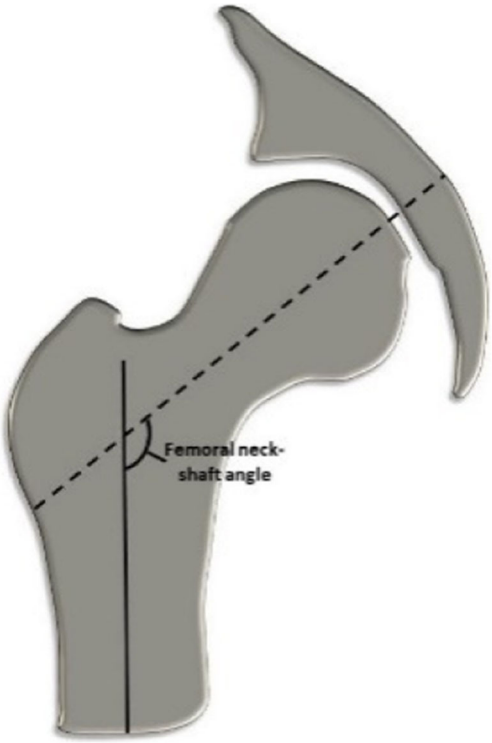

Fig. 2 Femoral neck–shaft angle and hip axis length. Normally, in adults, the femoral neck subtends an angle of 125–135° with the femoral shaft. The hip axis length (*dashed line*) is measured along the femoral neck axis and is the distance from the inferolateral aspect of the greater trochanter to the inner pelvic brim

Hip joint capsule: attachments and boundaries

The hip joint is a large ball and socket joint composed of the acetabulum, femoral head, and a portion of the femoral neck. Proximally, the hip capsule attaches to the acetabular rim (just beyond the labrum) and to the transverse acetabular ligament at the acetabular notch level [8]. Distally, the anterior hip capsule attaches

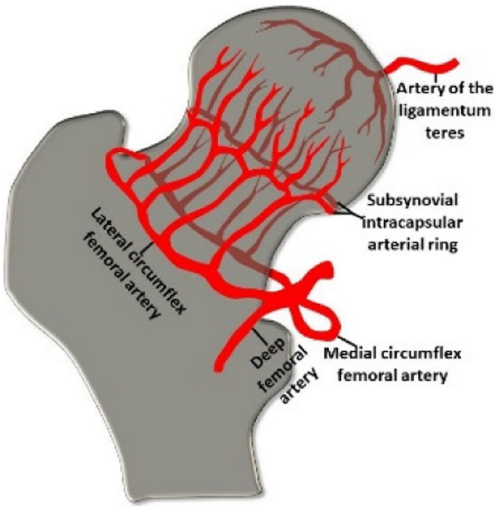

Fig. 3 Vascular supply of the femoral head. The main vascular supply of the femoral head is derived from the medial and lateral circumflex femoral arteries. These arteries form an extracapsular anastomotic ring at the base of the femoral neck. Ascending cervical capsular branches arise from this anastomotic ring and after a short distance become intracapsular either by penetrating the anterior hip capsule or extending deep to the zona orbicularis of the posterior hip capsule. Within the hip capsule, these vessels are referred to as the retinacular arteries. The retinacular arteries form a subsynovial intra-articular ring from which arterial branches extend toward and penetrate the femoral head

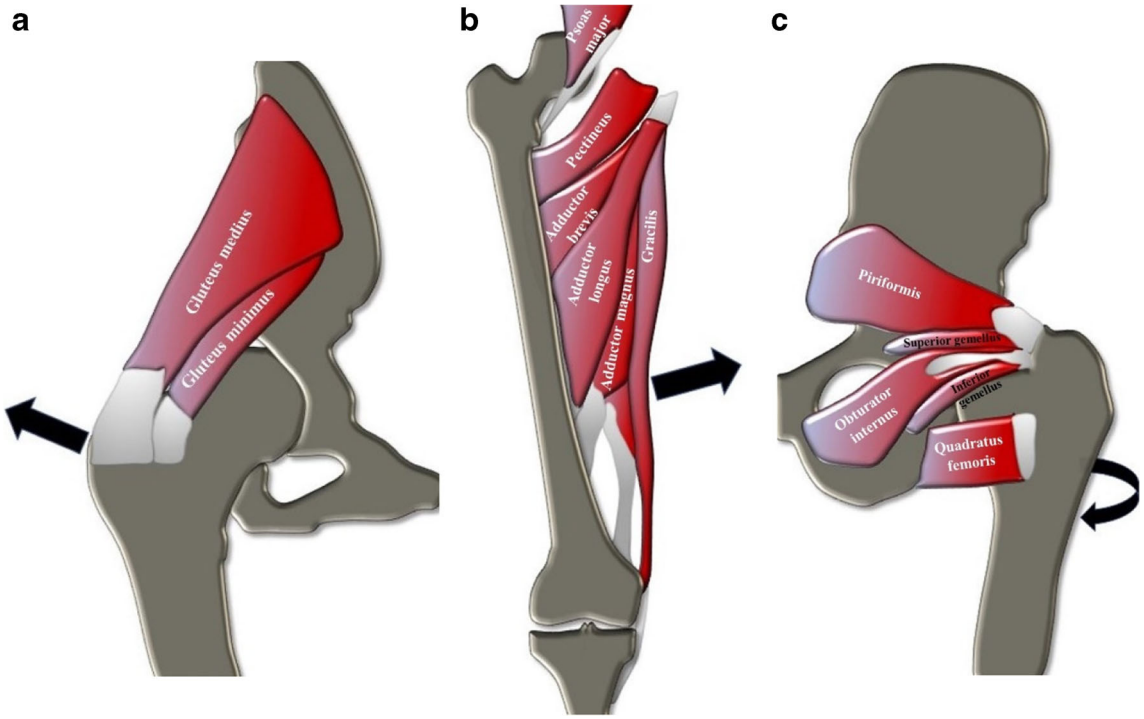

Fig. 4 Major muscle groups that can potentially displace proximal femoral fracture fragments. **a** Main hip abductors. **b** Psoas major muscle (main hip flexor) and the hip adductors (composed of the pectineus, adductor longus, brevis and magnus, and gracilis muscles). **c** The short external rotators (obturator externus muscle is not shown)

Fig. 5 Sixty-nine-year-old woman with right hip pain after a ground-level fall and negative right hip radiographs. Coronal STIR MR mage shows a nondisplaced transcervical femoral neck fracture surrounded by bone marrow edema

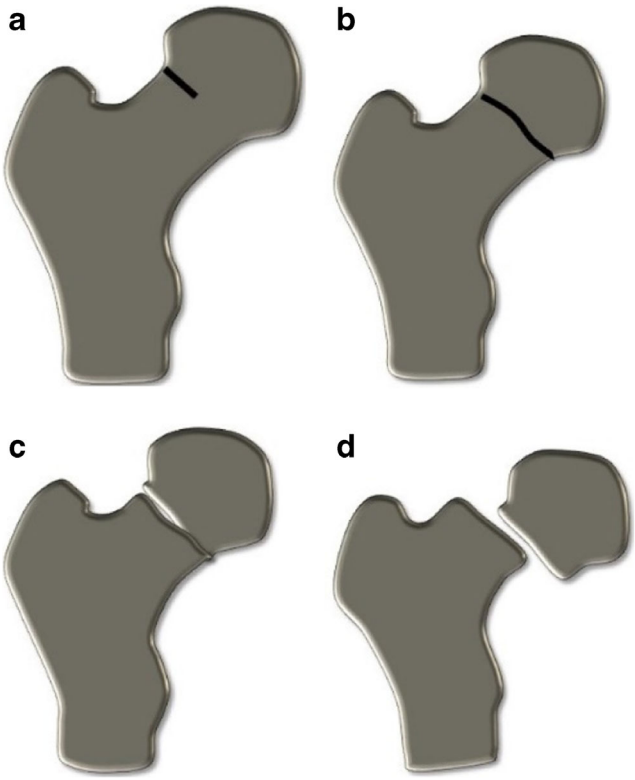

Fig. 6 Garden classification of subcapital femoral neck fractures in the elderly. **a** Incomplete and valgus-impacted fracture (stage I); **b** complete and nondisplaced fracture (stage II); **c** complete and partially displaced fracture (stage III); and **d** complete and fully displaced fracture (stage 4)

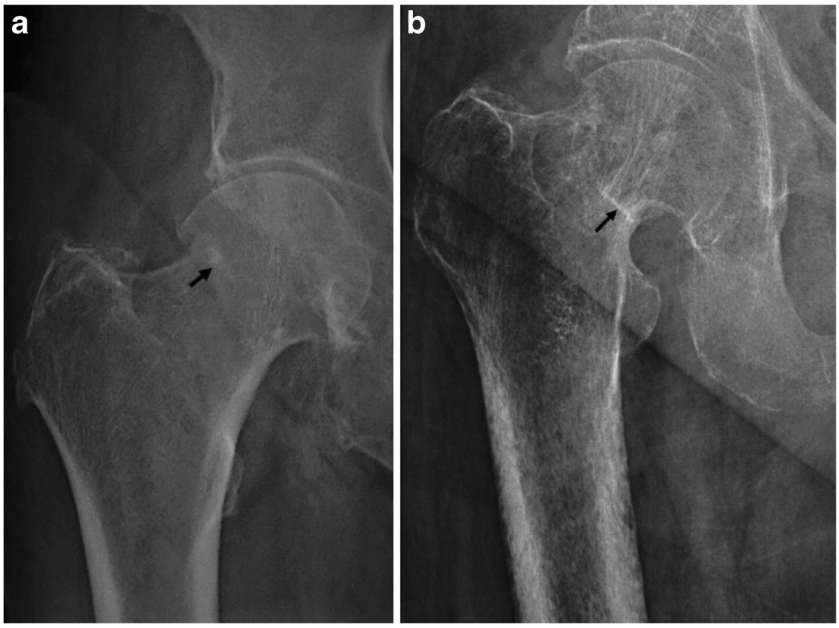

Fig. 7 Femoral neck fractures (different patients). **a** Anteroposterior hip radiograph in a 97-year-old woman after a ground-level fall demonstrates an incomplete, valgus-impacted subcapital femoral neck fracture (stage I in the Garden classification). Observe the sclerotic line (*arrow*) at site of the impacted fracture. **b** Anteroposterior hip radiograph in a 65-year-old woman after a ground-level fall shows an incomplete, varus-impacted subcapital femoral neck fracture. Observe the thin sclerotic line (*arrow*) at the level of the impacted fracture. Incomplete, varus-impacted subcapital femoral neck fractures are not included in the Garden classification

firmly to the intertrochanteric line. The posterior hip capsule is relatively thin and loose, extending halfway along the posterior aspect of the femoral neck. Distally, the posterior hip capsule does not have a direct osseous insertion and is formed by a compact set of arcuate fibers (zona orbicularis) [8]. A small synovial recess deep to the zona orbicularis demarcates the contained synovial hip cavity at this level.

Proximal femur: internal architecture and geometry

Bone strength and proximal femoral geometry contribute to proximal femoral fracture risk. Bone strength is partially determined by its internal architecture. The internal architecture of the proximal femur is primarily determined by forces generated during weight-bearing and ambulation, in addition to those resulting from surrounding muscle action [9]. This stress-

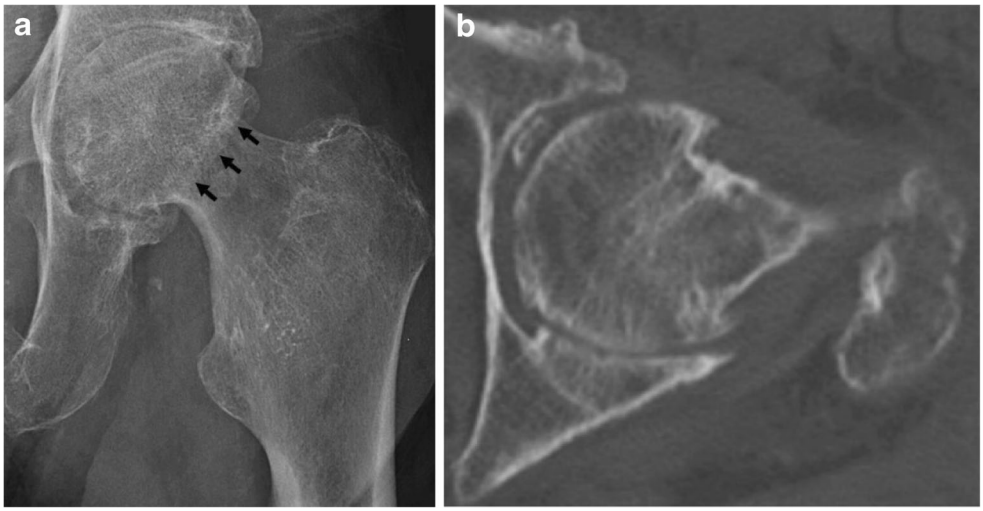

Fig. 8 Hip osteoarthritis potentially mimicking an impacted femoral neck fracture in a 78-year-old man with left hip pain after a ground-level fall. **a** Aneroposterior left hip radiograph shows severe hip osteoarthritis. Apparent band-like sclerosis (*arrows*) at the femoral head-neck junction is due to overlapping circumferential femoral head osteophytes and may be confused with an impacted femoral neck fracture. **b** On the axial hip CT scan, observe the marginal hip osteophytes that overlap the femoral head–neck junction and cause the band-like sclerotic appearance on the hip radiograph. Hip MRI (not shown) was negative for fracture

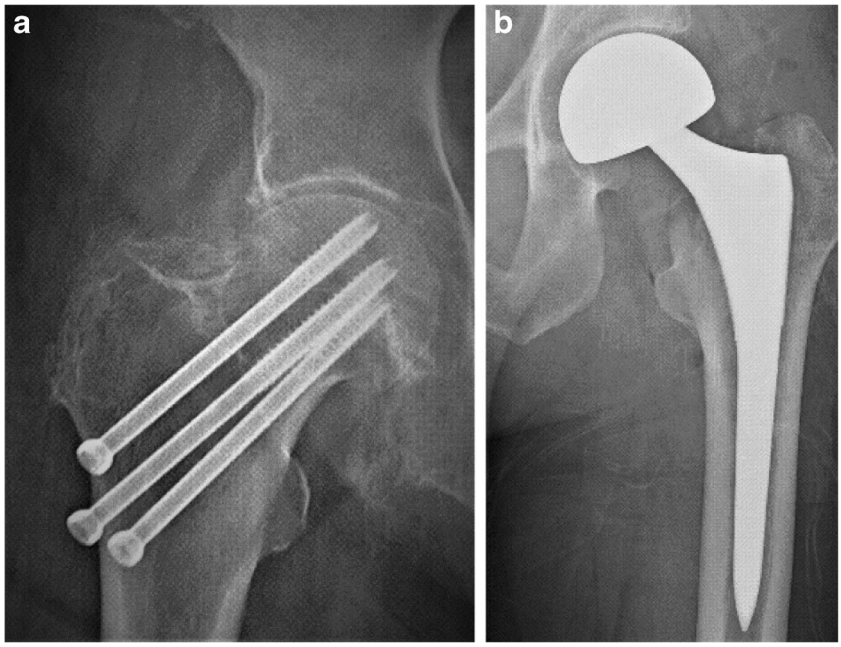

Fig. 9 Surgical management of femoral neck fractures (anteroposterior hip radiographs in different patients). **a** Three cannulated screws transfixing a femoral neck fracture in a 97-year-old woman. **b** Bipolar hemiarthroplasty performed for a displaced femoral neck fracture in a 65-year-old man

induced bone remodeling results in thickening of the cortex and osseous trabeculae at sites of greatest stress. There is thickening of the inferomedial cortex of the femoral neck. A ridge of dense bone (calcar femorale) projects from the endosteal surface of the posteromedial femoral neck deep to the lesser trochanter [10]. The proximal femoral trabeculations are arranged in groups (Fig. 1) with the vertically oriented principal compressive trabeculae transmitting most of the compressive forces during normal ambulation [11].

Geometrically, the femoral neck–shaft angle, femoral neck width, and hip axis length may influence the risk for femoral neck fractures (Fig. 2) [12–14]. Normally, in adults, the femoral neck subtends an angle of 125–135° with the femoral shaft. Femoral neck–shaft angles less than 120° and above 135–140° are termed coxa vara and coxa valga respectively. Both coxa valga and increased femoral neck width may increase the propensity to femoral neck fractures [14]. The hip axis length (Fig. 2) is measured along the femoral neck axis and is the distance from the inferolateral aspect of the greater trochanter to the inner pelvic brim [13]. A longer hip axis length is associated with a greater force being applied to the femoral neck during a fall and may increase the risk for femoral neck fractures.

Vascular supply of the femoral head

Most of the arterial supply to the femoral head is derived from the capsular vessels, with typically minimal contributions from the ligamentum teres and transcervical intramedullary arteries [4, 15–17]. The capsular vessels arise from the medial and lateral circumflex femoral arteries (Fig. 3). The medial and lateral circumflex femoral arteries most commonly originate from the deep femoral artery and form an extracapsular arterial anastomotic ring at the base of the femoral neck. Ascending cervical capsular arteries extend proximally from this arterial ring and after a short distance either penetrate the anterior hip capsule or extend deep to the zona orbicularis of the posterior hip capsule. Within the hip capsule, these arteries are referred to as retinacular arteries. The retinacular vessels are divided into four main groups: anterior, medial, lateral, and posterior. At the junction of the femoral head and neck, the retinacular vessels form a subsynovial intra-articular ring from which arterial branches extend toward and penetrate the femoral head. The most important retinacular arteries are the lateral retinacular vessels. These vessels are derived from the medial circumflex femoral artery and supply the main weight-bearing area of the femoral head [16]. The intracapsular vessels are vulnerable to injury (with subsequently increased risk of femoral head avascular necrosis) particularly in the context of displaced subcapital femoral neck fractures [16].

Muscles

In proximal femoral fractures, the major fracture fragments have the potential to be displaced by the pull of neighboring muscles, especially with weight bearing. In PFFs, the major fracture fragments are mainly displaced by the actions of the abductors, flexors, adductors, and short extensors of the hip (Fig. 4). The main hip abductors (the gluteus medius and minimus muscles) insert onto the greater trochanter. The psoas major muscle is the main hip flexor and inserts onto the lesser trochanter. The hip adductors are composed of the pectineus, adductor longus, brevis and magnus, and gracilis muscles.

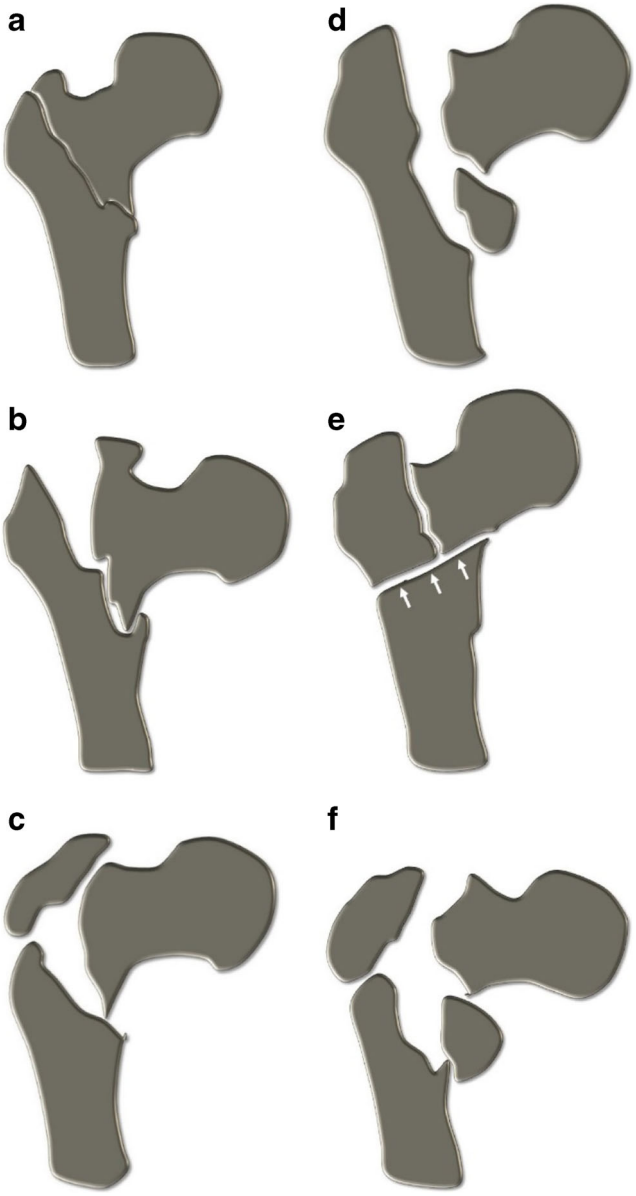

Fig. 10 Evans–Jensen classification. Intertrochanteric fractures are classified into three groups [33]. Class I includes **a** nondisplaced and **b** displaced two-fragment fractures and are considered stable. Class II comprises unstable three-fragment fractures with **c** posterolateral (greater trochanteric) or **d** posteromedial (lesser trochanteric) involvement. **e** The rare fracture with a reverse oblique fracture line (*arrows*) is considered a three-fragment fracture with greater trochanteric involvement. In contrast to the typical oblique intertrochanteric fracture line that courses parallel or roughly parallel to the intertrochanteric line, the reverse oblique fracture line is roughly perpendicular to the intertrochanteric line and courses from the superomedial to the inferolateral aspects of the intertrochanteric region. These fractures are particularly unstable, especially because the pull of the adductor muscles tends to worsen the proximal and medial displacement of the distal fracture fragment with weight-bearing. **f** Class III consists of very unstable four-fragment fractures

The short external rotators laterally rotate the femur at the level of the hip joint and are composed of the piriformis, gemellus superior, obturator internus, gemellus inferior, quadratus femoris, and the obturator externus muscles.

Imaging assessment of acute hip pain in the elderly

Radiography is the initial imaging of choice for assessment of acute hip pain. Radiographs should include an anteroposterior (AP) view of the pelvis along with AP and cross-table lateral views of the affected hip [3]. Positioning for a frog-leg lateral view of the hip may potentially cause further displacement of a proximal femoral fracture and is therefore not recommended for evaluation of suspected PFFs [18]. In the presence of subtrochanteric fractures, anteroposterior and lateral views of the ipsilateral femur are usually performed for determination of fracture extension.

Two to 10% of PFFs are occult on initial radiographs [19]. For individuals who are >50 years old or who are osteoporotic and present with acute hip pain with negative or indeterminate radiographs, MRI is recommended for further evaluation [3]. On MRI, fractures appear as a T1 hypointense line surrounded by bone marrow edema (Fig. 5). In addition to diagnosing occult fractures, MRI has the advantage of diagnosing a wide range of potential causes of hip pain. In a 10-year retrospective study of 98 patients with a clinical diagnosis of proximal femoral fracture and negative radiographs, MRI demonstrated fractures (proximal femoral or pelvic ring fractures) in 69 patients [20]. Only 17% of the scans were negative for any abnormality in this study. Early MRI can lead to early diagnosis and characterization of PFFs with initiation of definitive management. Typically, PFFs are managed with early surgery. The goal of surgery is to allow the patient to initiate immediate full weight-bearing and mobilization. Khan et al, in a systematic review, demonstrated that early surgery (within 48 h of admission) after a proximal femoral fracture leads to decreased length of hospital stay, morbidity, and mortality [21]. Although not generally indicated, unenhanced CT of the pelvis and hips may be used for identification, characterization, and preoperative planning of PFFs. CT images of the pelvis and hips may be obtained de novo or reconstructed from CT data acquired from an abdominopelvic CT scan. Dual-energy X-ray absorptiometry is recommended in all patients with a fragility fracture, to establish a baseline and determine the effectiveness of future therapy [3].

Femoral neck fractures

Classification

Several classification systems have been proposed for femoral neck fractures, none of which has been proven to be

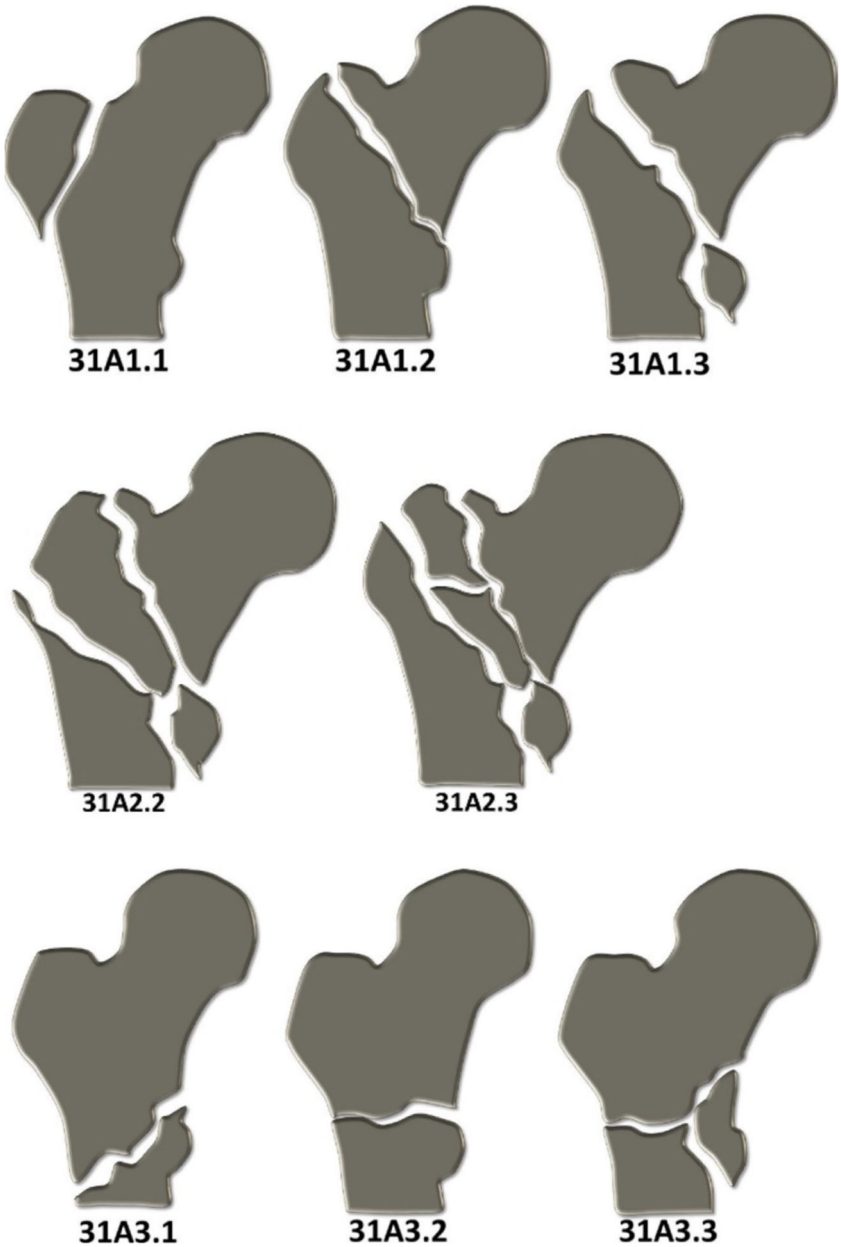

Fig. 11 The AO Foundation/Orthopaedic Trauma Association (AO/OTA) classification (second revision; 2018 compendium) [31]. Intertrochanteric fractures comprise type 31A and are divided into three groups. Group 31A1 are simple pertrochanteric fractures that do not involve the lateral wall and are subdivided into three subgroups: 31A1.1 is an isolated single trochanteric fracture (either greater or lesser trochanter); 31A1.2 is a two-part fracture, and 31A1.3 is a mildly comminuted fracture that does not involve the lateral wall. Group 31A2 comprises multifragmentary, pertrochanteric lateral wall incompetent fractures with either one (31A2.2) or two or more (31A2.3) intermediate fragments. Group 31A3 are intertrochanteric fractures with simple oblique (31A3.1), simple transverse (31A3.2), or multifragmentary or wedge-shaped (31A3.3) morphology. In contrast to groups 31A1 and 31A2 fractures, in which fractures course from proximal–lateral to distal–medial (except for the isolated single trochanteric fractures), group 31A3 fractures demonstrate either an oblique proximal–medial to distal–lateral (reverse oblique course) or transverse course

ideal. Femoral neck fractures can be classified based on location into subcapital (most fractures), transcervical, and basicervical fractures. Subcapital and transcervical fractures are intracapsular, whereas basicervical fractures may be either intra- or extracapsular. In the following discussion, the term "femoral neck fractures" refers to subcapital and transcervical femoral neck fractures (basicervical fractures are discussed separately). The anatomical location of intracapsular femoral neck fractures does not influence management or outcome; therefore, such classification is of limited value [15].

The Garden classification (Fig. 6) is the most widely used classification system in the orthopedic literature for femoral neck fractures in the elderly. This system describes four categories of subcapital fractures based on AP radiographs: incomplete and valgus-impacted (stage I; Fig. 7a), complete and nondisplaced (stage II), complete and partially displaced (stage III), and complete and fully displaced (stage 4) fractures. Several studies have found this classification system to be unreliable [22, 23]. Furthermore, the management and outcomes of both nondisplaced (stages I and II) and displaced (stages III and IV) femoral neck fractures are independent of the specific grades assigned. Therefore, a simplified two-part classification system of femoral neck fractures into nondisplaced (including minimally impacted fractures; Fig. 7) and displaced has been proposed and forms the basis of management [22, 23].

Fig. 12 Reverse oblique fracture in a 96-year-old woman. Coronal reconstructed CT image of the hip demonstrates a reverse oblique fracture. Observe that the intertrochanteric fracture line is roughly perpendicular to the intertrochanteric line. This fracture is considered a class II fracture in the Evans–Jensen classification and a 31A3.3 fracture in the AO/OTA classification. Greater trochanter fracture (*arrow*)

Fig. 13 Three-fragment intertrochanteric fracture in a 91-year-old woman. AP radiograph of the hip shows a three-fragment intertrochanteric fracture with involvement of the lesser trochanter. This fracture corresponds to a class II fracture in the Evans–Jensen classification and a 31A1.3 fracture in the AO/OTA classification

Imaging

Nondisplaced and minimally impacted femoral neck fractures may demonstrate subtle findings or be entirely missed on radiographs. The following findings may be detected on radiographs of femoral neck fractures: minimal cortical irregularity at the fracture site, sclerotic line or triangle at the site of impaction (Fig. 7), abrupt angulation of proximal femoral trabeculations at the level of the fracture, nonaligned femoral and acetabular trabeculations (in the nonfractured hip, the femoral head and acetabular trabeculations are colinear), and valgus or less commonly varus angulation of the femoral head–neck junction [24]. Femoral neck fractures may simulate hip osteophytosis and vice versa [4, 15]. Hip osteoarthritis may create a circumferential rim of osteophytosis that can be mistaken for an impacted femoral neck fracture (Fig. 8). In elderly individuals presenting with acute hip pain with negative or indeterminate radiographs, MRI is recommended for further evaluation [3]. On MRI, fractures appear as a T1 hypointense line surrounded by bone marrow edema (Fig. 5).

Management

The treatment of fragility fractures of the femoral neck in the elderly depends primarily on fracture type (nondisplaced versus displaced fractures) and the patient's activity level [7]. Internal fixation is the treatment of choice for nondisplaced femoral neck fractures [7]. Early internal fixation is critical to prevent fracture displacement, as up to 46% of fractures become secondarily displaced if not treated surgically [25]. Nonoperative treatment of nondisplaced femoral neck fractures is reserved for poor surgical candidates, for individuals who decline operative treatment, or in some patients who present late after the index injury [15]. Internal fixation is usually achieved with minimal surgical exposure using cannulated screws (Fig. 9a) [7]. Surgically treated fractures generally have a good functional outcome with a low rate of non-union [26].

The optimal treatment of displaced femoral neck fragility fractures in the elderly is arthroplasty, primarily because of the high failure rate of internal fixation with these fractures [7]. Low-demand patients are typically treated with hemiarthroplasty (either unipolar or bipolar hemiarthroplasty; Fig. 9b), whereas more active elderly patients are usually treated with total hip replacement [7]. The survival of these implants is generally good, mainly because of the limited life expectancy of the treated patient population (most patients with these prostheses do not survive long enough to develop hardware complications) [27, 28].

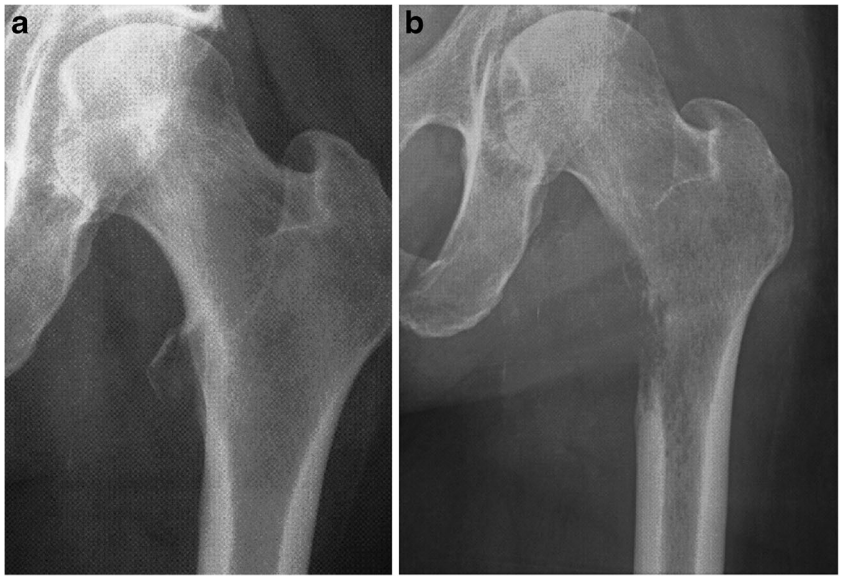

Fig. 14 Lesser trochanter fracture in a 66-year-old male. **a** Anteroposterior radiograph of the hip demonstrates a pathological fracture of the lesser trochanter (the lytic lesser trochanter lesion was due to metastatic hepatocellular carcinoma). **b** Anteroposterior hip radiograph obtained 2 months later demonstrates progressive destruction of the medial aspect of the proximal femur

Basicervical fractures

Basicervical fracture refers to a fracture through the base of the femoral neck at its junction with the intertrochanteric region [29]. These fractures may be either intracapsular or extracapsular and are unstable [30]. Basicervical fractures have been classified either with femoral neck or intertrochanteric fractures and are typically treated with internal fixation [30].

Pertrochanteric and intertrochanteric fractures

Definition

According to the AO Foundation/Orthopaedic Trauma Association (AO/OTA), trochanteric region fractures are defined as any fracture centered distal to the intertrochanteric line and proximal to a transverse line drawn along the inferior border of the lesser trochanter [31]. There is ongoing controversy regarding the proper terminology of these fractures. The most recent AO/OTA fracture and dislocation compendium suggested the term "pertrochanteric" for describing fractures that course through the trochanters and "intertrochanteric" for describing fractures between the trochanters [31]. The commonly used radiological term "intertrochanteric" is used in this article to describe fractures occurring between the greater and lesser trochanters, irrespective of the involvement of the trochanters.

Classification

Multiple and continuously evolving classification systems have been proposed for intertrochanteric fractures. None of these classifications has achieved reliable reproducible validity [31, 32]. The more commonly used classification systems use fracture location and comminution on radiographs for differentiating stable from unstable fractures [7]. Increased surgical complexity and complicated recovery are associated with unstable fracture patterns [32].

The Evans/Jensen (Fig. 10) and AO/OTA (Figs. 11, 12, and 13) classifications are the most widely used classification systems for intertrochanteric fractures [31, 33, 34]. The AO/OTA classification demonstrates greater interobserver agreement and is that most frequently referenced in recent scientific articles [34]. According to the alphanumeric AO/OTA classification, intertrochanteric fractures are classified as type 31A fractures (bone: femur: 3; location: femur, proximal end segment: 1; type: trochanteric region fracture: A). Type 31A fractures are divided into three groups (31A1, 31A2, and 31A3), with each group further subdivided into two or three subgroups. Generally, the 31A1 group is the most stable and the 31A2 and 31A3 groups are unstable (Fig. 14).

Greater trochanter fractures

Isolated greater trochanter fractures or greater trochanter fractures with incomplete intertrochanteric extension may be treated conservatively. In patients with apparent isolated greater trochanter fractures or greater trochanter fractures with incomplete intertrochanteric extension on radiographs, MRI is recommended for determination of the true extent of the fractures. Isolated greater trochanter fractures are rare. In a systematic review of 110 patients with isolated greater trochanter fractures on initial radiographs, 99 patients (90%) demonstrated intertrochanteric extension of the fractures on subsequent MRIs [3, 35]. Isolated greater trochanter fractures are usually treated conservatively with early mobilization as the major

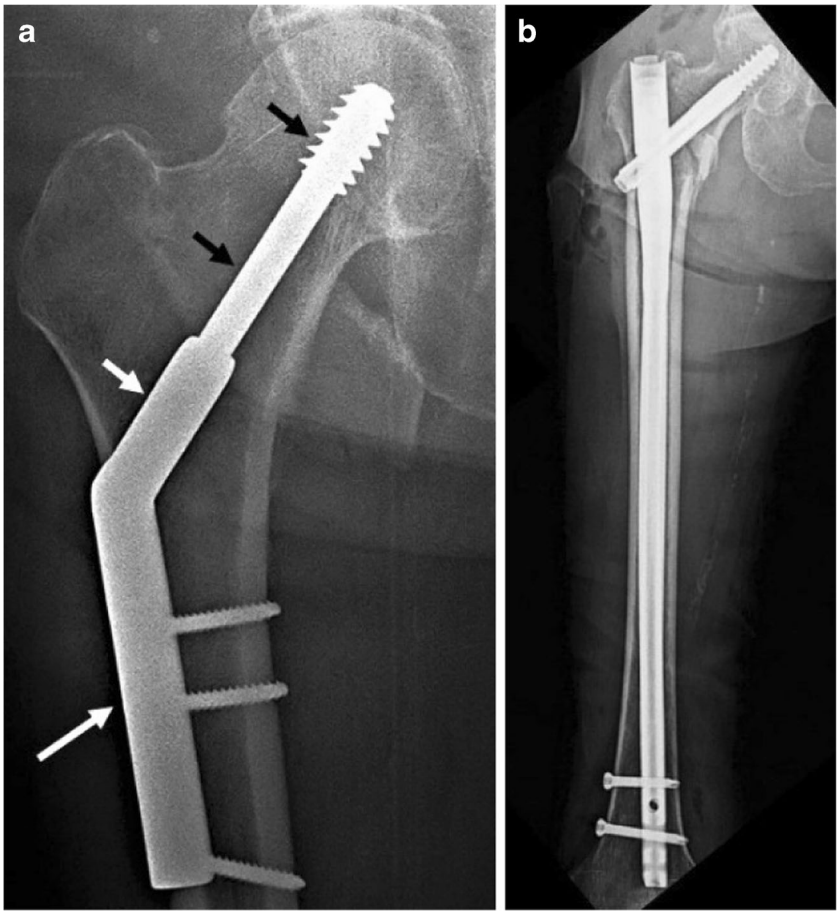

Fig. 15 Commonly used fixation hardware for intertrochanteric fractures (different patients). **a** Anteroposterior hip radiograph in a 67-year-old woman shows a sliding hip screw system (Dynamic Hip Screw; Synthes USA, Paoli, PA, USA) with a four-hole side-plate. The sliding hip screw system is composed of a large cancellous lag screw (*black arrows*) that is inserted into the head and neck of the femur. The lag screw glides in a metal sleeve (*small white arrow*) that is attached to a fixed-angle lateral side plate (*large white arrow*). The lateral side plate is fixed to the proximal femoral shaft with screws. With weight-bearing, the lag screw slides down the metal sleeve, producing dynamic compression of the fracture. **b** Intramedullary (IM) nail. Anteroposterior radiograph of the femur demonstrates a long IM nail (Cephalomedullary Nail; Zimmer, Warsaw, IN, USA) transfixing an intertrochanteric femoral neck fracture. IM nails are composed of a helical blade or one or two lag screws that are inserted in the femoral head and neck. These are interlocked with the IM nail component of the construct (depending on the design, IM nails may be inserted through the medial or lateral aspects of the greater trochanter or the piriformis fossa). The IM nail may be short or long and is transfixed distally by one or more interlocking screws

weight-bearing portion of the femur is intact [36]. There are no established guidelines for the treatment of greater trochanter fractures with incomplete intertrochanteric extension. Incomplete intertrochanteric fractures that do not cross the midline on mid-coronal MR images of the affected hip may be treated conservatively, whereas those that cross the midline tend to be treated with internal fixation [35, 37].

Lesser trochanter fractures

Isolated lesser trochanteric avulsion fractures are uncommon in the elderly. Such fractures are usually seen after minimal or no trauma, either in the setting of osteoporosis or more commonly secondary to an underlying osseous metastasis (see Fig. 16) [38, 39]. In a case series of 15 patients, James and Davies noted that 69% of atraumatic lesser trochanteric avulsions were associated with metastatic disease [40]. A thorough search for metastatic disease is recommended in cases of lesser trochanter fractures in the elderly [38, 40]. Hip MRI may be warranted in isolated lesser trochanter fractures both for evaluation of underlying osseous lesions and determination of the geographic extent of the fracture [38, 40]. Prophylactic fixation of isolated lesser trochanter fractures may be performed in some cases to avoid potential propagation of the fracture into the intertrochanteric region [38, 39].

Management

Most intertrochanteric fractures are treated with internal fixation. Internal fixation may be achieved with extramedullary

Fig. 16 Atypical insufficiency fracture in a 62-year-old woman on long-term bisphosphonate therapy. Anteroposterior hip radiograph demonstrates a noncomminuted short oblique subtrochanteric fracture

implants or intramedullary (IM) nail fixation devices (Fig. 15). Extramedullary implants include blade-plate, fixed-angle nail-plate, sliding nail plate, sliding hip screw with side plate, and locking plate fixation constructs [41]. Currently, the most commonly used extramedullary implant for intertrochanteric fracture fixation is the sliding hip screw system (Fig. 15a) [7]. Intramedullary nail fixation devices (cephalomedullary nails; Fig. 15b) consist of a variety of evolving designs and have become popular for intertrochanteric fracture fixation in more recent years [7, 42, 43]. Extramedullary sliding hip screw systems are generally recommended for stable fractures, whereas IM nail fixation devices may be used for both stable and unstable intertrochanteric fractures [42, 44]. In comparison to the extramedullary sliding hip screw system, IM nailing has theoretical advantages of being less invasive and biomechanically superior, providing a buttress to limit fracture collapse. Unstable intertrochanteric fractures have lower rates of failure and reoperation when treated with IM nailing. Arthroplasty is typically reserved for treatment of failed or complicated primary fixation of intertrochanteric fractures [41].

Subtrochanteric fractures

Definition and overview

Subtrochanteric fractures are unstable fractures that are most commonly defined as fractures that occur up to 5 cm distal to the lesser trochanter. The subtrochanteric region is an area of great stress concentration as it experiences mechanical forces several multiples of an individual's weight during weight-bearing and ambulation. In addition, the proximal and distal fracture fragments are subjected to various deforming forces due to tendon insertions. Characteristically, the proximal segment is flexed, abducted, and externally rotated secondary to the pull of the iliopsoas, gluteus medius, and short external rotators respectively. Furthermore, the distal segment is adducted by the adductor magnus and longus tendons.

Subtrochanteric fractures in the elderly may occur in two distinct settings: typical spiral fractures (with varying comminution) in osteoporotic individuals after ground-level falls and atypical insufficiency fractures occurring after no or low-energy trauma. Atypical insufficiency fractures typically occur in individuals receiving long-term bisphosphonate therapy (presumably due to impaired bone remodeling), although such fractures have occasionally been described in bisphosphonate-naive individuals [45]. These are noncomminuted, transverse or short oblique fractures (Fig. 16) that occur after no or minimal trauma, and always involve the lateral cortex (complete fractures may extend to the medial cortex) of the femoral subtrochanteric region or femoral diaphysis [43].

Classification

Multiple classification systems have been proposed for subtrochanteric fractures [46]. None of these classifications has proven ideal for guiding treatment and establishing prognosis with satisfactory inter-observer reproducibility [31, 46]. The Russell–Taylor classification divides subtrochanteric fractures based on the absence or presence of the involvement of the piriformis fossa and the lesser trochanter. This classification system was used as a guideline for implant selection during the first-generation IM nail era. As involvement of the piriformis fossa is no longer a contraindication for using the newer generation IM nails, the value of this classification system is primarily historical [46].

The classification by Seinsheimer (Figs. 17 and 18) is one of the most practical classifications, as it emphasizes the number of fracture fragments and involvement of both the medial and lateral femoral cortices [47]. The AO/OTA classification (Fig. 19) is widely used and referenced in current publications [46]. The alphanumeric AO/OTA classification considers the bone (femur = 3), location (diaphysis = 2), fracture morphology (A, B, C) and absence or presence of comminution for characterizing subtrochanteric fractures [31]. The qualifier (a) is used at the end of the alphanumeric descriptor to define the location of the fracture in the proximal third of the diaphysis. One of the disadvantages of this classification system is that subtrochanteric fractures are classified with diaphyseal fractures, which have different biomechanics [46].

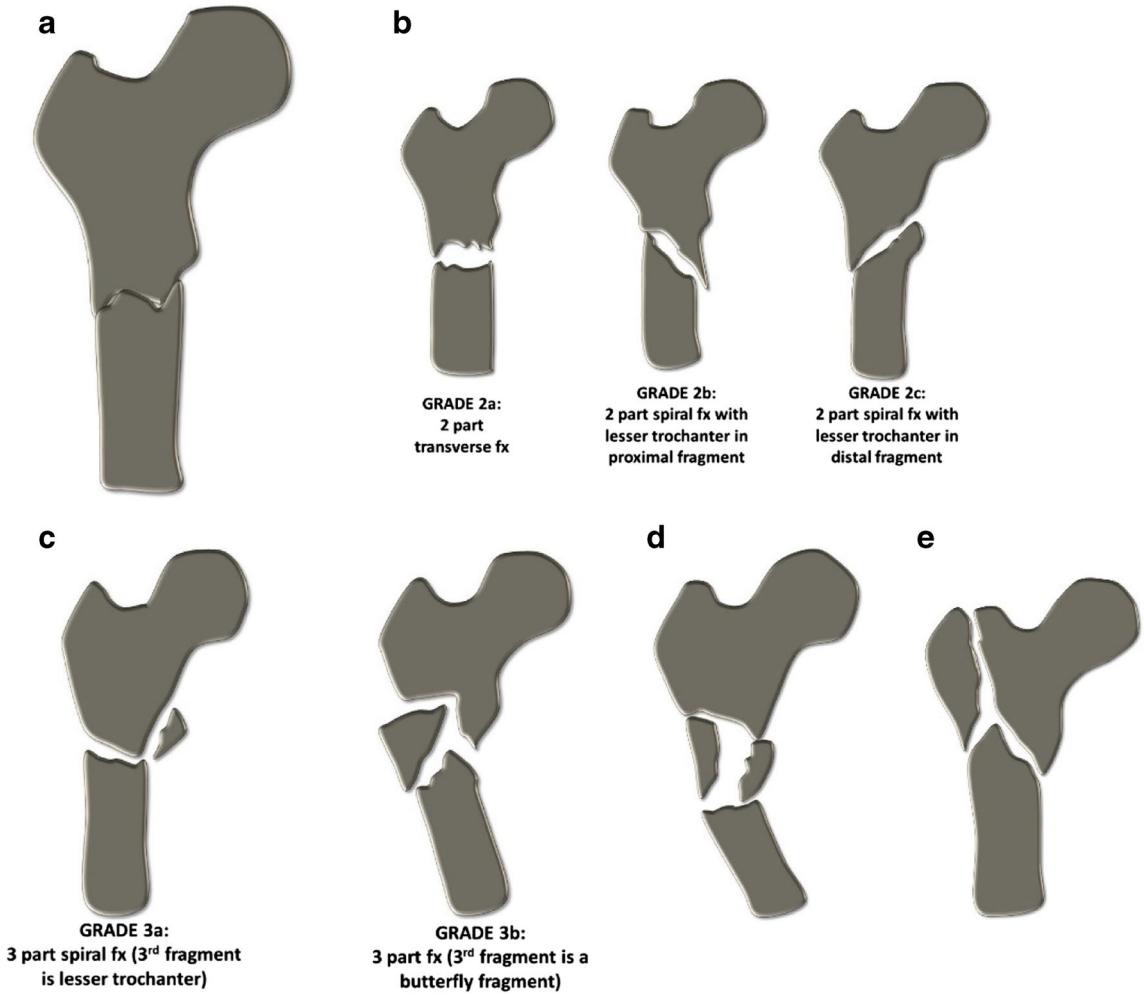

Fig. 17 The Seinsheimer classification of subtrochanteric fractures. Subtrochanteric fractures are classified into five grades. **a** Grade I is any fracture with less than 2-mm displacement. **b** Grade II is composed of two-part fractures. **c** Grade III includes three-part fractures. **d** Grade IV are fractures composed of four or more fragments. **e** Grade V comprises any fracture that extends to the greater trochanter

Management

Subtrochanteric fractures are considered unstable fractures and their treatment (including achieving and maintaining anatomical reduction) continues to be challenging [15]. These fractures are typically treated surgically with intramedullary nail fixation devices.

Complications

Proximal femoral fractures in the elderly are associated with significant morbidity and mortality. Approximately 50% of patients who live independently before a proximal femoral fracture are unable to maintain their independent lifestyles [48, 49]. The estimated 1-year mortality of PFFs is 20–30% [48, 49]. Complications of PFFs can be broadly categorized as intraoperative, post-operative general medical, and postoperative localized (occurring primarily at or near the operative bed) complications. Intraoperative complications include malreduction, inappropriate hardware component selection or hardware entry point, neurovascular injury, impingement and penetration of the anterior femoral cortex during nail insertion and iatrogenic femoral fracture [41].

Postoperative medical complications can affect a variety of systems and are seen in approximately 20% of proximal femoral fracture patients aged 60 years or older. In a prospective study of 2,448 consecutive patients, pneumonia and heart failure were the most common postoperative general medical complications [50].

Postoperative localized complications include secondary malalignment (owing to inadequate fixation or loss of fixation; Fig. 20), avascular necrosis, delayed union, nonunion (Fig. 20), malunion, hardware-related complications, periprosthetic fracture, discrepant leg length, heterotopic ossification (Fig. 20), hip osteoarthritis, and infection [4, 15, 51–54]. The frequency of some of these complications varies depending on the intracapsular versus extracapsular location of the fractures. The main complications encountered with

Fig. 18 Anteroposterior radiograph of the left hip shows a comminuted subtrochanteric fracture with extension into the greater trochanter and intertrochanteric region (grade V fracture in the Seinsheimer classification)

intracapsular fractures that are treated with internal fixation are avascular necrosis of the femoral head and non-union [4, 15]. Malunion is more frequently encountered with extracapsular fractures, although the amount of problematic deformity remains undefined [15]. Both non-union and malunion are intimately associated with hardware failure. The more common postoperative localized complications are reviewed.

Avascular necrosis

Avascular necrosis (AVN; Fig. 21) is a well-recognized complication of intracapsular PFFs treated with internal fixation owing to the intimate relationship of the femoral neck with the femoral head nourishing blood vessels and the potential of these vessels to be compromised with femoral neck fractures [51]. There is an increased risk of AVN with displaced and non-anatomically reduced fractures [52]. The reported

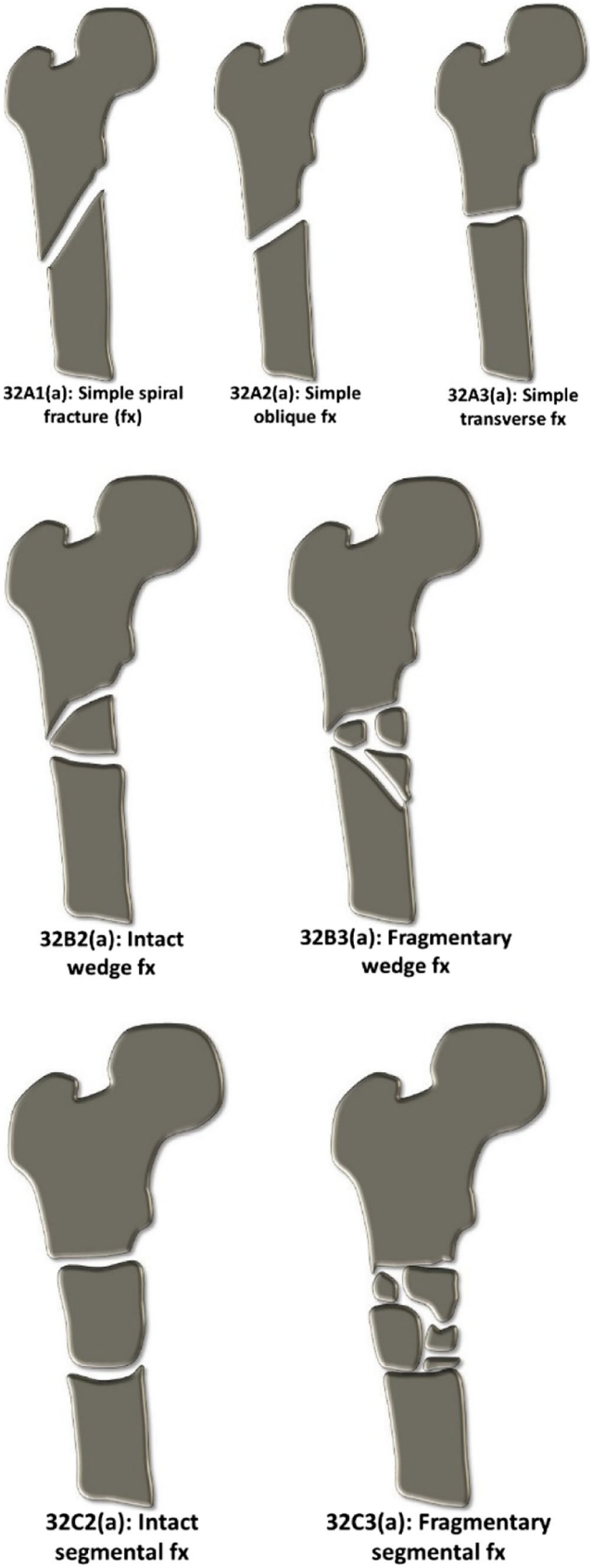

Fig. 19 The AO/OTA classification (second revision; 2018 compendium) [31]. Subtrochanteric fractures comprise type 32 with the qualifier (a) at the end of the alphanumeric descriptor to define the location of the fracture in the proximal third of the diaphysis. These fractures are divided into three groups based on fracture morphology: group A are simple, group B are wedge-shaped, and group C are multifragmentary fractures. Each group is further subdivided into two or three subgroups

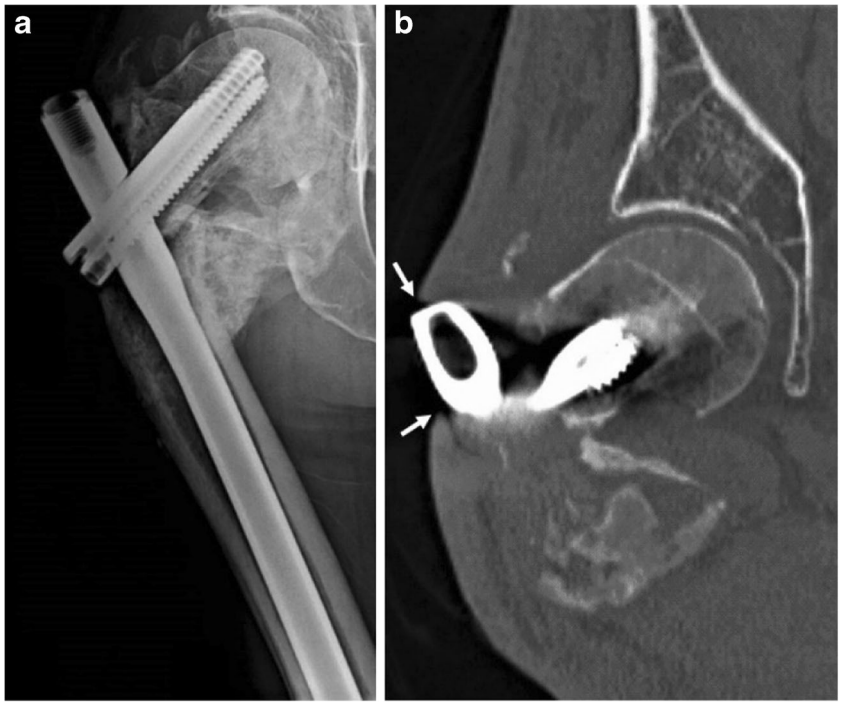

Fig. 20 Non-union and malalignment in a 55-year-old woman, 8 months after intertrochanteric fracture fixation. **a** Anteroposterior radiograph and **b** coronal reconstructed CT image of the hip show non-union and malalignment of the intertrochanteric fracture with varus deformity. Patient has a complex history of hardware infection with wound dehiscence and hardware exposure (*arrows*). Observe the exuberant heterotopic ossification medially

incidence of AVN after fixation of femoral neck fractures is 6.6% to 39% [52, 55]. There has been a decreased incidence of this complication in recent years, perhaps because of the current management paradigm of treating displaced fragility fractures of the femoral neck in the elderly with arthroplasty.

Typically, AVN is a later complication that most commonly occurs in the second year after surgery [55]. Most of the affected patients are asymptomatic or have an acceptable level of disability, and therefore do not require surgery. Arthroplasty is the treatment of choice in patients who require surgical treatment [15].

Fig. 21 Avascular necrosis of the femoral head in a 60-year-old woman, 9 years after internal fixation of a femoral neck fracture. Anteroposterior radiograph of the hip shows sclerosis and collapse of the weight-bearing surface of the femoral head indicative of avascular necrosis

Non-union

Non-union is defined as a lack of radiographic evidence of union 6 months after the fracture (Fig. 20) [53]. Affected patients usually present with pain on weight-bearing 3 months after fixation. Non-union is most frequently observed and reported in up to 30% of femoral neck fractures treated with internal fixation [54]. An absence of the intracapsular periosteum (which is a major contributor to normal fracture healing) predisposes to non-union in femoral neck fractures [51]. Non-union is intimately associated with fixation failure and varus collapse of the fracture, which together constitute the main mode of failure of femoral neck fractures treated with internal fixation [15]. Non-union is more commonly seen in initially displaced fractures, fractures with posterior comminution and poorly reduced fractures [54]. Typically, non-union of femoral neck fractures in the elderly is treated with arthroplasty [15].

Hardware-related complications

A comprehensive review of complications of implants used in the treatment of proximal femoral fractures is beyond the scope of this manuscript, and only unique hardware complications are reviewed.

Fig. 22 Z-effect with lag screw cutout in a 65-year-old woman. Anteroposterior hip radiograph demonstrates IM nailing of an intertrochanteric fracture. There is migration of the two femoral head lag screws in opposite directions and cutout of the femoral head by the superior screw and lateral migration (back out) of the inferior screw

One of the most frequently encountered complications for both extramedullary sliding hip screws and IM nails is the loss of construct stability with varus collapse at the fracture level and medial migration of the lag screw [15, 56]. This may ultimately lead to medial extrusion (cutout; Fig. 22) of the lag screw from the femoral head. Lag screw cutout is the most frequently reported mode of mechanical failure of internal fixation devices used for the treatment of intertrochanteric fractures, with variably reported rates of between 0 and 16% [56]. The most important predictors of lag screw cutout are suboptimal fracture reduction, substandard femoral head lag screw position, unstable fracture pattern, and intramedullary implant design [56, 57].

Lag screw cutout may occur in the context of the z-effect (Fig. 22). Z-effect and reverse z-effect are well-described unique patterns of hardware failure that are seen in intertrochanteric fractures treated with IM nails containing two femoral head lag screws [41, 58]. These terms are used to describe the migration of the femoral head lag screws in opposite directions with consequent varus collapse of the fracture. The Z-effect (Fig. 22) involves the lateral migration of the inferior screw and cutout of the femoral head by the superior screw. In the reverse Z-effect the opposite occurs: lateral migration of the superior screw along with medial migration of the inferior screw. Suboptimal fracture reduction, severe medial comminution, inappropriate entry point of the IM nail and poor bone quality may predispose to this complication [58].

Conclusion

Imaging plays an integral role in the classification, management, and follow-up of PFFs. Classification of proximal femoral fragility fractures is primarily based on anteroposterior hip radiographs. Pertinent imaging features for each category of proximal femoral fractures that would guide management are: differentiating nondisplaced from displaced femoral neck fractures, distinguishing stable from unstable intertrochanteric fractures and determining the morphology and comminution of subtrochanteric fractures. Treatment of proximal femoral fragility fractures in the elderly is primarily surgical, with arthroplasty typically performed for displaced femoral neck fractures and internal fixation for nondisplaced femoral neck, intertrochanteric, and subtrochanteric fractures. IM nailing is used in the treatment of some types of proximal femoral fractures and may be associated with unique complications that become evident on postoperative follow-up radiographs.

Compliance with ethical standards

Conflicts of interest The authors declare that they have no conflicts of interest.

References

1. Sozen T, Ozisik L, Basaran NC. An overview and management of osteoporosis. Eur J Rheumatol. 2017;4(1):46–56.
2. Kanis JA, Oden A, Johnell O, Jonsson B, de Laet C, Dawson A. The burden of osteoporotic fractures: a method for setting intervention thresholds. Osteoporos Int. 2001;12(5):417–27.
3. Ward RJ, Weissman BN, Kransdorf MJ, Adler R, Appel M, Bancroft LW, et al. ACR appropriateness criteria acute hip pain-suspected fracture. J Am Coll Radiol. 2014;11(2):114–20.
4. Sheehan SE, Shyu JY, Weaver MJ, Sodickson AD, Khurana B. Proximal femoral fractures: what the orthopedic surgeon wants to know. Radiographics. 2015;35(5):1563–84.
5. Center for Disease Control and Prevention. Hip fractures among older adults. https://www.cdc.gov/homeandrecreationalsafety/falls/adulthipfx.html. Published September 2016. Accessed: April 2018.
6. Kannus P, Parkkari J, Sievanen H, Heinonen A, Vuori I, Jarvinen M. Epidemiology of hip fractures. Bone. 1996;18(1 Suppl):57S–63S.
7. Mears SC. Classification and surgical approaches to hip fractures for nonsurgeons. Clin Geriatr Med. 2014;30(2):229–41.
8. Wagner FV, Negrao JR, Campos J, Ward SR, Haghighi P, Trudell DJ, et al. Capsular ligaments of the hip: anatomic, histologic, and

positional study in cadaveric specimens with MR arthrography. Radiology. 2012;263(1):189–98.
9. Kerr R, Resnick D, Pineda C. CT analysis of proximal femoral trabecular pattern simulating skeletal pathology. J Comput Assist Tomogr. 1988;12(2):227–30.
10. Tetsunaga T, Fujiwara K, Endo H, Tetsunaga T, Shiota N, Sato T, et al. Calcar femorale in patients with osteoarthritis of the hip secondary to developmental dysplasia. Clin Orthop Surg. 2017;9(4):413–9.
11. Stiehl JB, Jacobson D, Carrera G. Morphological analysis of the proximal femur using quantitative computed tomography. Int Orthop. 2007;31(3):287–92.
12. Gnudi S, Sitta E, Pignotti E. Prediction of incident hip fracture by femoral neck bone mineral density and neck-shaft angle: a 5-year longitudinal study in post-menopausal females. Br J Radiol. 2012;85(1016):e467–73.
13. Leslie WD, Lix LM, Morin SN, Johansson H, Oden A, McCloskey EV, et al. Hip axis length is a FRAX- and bone density-independent risk factor for hip fracture in women. J Clin Endocrinol Metab. 2015;100(5):2063–70.
14. Alonso CG, Curiel MD, Carranza FH, Cano RP, Perez AD. Femoral bone mineral density, neck-shaft angle and mean femoral neck width as predictors of hip fracture in men and women. multicenter project for research in osteoporosis. Osteoporos Int. 2000;11(8):714–20.
15. Court-Brown C, Heckman J, McKee M, McQueen M, Ricci W, Torentta P, editors. Rockwood and Green's fractures in adults: volume 2. 8th ed. Alphen aan den Rijn: Wolters Kluwer; 2015.
16. Claffey TJ. Avascular necrosis of the femoral head. An anatomical study. J Bone Joint Surg (Br). 1960;42-B:802–9.
17. Sevitt S, Thompson RG. The distribution and anastomoses of arteries supplying the head and neck of the femur. J Bone Joint Surg (Br). 1965;47:560–73.
18. Koval KJ, Zuckerman JD. Hip fractures. I. Overview and evaluation and treatment of femoral-neck fractures. J Am Acad Orthop Surg. 1994;2(3):141–9.
19. Lubovsky O, Liebergall M, Mattan Y, Weil Y, Mosheiff R. Early diagnosis of occult hip fractures MRI versus CT scan. Injury. 2005;36(6):788–92.
20. Sankey RA, Turner J, Lee J, Healy J, Gibbons CE. The use of MRI to detect occult fractures of the proximal femur: a study of 102 consecutive cases over a ten-year period. J Bone Joint Surg (Br). 2009;91(8):1064–8.
21. Khan SK, Kalra S, Khanna A, Thiruvengada MM, Parker MJ. Timing of surgery for hip fractures: a systematic review of 52 published studies involving 291,413 patients. Injury. 2009;40(7):692–7.
22. Van Embden D, Rhemrev SJ, Genelin F, Meylaerts SA, Roukema GR. The reliability of a simplified garden classification for intracapsular hip fractures. Orthop Traumatol Surg Res. 2012;98(4):405–8.
23. Thomsen NO, Jensen CM, Skovgaard N, Pedersen MS, Pallesen P, Soe-Nielsen NH, et al. Observer variation in the radiographic classification of fractures of the neck of the femur using garden's system. Int Orthop. 1996;20(5):326–9.
24. Blankenbaker D, Davis K. Diagnostic imaging: musculoskeletal trauma e-book. 2nd ed. Amsterdam: Elsevier Health Sciences; 2016.
25. Verheyen CC, Smulders TC, van Walsum AD. High secondary displacement rate in the conservative treatment of impacted femoral neck fractures in 105 patients. Arch Orthop Trauma Surg. 2005;125(3):166–8.
26. Conn KS, Parker MJ. Undisplaced intracapsular hip fractures: results of internal fixation in 375 patients. Clin Orthop Relat Res. 2004;(421):249–54.
27. Tarasevicius S, Jermolajevas V, Tarasevicius R, Zegunis V, Smailys A, Kalesinskas RJ. Total hip replacement for the treatment of femoral neck fractures. Long-term results. Medicina (Kaunas). 2005;41(6):465–9.
28. Haidukewych GJ, Israel TA, Berry DJ. Long-term survivorship of cemented bipolar hemiarthroplasty for fracture of the femoral neck. Clin Orthop Relat Res. 2002;(403):118–26.
29. Blair B, Koval KJ, Kummer F, Zuckerman JD. Basicervical fractures of the proximal femur. A biomechanical study of 3 internal fixation techniques. Clin Orthop Relat Res. 1994;(306):256–63.
30. Massoud EI. Fixation of basicervical and related fractures. Int Orthop. 2010;34(4):577–82.
31. Fracture and Dislocation Classification Compendium-2018: International Comprehensive Classification of Fractures and Dislocations Committee. https://classification.aoeducation.org/compendium.html.Published January 2018. Accessed April 2018.
32. Russel T. Intertrochanteric fractures of the hip In: Court-Brown C, Heckman J, McQueen M, Ricci W, Tornetta P, editors. Rockwood and Green's fractures in adults. 8th ed. Philadelphia: Lippincott Williams & Wilkins; 2015.
33. Jensen JS. Classification of trochanteric fractures. Acta Orthop Scand. 1980;51(5):803–10.
34. Fung W, Jonsson A, Buhren V, Bhandari M. Classifying intertrochanteric fractures of the proximal femur: does experience matter? Med Princ Pract. 2007;16(3):198–202.
35. Kim SJ, Ahn J, Kim HK, Kim JH. Is magnetic resonance imaging necessary in isolated greater trochanter fracture? A systemic review and pooled analysis. BMC Musculoskelet Disord. 2015;16:395.
36. Merlino AF, Nixon JE. Isolated fractures of the greater trochanter. Report of twelve cases. Int Surg. 1969;52(2):117–24.
37. Alam A, Willett K, Ostlere S. The MRI diagnosis and management of incomplete intertrochanteric fractures of the femur. J Bone Joint Surg (Br). 2005;87(9):1253–5.
38. Herren C, Weber CD, Pishnamaz M, Dienstknecht T, Kobbe P, Hildebrand F, et al. Fracture of the lesser trochanter as a sign of undiagnosed tumor disease in adults. Eur J Med Res. 2015;4:20.
39. Bonshahi AY, Knowles D, Hodgson SP. Isolated lesser trochanter fractures in elderly—a case for prophylactic DHS fixation. A case series. Injury. 2004;35(2):196–8.
40. James SL, Davies AM. Atraumatic avulsion of the lesser trochanter as an indicator of tumour infiltration. Eur Radiol. 2006;16(2):512–4.
41. Mavrogenis AF, Panagopoulos GN, Megaloikonomos PD, Igoumenou VG, Galanopoulos I, Vottis CT, et al. Complications after hip nailing for fractures. Orthopedics. 2016;39(1):e108–16.
42. Mittal R, Banerjee S. Proximal femoral fractures: principles of management and review of literature. J Clin Orthop Trauma. 2012;3(1):15–23.
43. Shane E, Burr D, Abrahamsen B, Adler RA, Brown TD, Cheung AM, et al. Atypical subtrochanteric and diaphyseal femoral fractures: second report of a task force of the American Society for Bone and Mineral Research. J Bone Miner Res. 2014;29(1):1–23.
44. Tao R, Lu Y, Xu H, Zhou ZY, Wang YH, Liu F. Internal fixation of intertrochanteric hip fractures: a clinical comparison of two implant designs. Sci World J. 2013;2013:834825.
45. Saleh A, Hegde VV, Potty AG, Lane JM. Bisphosphonate therapy and atypical fractures. Orthop Clin North Am. 2013;44(2):137–51.
46. Barbosa de Toledo Lourenco PR, Pires RE. Subtrochanteric fractures of the femur: update. Rev Bras Ortop. 2016;51(3):246–53.
47. Joglekar SB, Lindvall EM, Martirosian A. Contemporary management of subtrochanteric fractures. Orthop Clin North Am. 2015;46(1):21–35.
48. Parker M, Johansen A. Hip fracture. BMJ. 2006;333(7557):27–30.
49. Castronuovo E, Pezzotti P, Franzo A, Di Lallo D, Guasticchi G. Early and late mortality in elderly patients after hip fracture: a cohort study using administrative health databases in the Lazio region, Italy. BMC Geriatr. 2011;11:37.

50. Roche JJ, Wenn RT, Sahota O, Moran CG. Effect of comorbidities and postoperative complications on mortality after hip fracture in elderly people: prospective observational cohort study. BMJ. 2005;331(7529):1374.
51. Carpintero P, Caeiro JR, Carpintero R, Morales A, Silva S, Mesa M. Complications of hip fractures: a review. World J Orthop. 2014;5(4):402–11.
52. Loizou CL, Parker MJ. Avascular necrosis after internal fixation of intracapsular hip fractures; a study of the outcome for 1023 patients. Injury. 2009;40(11):1143–6.
53. Tripathy SK, Sen RK, Goyal T. Nonvascularized fibular grafting in nonunion of femoral neck fracture: a systematic review. Indian J Orthop. 2016;50(4):345–51.
54. Varghese VD, Livingston A, Boopalan PR, Jepegnanam TS. Valgus osteotomy for nonunion and neglected neck of femur fractures. World J Orthop. 2016;7(5):301–7.
55. Barnes R, Brown JT, Garden RS, Nicoll EA. Subcapital fractures of the femur. A prospective review. J Bone Joint Surg (Br). 1976;58(1):2–24.
56. Bojan AJ, Beimel C, Speitling A, Taglang G, Ekholm C, Jonsson A. 3066 consecutive gamma nails. 12 years experience at a single centre. BMC Musculoskelet Disord. 2010;11:133.
57. Bojan AJ, Beimel C, Taglang G, Collin D, Ekholm C, Jonsson A. Critical factors in cut-out complication after gamma nail treatment of proximal femoral fractures. BMC Musculoskelet Disord. 2013;14:1.
58. Pires RE, Santana EO Jr, Santos LE, Giordano V, Balbachevsky D, Dos Reis FB. Failure of fixation of trochanteric femur fractures: clinical recommendations for avoiding Z-effect and reverse Z-effect type complications. Patient Saf Surg. 2011;5:17.