Current Gastroenterology Reports (2019) 21:49
https://doi.org/10.1007/s11894-019-0718-1

ESOPHAGUS (J CLARKE AND N AHUJA, SECTION EDITORS)

How I Approach Dysphagia

Jooho P. Kim [1] · Peter J. Kahrilas [1]

© Springer Science+Business Media, LLC, part of Springer Nature 2019

Abstract

Purpose of Review This review presents an overview of the diagnostic approach to esophageal dysphagia and summarizes recent epidemiological trends and technical advancements.

Recent Findings The evaluation of dysphagia begins with a detailed history followed by endoscopy to evaluate for any structural abnormalities including malignancy. This is especially true given the emergence of eosinophilic esophagitis (EoE) as a dominant cause of esophageal dysphagia. In fact, it is now standard practice to obtain esophageal biopsies during endoscopy performed to evaluate dysphagia, since EoE can present without the characteristic mucosal features of rings, furrows, and exudate. Achalasia is also more frequently encountered since the introduction of high-resolution manometry (HRM) and the Chicago Classification into clinical practice. The Chicago Classification provides a stepwise diagnostic algorithm for evaluating HRM studies and systematically diagnosing esophageal motility disorders. Lastly, the functional lumen imaging probe (FLIP) is a novel technology that has added insight into both achalasia and EoE. Measuring esophageal distensibility with FLIP has useful prognostic implications for both diseases, and FLIP can identify motility abnormalities in achalasics not detected with HRM.

Summary A careful history is key to the efficient evaluation of dysphagia, and endoscopy is usually the first diagnostic study to obtain. For patients with prominent reflux symptoms, an empiric trial with proton pump inhibitors is reasonable then because reflux disease is such a common cause of dysphagia. Thereafter, patients should undergo HRM to evaluate for a motility disorder, and FLIP can provide complementary data to guide management.

Keywords Esophagus · Dysphagia · High-resolution manometer · Functional luminal imaging probe

Introduction

Dysphagia—defined as difficulty with or abnormal swallowing—is estimated to affect about 3% of the general population and has a significant impact on quality of life [1, 2]. The causes of dysphagia are numerous and can be broadly subdivided into oropharyngeal and esophageal causes. Oropharyngeal dysphagia is sometimes referred to as transfer dysphagia because it is characterized by difficulty in transferring ingested food from the mouth to the esophagus. On the other hand, esophageal dysphagia involves difficulty with the passage of food and/or liquids during passage from the upper esophageal sphincter to the stomach [3]. This review outlines a general approach to the evaluation of esophageal dysphagia in adults, highlights recent trends in the epidemiology of dysphagia, and discusses how high-resolution manometry (HRM) and the functional lumen imaging probe (FLIP) have yielded new insight into esophageal disorders.

History and Physical Exam

The word dysphagia is usually not part of a patient's lexicon. Similarly, asking whether or not they have trouble swallowing will often be interpreted as trouble with swallow initiation. Consequently, one needs to explore a variety of concepts with a patient to fully characterize dysphagia and organize an efficient evaluation. In most instances, this is worth the effort because spending time on the history goes a long way in identifying the likely etiology of dysphagia (Table 1). The first step is to determine whether their dysphagia is oropharyngeal or esophageal. A key distinction between the two is that while esophageal dysphagia is usually attributable to esophageal

This article is part of the Topical Collection on *Esophagus*

✉ Peter J. Kahrilas
p-kahrilas@northwestern.edu

[1] Feinberg School of Medicine, Department of Medicine, Northwestern University, 676 St Clair St, 14th floor, Chicago, IL 60611-2951, USA

Published online: 20 August 2019

Table 1 Key aspects of the patient history in ascertaining the likely etiology of dysphagia

Questions to explore in the history	Diagnostic implications
Do you cough or choke when trying to eat? After you swallow, does the food ever come back out through your nose?	Oropharyngeal dysphagia
What do you have trouble swallowing?	
• Only solids like meats/bread	• Ring, web, stricture, or rarely, malignancy
• Liquids and solids	• Motility disorder, especially achalasia
Any associated heartburn?	• GERD- esophagitis, stricture, hypersensitivity, or poor motility
Any associated regurgitation?	
• Acidic or sour regurgitation	• GERD
• Bland regurgitation during or even long after a meal	• Achalasia, rumination
Where does the food seem to get stuck?	
• Subxiphoid	• Distal esophageal process
• Mid chest	• Diffuse process like EoE or lichen planus
• Cervical	• Cricopharyngeal bar or distal process referred proximally (occurs about 30% of the time)
What happens when you swallow?	
• Do you feel the food as it goes down?	• Hypersensitivity
• Does the food get stuck?	• Mechanical obstruction- stricture
• After it is stuck, do you bring food back up?	• Mechanical obstruction- stricture
• Does the food go down fine, but you feel like it is still there?	• Globus sensation
When did it start? Is it getting worse? Any associated weight loss?	
• Recent onset, rapidly progressive, weight loss	• 1° or 2° malignancy
• Chronic, slowly progressive, no associated weight loss	• Non-malignant disease process
Do you have a history of food allergies, seasonal allergies, asthma, and/or eczema?	• EoE
What medications are you taking? Do you have any pain with swallowing? Do you drink an adequate amount of fluid when taking pills?	• Pill or caustic esophagitis (especially with tetracyclines, bisphosphonates, potassium, and NSAIDs)

Important questions to ask all patients who present with dysphagia and their clinical implications

disease, oropharyngeal dysphagia is commonly one of several manifestations of neuromuscular disorders such as stroke, multiple sclerosis, Parkinson's disease, amyotrophic lateral sclerosis, or dementia. Consequently, there are usually other physical findings indicative of an underlying neuromuscular disease, and patients typically report coughing, choking, drooling, dysarthria, dysphonia, aspiration pneumonia, or nasopharyngeal regurgitation as associated symptoms [3]. In the absence of these symptoms and neurologic comorbidities, a disorder affecting the esophageal body or the esophagogastric junction (EGJ) is more likely. At the crossroads between esophageal and oropharyngeal disorders are disorders of the upper esophagus (Zenker's diverticulum, cricopharyngeal bar) with features of both.

Causes of esophageal dysphagia can then be further subdivided into mechanical obstruction vs. motility disorders. In general, patients who primarily have difficulty with swallowing solid foods are more likely to have mechanical obstruction such as a stricture, ring, web, or malignancy, while those who report difficulty with swallowing both solids and liquids at the onset of symptoms are more likely to have a primary or secondary motility disorder. The time course of symptoms is also helpful to ascertain. Gradually progressive symptoms are more consistent with benign etiologies, while dysphagia that rapidly progresses is more concerning for malignancy of the esophagus or gastric cardia, especially in the setting of concurrent weight loss, anemia, or anorexia. On the other hand, intermittent dysphagia with normal function most of the time is more suggestive of eosinophilic esophagitis or an esophageal ring of fairly wide aperture such that it is only obstructive when swallowing a larger bolus of food, especially meat—also known as "steakhouse syndrome." Elucidating various adaptive eating behaviors that patients have adopted over time, such as chewing more carefully, longer meal times, drinking more water during meals, and changes in the positioning of their head and neck during swallowing, may point toward the chronicity of symptoms as well.

Asking the patient about heartburn or acid regurgitation is essential to the diagnostic process because gastroesophageal reflux disease (GERD) is the most common disease associated with dysphagia [4]. It is also useful to elicit a history of food allergies, environmental allergies, atopic dermatitis, allergic rhinitis, and asthma, as the presence of one or more these comorbidities might point toward an underlying diagnosis of

eosinophilic esophagitis (EoE), a disease which has become the most common cause of emergency room visits for esophageal food impactions [5••]. Lastly, alcohol use and a smoking history are important to ask about to assess the risk for esophageal cancer. These key features of dysphagia along with their diagnostic implications are summarized in Table 1.

The physical exam for patients with esophageal dysphagia is usually unrevealing or non-specific. However, skin changes like rashes, Raynaud's, calcinosis cutis, telangiectasias, and sclerodactyly are important to note if considering a diagnosis of scleroderma or another connective tissue disease. Identifying muscle wasting, weight loss, and pathologic lymph nodes, as well as signs of iron deficiency anemia (skin and conjunctival pallor), should increase the concern for malignancy.

Structural Abnormalities

Esophageal dysphagia always requires sufficient investigation to exclude the possibility of a malignancy. Practically speaking, this means performing an esophagogastroduodenoscopy (EGD), but if the history suggests a proximal esophageal obstruction, a very tight stricture, or one cannot exclude an oropharyngeal etiology, obtaining a fluoroscopic swallowing study with a barium esophagram can be the most informative initial investigation. It will rarely obviate the need for a subsequent EGD but can help direct the details of the planned procedure. Barium imaging is also better at delineating extrinsic compression of the esophagus as can occur with vascular anomalies such as an aberrant takeoff of the right subclavian artery (dysphagia lusoria). However, for most patients, the best initial test for the evaluation of dysphagia is an EGD because (1) it allows for the direct visualization of strictures, rings, esophagitis, mucosal features of EoE, or Barrett's; (2) it can be coupled with an esophageal dilation if needed; and (3) mucosal biopsies can be obtained to evaluate for EoE, metaplasia, infection, or suspected malignancy. In fact, since EoE remains in the differential diagnosis even in the circumstance of a normal appearing mucosa, mucosal biopsy has become an essential element of the diagnostic algorithm of esophageal dysphagia [5••].

Within the inventory of gastrointestinal symptoms, dysphagia, along with odynophagia, bleeding, weight loss, and anemia, is referred to as an alarm symptom because of the possibility of esophageal cancer. An estimated 18,000 cases of esophageal cancer are diagnosed annually in the USA, and as a testimony to its poor prognosis, about 16,000 people die from the disease annually [6]. However, the predictive value of alarm symptoms, including dysphagia, for gastroesophageal cancer is debatable with the sensitivity ranging from 4 to 62% and the specificity ranging from 67 to 99% [7]. Moreover, in patients who undergo EGD for dysphagia, suspected malignancy represents only about 0.9% of all findings [4]. Nonetheless, given the high morbidity and mortality of esophageal cancer, patients presenting with esophageal dysphagia should be evaluated with EGD to rule out this potentially devastating disease.

With cancer being a rare finding, the most common esophageal pathology causing dysphagia is benign stricturing, which is well visualized on EGD. Krishnamurthy et al. analyzed the frequency of various endoscopic findings in 30,377 patients who underwent EGD for the evaluation of dysphagia and found esophageal strictures to be the most common with the majority being peptic in etiology related to chronic acid reflux [4]. Other etiologies for strictures to consider include EoE, radiation therapy, post-surgical anastomotic strictures, and certain medications (particularly tetracyclines, bisphosphonates, non-steroidal anti-inflammatory drugs, and potassium supplements) [8]. Circumstances that may predispose to the development of peptic strictures include having a history of erosive esophagitis, coexisting scleroderma or CREST syndrome, treated achalasia, and (very rarely) Zollinger-Ellison syndrome. It should also be recognized that GERD is associated with esophageal dysphagia even in the absence of a stricture by the mechanisms of erosive esophagitis, hypersensitivity, or ineffective esophageal motility (Table 1), reinforcing the fact that GERD is always high on the list of diagnostic considerations for esophageal dysphagia. In view of this, the initial diagnostic/therapeutic intervention after a non-diagnostic EGD in the evaluation of dysphagia is a therapeutic trial of a proton pump inhibitor (PPI) (Fig. 1).

The esophageal disease entity that has rapidly increased in incidence and prevalence over the last three decades is EoE, an allergen-driven inflammatory condition that typically presents with dysphagia, food impaction, heartburn, non-cardiac chest pain, and/or abdominal pain. Potential endoscopic features of EoE include strictures, transient or fixed esophageal rings, a narrow caliber esophagus, furrows, edema, and mucosal exudate [9]. However, up to 25% of patients with EoE can have a normal endoscopic exam. Hence, the diagnosis of EoE is made with esophageal mucosal biopsies demonstrating eosinophilic inflammation at a density of ≥ 15 eosinophils per high power field in the area of greatest inflammation. Currently, EoE is identified as the cause of dysphagia in about 7% of patients undergoing EGD and appears to be rising in incidence at a rate faster than what would be expected based only on an increased recognition of the disease [5••, 10, 11]. Given that many patients with EoE present without typical endoscopic features, it has become standard practice to obtain four to six esophageal biopsies to evaluate for this disease during EGD for the evaluation of dysphagia [12••]. It is important to note that PPIs have become an essential part of the treatment paradigm for EoE, as there is a substantial subset of patients whose eosinophilic inflammation clears with PPIs, potentially because of anti-inflammatory properties that PPIs have in addition to their acid suppressing effects. PPI

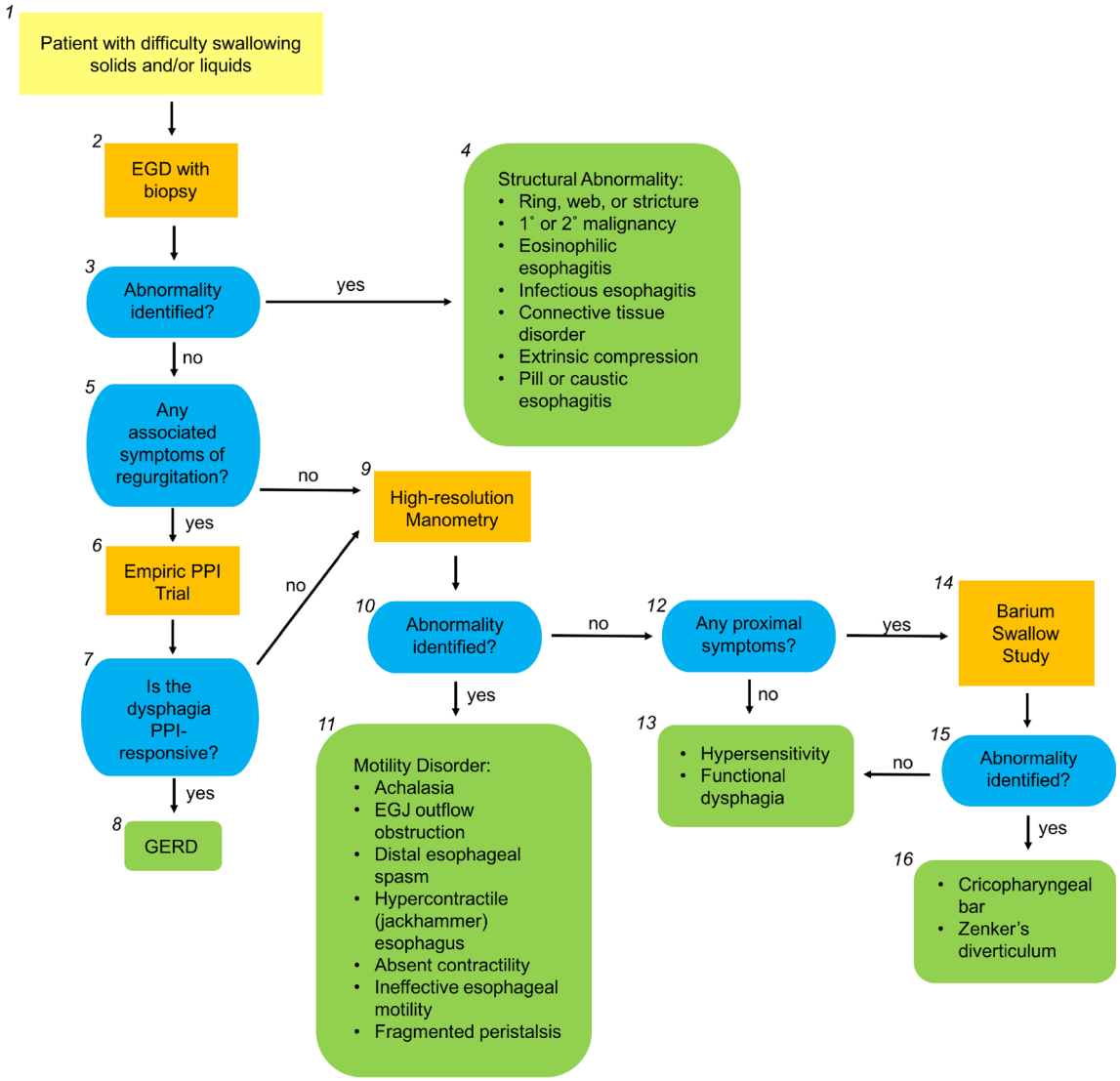

Fig. 1 Diagnostic evaluation of dysphagia. Flow chart representing a general diagnostic approach to dysphagia and the possible diagnoses detected with EGD, HRM, and barium swallow study. Patients with the symptom of dysphagia should be initially evaluated with an EGD to detect relevant structural abnormalities, including malignancy. If none are identified, an empiric PPI trial is warranted for patients who endorse any significant symptoms of acid reflux. In the absence of such symptoms or if the dysphagia fails to respond to PPIs, HRM should be pursued to diagnose potential motility disorders. If no motility disorders are identified, a barium swallow study can be used to diagnose proximal esophageal lesions if the patient endorses proximal symptoms. If EGD, HRM, and the barium swallow study are negative, the patient likely has either functional dysphagia or hypersensitivity

responsiveness however does not exclude a concurrent diagnosis of GERD, and both may be contributing to symptoms of dysphagia in EoE patients [13].

Motility Disorders

For patients with a normal endoscopic exam without significant reflux symptoms or who do not respond to a therapeutic trial of PPIs, high-resolution manometry (HRM) should be done as the next step in the evaluation of esophageal dysphagia (Fig. 1). HRM utilizes a transnasally positioned manometric catheter with 36 pressure sensors spaced 1 cm apart to record intraluminal pressure along the entire esophagus while the patient performs 10 swallows of 5-ml boluses of water at 20–30 s intervals in a supine or semi-recumbent position. The changes in intraluminal pressure at each sensor over time are displayed as colored isobaric contour plots called esophageal pressure topography or Clouse plots [14, 15]. Compared to now obsolete line tracing manometry, which utilized catheters with only 3–8 sensors, HRM not only has greater diagnostic accuracy and improved inter-observe agreement for motility disorders but also results in more accurate interpretations by even novice learners [16•, 17, 18]. As such, HRM has become the optimal diagnostic study for the detection of motility disorders.

Along with the widespread adoption of HRM was the development of an international consensus effort aimed at standardizing the diagnosis and classification of esophageal motility disorders, the Chicago Classification. The Chicago Classification, now in its third iteration, is built around three key metrics derived from the esophageal pressure topography plots: the integrated relaxation pressure (IRP), the distal contractile integral (DCI), and the distal latency (DL) [19, 20]. The hierarchical interpretive algorithm first considers the adequacy of EGJ deglutitive relaxation, expressed as the median IRP for the ten test swallows. The IRP is the mean minimal pressure across six adjacent sensors straddling the EGJ (the maximum of the minimums) for 4 s (contiguous or non-contiguous) after a swallow. In general, a median IRP < 15 mmHg is considered normal. The second metric utilized in the hierarchical algorithm is the DCI, which represents peristaltic vigor in the distal esophagus, spanning from the transition zone (the pressure node between the striated and smooth muscle portion of the esophagus) to the EGJ. The DCI is calculated as the product of the mean contractile amplitude multiplied by the duration of contraction multiplied by the length of this entire esophageal segment. Normal peristalsis has a DCI ranging between 450 and 8000 mmHg·s·cm. Based on the DCI, swallows can alternatively be classified as failed (DCI < 100 mmHg·s·cm), weak (DCI 100–450 mmHg·s·cm), or hypercontractile (> 8000 mmHg·s·cm) with failed and weak test swallows labeled as ineffective. The third fundamental metric is distal latency (DL), which represents the interval between relaxation of the upper esophageal sphincter and the contractile deceleration point just above the EGJ. Physiologically, the contractile deceleration point represents the transition from the faster contractions of esophageal peristalsis in the tubular portion of the esophagus to the slower process of ampullary emptying, which is mechanistically related to the reconstitution of the relaxed, effaced, and elongated lower esophageal sphincter [21, 22]. A DL of < 4.5 s is indicative of a premature contraction, which is the essential diagnostic feature of a spastic contraction defining distal esophageal spasm and type III achalasia [23, 24]. Beyond defining the limits of these three metrics, the Chicago Classification also assesses the integrity of esophageal peristalsis and defines abnormal pressurization within the esophagus after swallows. Swallows are classified as fragmented if they have a normal DCI but large (> 5 cm) gaps or breaks in the peristaltic contraction on the esophageal pressure topography plot. Esophageal pressurization is quantified during swallowing by measuring the intrabolus pressure within an open segment of the esophagus situated between two contracting segments. Pressurization can involve either the entire esophagus from the upper esophageal sphincter to the EGJ (panesophageal pressurization) or just the segment between the progressing contraction and the EGJ (compartmentalized pressurization) with pressures > 30 mmHg considered abnormal.

An immediate impact of the widespread adoption of the Chicago Classification has been increased recognition of achalasia, now subcategorized as types I, II, or III [19, 25••]. This is very significant because achalasia is the only esophageal motility disorder for which there are specific and effective treatment options [26]. The key feature of this disease is abnormal relaxation of the lower esophageal sphincter caused by degeneration of neurons in the myenteric plexus [27]. The increased recognition of achalasia has resulted in greater estimates of the incidence and prevalence of the disease, going from the oft quoted 1/100,000 and 10/100,000 respectively to about 3/100,000 and upwards of 33/100,000 respectively [28•]. The Chicago Classification identifies three subtypes of achalasia. Type I (classic) achalasia is defined by a complete absence of peristalsis in 100% of swallows (DCI < 100 mmHg·s·cm), type II (the most common subtype) with panesophageal pressurization in at least 20% of swallows, and type III (spastic, which is the rarest) with premature contractions (DL < 4.5 s) in ≥ 20% of swallows. All three subtypes typically have an IRP > 15 mmHg, although there are a number of caveats to this [25••]. Distinguishing among the three subtypes has prognostic value with regard to treatment response and helps guide the approach to management. Type II achalasia has the greatest rates of treatment success, while type III has the least [29, 30].

Another major evolution brought on by HRM and the Chicago Classification was the recognition of EGJ outflow obstruction (EGJOO) as an additional phenotype of impaired EGJ relaxation. If the IRP is elevated and there is evidence of preserved peristalsis with either a normal DCI or DCI between 100 and 450 mmHg·s·cm (i.e., weak peristalsis), the criteria for any subtype of achalasia are not met, and EGJOO is diagnosed. Even with its initial description, EGJOO was recognized as a heterogeneous condition potentially attributable to anatomic factors (small hiatal hernia, extrinsic vascular compression), artifact, or an incomplete expression of achalasia [31]. With that in mind, further evaluation with endoscopic ultrasound and/or CT is recommended to detect underlying conditions such as submucosal malignancies, infiltrative diseases like sarcoidosis, or a vascular malformation [32]. It is also wise to proceed with caution with this diagnosis because most patients tend to experience resolution of symptoms over time even without any treatment [33].

Apart from broadening our understanding of achalasia and its variations, HRM has also improved our understanding of other disorders of peristalsis. In the setting of a normal IRP, the Chicago Classification recognizes distal esophageal spasm, hypercontractile (jackhammer) esophagus, and absent contractility as major disorders of peristalsis because these are not found in normal controls. On the other hand, minor disorders of peristalsis (ineffective esophageal motility and fragmented peristalsis) can be found in asymptomatic controls. Among the major peristaltic disorders, distal esophageal

spasm is diagnosed when at least 20% of swallows exhibit premature contractions; hypercontractile (jackhammer) esophagus is characterized by at least 20% of swallows demonstrating a DCI > 8000 mmHg·s·cm, but with a normal DL; and absent contractility is defined by all swallows exhibiting failed peristalsis. The underlying pathology of absent contractility is frequently not identified, but this motility disorder can be associated with connective tissue disorders like scleroderma, amyloidosis, myxedema, diabetes, multiple sclerosis, or GERD [34]. Generally, the treatment of absent contractility focuses on treating the often-coexistent GERD with PPIs; there is no known pharmacological way to restore peristalsis. The optimal management of distal esophageal spasm and hypercontractile esophagus has yet to be delineated, but reducing smooth muscle contractility with nitrates, calcium channel blockers, phosphodiesterase inhibitors, or botulinum toxin injections is common strategy. However, it is unclear to what degree these manometric findings explain patients' symptoms [35]. Though many patients with distal esophageal spasm and hypercontractile esophagus present with dysphagia and/or chest pain, they often do not experience these symptoms during HRM.

Among the minor peristaltic disorders, the clinical significance of ineffective esophageal motility (IEM) and fragmented peristalsis is also unclear, as these patterns can be seen in asymptomatic, healthy controls, and patients with these minor disorders of peristalsis tend to have a favorable prognosis [36]. GERD is also an interesting entity with respect to esophageal motility, as it can present with a wide spectrum of manometric findings, including absent contractility, IEM, fragmented peristalsis, jackhammer, and normal peristalsis. The approach to classifying abnormal motor function in GERD was recently the subject of an international consensus report [37].

The Chicago Classification distinguishes motility disorders based on HRM metrics obtained during supine or semi-recumbent swallows of 5-ml boluses of water. However, to improve upon its diagnostic utility, HRM can also be performed with the patient sitting upright (a more physiologic position), with boluses of different consistencies such as thicker liquids and solids, and with test meals [38, 39]. Multiple rapid swallows of five 2-ml boluses of water spaced 2–3 s apart can also be performed during HRM to assess the integrity of deglutitive inhibition [40]. These provocative tests may detect abnormalities in esophageal motor function that are not seen during the standard HRM study protocol since many patients generally do not experience dysphagia when swallowing only small volumes of water. It is important to keep in mind that the normative values for the HRM metrics discussed above are different for these provocative tests and should be interpreted accordingly [41]. The current version of the Chicago Classification does not incorporate these provocative tests into its diagnostic algorithm, but that will likely change with future iterations currently in development.

Functional Lumen Imaging Probe

Since motility disorders are rarely, if ever, diagnosed on the basis of histopathology, there is no "gold standard" diagnostic test. Of the available diagnostics, HRM is the most accurate, but there are clearly instances in which barium fluoroscopy and even endoscopy will end up being the most useful [25••]. Enter the newest modality for assessing esophageal motility and the biomechanical properties of the esophagus using impedance planimetry, the functional lumen imaging probe (FLIP). The FLIP is passed transorally during sedated endoscopy and incorporates a cylindrical compliant bag that can be filled with conductive fluid (saline) to specified volumes. Within the bag, there is a pressure sensor and 16 paired electrodes spaced 1 cm apart. Using the concept of impedance planimetry, the device measures the cross-sectional area at each pair of electrodes as the bag is incrementally filled with saline. In real time, the FLIP display provides a three-dimensional view of the geometry of the esophageal lumen. By measuring the changes in CSA in relation to intra-bag pressure, the FLIP quantifies the distensibility of the esophageal body and sphincters [42, 43]. The EGJ distensibility index is calculated by dividing the median minimal CSA by the median intra-bag pressure. Currently, the FLIP is FDA-approved to measure pressure and dimensions in the GI tract, to guide bariatric procedures like gastric band placement and laparoscopic sleeve gastrectomy, and as an adjunctive test in the work-up of esophageal hypersensitivity.

With regard to the evaluation of dysphagia, there are currently two diseases in which FLIP may play a key role in guiding the diagnostic evaluation and management: achalasia and EoE. Endoscopically, EoE can present with a variety of features, including rings, strictures, and diffuse esophageal narrowing, which are the result of chronic inflammatory processes leading to fibrosis and progressive remodeling of the esophageal wall. However, EGD, the diagnostic test of choice for EoE, has a limited sensitivity for detecting esophageal narrowing [44]. FLIP, on the other hand, provides real-time cross-sectional area measurements and allows for accurate quantification of esophageal narrowing and strictures. This asset has also been leveraged to demonstrate diminished esophageal distensibility in patients with EoE compared to healthy controls [45], which has important prognostic implications as reduced distensibility is associated with a greater risk of food impaction [46, 47•].

In patients with achalasia, FLIP generates complementary data to HRM in that it provides information about the extent of lower esophageal sphincter opening, while HRM assesses only relaxation [25••]. Prior studies have shown that patients with untreated achalasia have a significantly lower EGJ distensibility index compared to healthy controls, but this is improved with effective treatment [48]. Hence, the dimensions and distensibility of the lower esophageal sphincter may be a

more clinically useful measure of disease severity than manometric patterns because the cross-sectional area of the sphincter determines the volume of the swallowed bolus that is able to pass through the EGJ into the stomach. Increases in the EGJ distensibility index are significantly associated with improved esophageal emptying and better symptomatic response to treatment [49, 50•]. Thus, FLIP may be a helpful test in guiding operative/endoscopic management, as higher intraoperative measurements of EGJ distensibility index after Heller myotomy or peroral esophageal myotomy have been shown to be predictive of better clinical outcomes [51•, 52].

FLIP can also assess patterns of esophageal motility when visualized in real time by a technique termed FLIP panometry. This method displays diameter changes in real time much the same way as HRM displays pressure changes. Distending the FLIP bag triggers secondary peristalsis, which is the contractile response of the esophageal body to luminal distention. By measuring the serial changes in cross-sectional area at each of the paired electrodes in response to balloon distention, FLIP can capture contractility patterns that are not seen on HRM. In one study comparing FLIP findings in 51 patients with treatment-naïve achalasia and 10 healthy controls, Carlson et al. (2015) found that the majority of patients with type I achalasia had no evidence of secondary peristalsis, but 27% of patients with type I achalasia had contractile activity on FLIP with either repetitive antegrade contractions or repetitive retrograde contractions. Though repetitive antegrade contractions were also observed in 80% of the control group, repetitive retrograde contractions were unique to patients with achalasia, and a significantly higher proportion of type III achalasia patients exhibited repetitive retrograde contractions compared to type I or II [53]. The significance of these findings is not yet fully understood, but FLIP panometry may lead to modifications in the subtyping of achalasia. In fact, in a comparative analysis, FLIP panometry was more sensitive than HRM in the detection of achalasia [54•]. In this study, 145 patients underwent upper endoscopy with FLIP and HRM, and the findings from both studies were compared. All 70 patients who had HRM studies consistent with achalasia also had abnormal FLIP panometry. However, among 34 patients with normal HRM studies, FLIP was able to identify 17 patients with abnormal esophageal motility, four of whom met criteria for and were treated for spastic achalasia.

Conclusion

In conclusion, the symptom of dysphagia should be approached systematically, starting with a careful history and physical to elicit clues into its potential etiology. Barium swallow studies are most useful in the setting of oropharyngeal dysphagia or dysphagia attributable to proximal esophageal lesions. For most patients, EGD is the initial test of choice in the evaluation of esophageal dysphagia, as it allows the clinician to visualize structural abnormalities, treat strictures should they be encountered, and obtain tissue biopsies to detect EoE and rule out malignancies. Given the increasing incidence of EoE, biopsies should always be sampled during EGD to evaluate esophageal dysphagia. Patients who have a negative EGD and with reflux symptoms noted on history should be treated with an empiric trial of PPIs, as their dysphagia may be secondary to GERD with or without a stricture. In the absence of reflux symptoms and/or if they fail to respond to PPIs, HRM should be pursued to evaluate for motility disorders, which can be diagnosed using the Chicago Classification. Lastly, FLIP is a relatively new technological advancement that has potentially significant diagnostic and prognostic utility with regard to achalasia and EoE.

Funding Information Peter J Kahrilas was supported by P01 DK117824 (PI John E. Pandolfino) from the US Public Health Service.

Compliance with Ethical Standards

Conflict of Interest Peter Kahrilas shares a patent with Drs John Pandolfino and Zhiyue Lin for the intellectual property behind FLIP panometry.

Jooho Kim declares no conflict of interest.

Human and Animal Rights and Informed Consent This article does not contain any studies with human or animal subjects performed by any of the authors.

Abbreviations *DCI*, distal contractile integral; *DL*, distal latency; *EGD*, esophagogastroduodenoscopy; *EGJ*, esophagogastric junction; *EGJOO*, esophagogastric junction outflow obstruction; *EoE*, eosinophilic esophagitis; *FLIP*, functional lumen imaging probe; *GERD*, gastroesophageal reflux disease; *HRM*, high-resolution manometry; *IEM*, ineffective esophageal motility; *IRP*, integrated relaxation pressure; *PPI*, proton pump inhibitor

References

Papers of particular interest, published recently, have been highlighted as:
• Of importance
•• Of major importance

1. Cho SY, Choung RS, Saito YA, Schleck CD, Zinsmeister AR, et al. Prevalence and risk factors for dysphagia: a USA community study. Neurogastroenterol Motil. 2014;27: 212–9.
2. Eslick GD, Talley NJ. Dysphagia: epidemiology, risk factors and impact on quality of life—a population-based study. Aliment Pharmacol Ther. 2008;27:971–9.
3. Malagelada JR, Bazzoli F, Boeckxstaens G, De Looze D, Fried M, et al. World gastroenterology organisation global guidelines: dysphagia–global guidelines and cascades update September 2014. J Clin Gastroenterol. 2015;49:370–8.
4. Krishnamurthy C, Hilden K, Peterson KA, Mattek N, Adler DG, et al. Endoscopic findings in patients presenting with dysphagia:

analysis of a national endoscopy database. Dysphagia. 2011;27: 101–5.
5.•• Dellon ES, Hirano I. Epidemiology and natural history of eosinophilic esophagitis. Gastroenterology. 2018;154:319–32 **This paper highlights the significant increase in the prevalence of EoE over the last few decades**.
6. Siegel RL, Miller KD, Jemal A. Cancer statistics, 2019. CA Cancer J Clin. 2019;69:7–34.
7. Vakil N, Moayyedi P, Fennerty MB, Talley NJ. Limited value of alarm features in the diagnosis of upper gastrointestinal malignancy: systematic review and meta-analysis. Gastroenterology. 2006;131:390–401.
8. ASGE Standards of Practice Committee, Pasha SF, Acosta RD, Chandrasekhara V, Chathadi KV, et al. Role of endoscopy in the evaluation and management of dysphagia. Gastrointest Endosc. 2014;79:191–201.
9. Hirano I, Moy N, Heckman MG, Thomas CS, Gonsalves N, Achem SR. Endoscopic assessment of the oesophageal features of eosinophilic oesophagitis: validation of a novel classification and grading system. Gut. 2013;62:489–95.
10. Kidambi T, Toto E, Ho N, Taft T, Hirano I. Temporal trends in the relative prevalence of dysphagia etiologies from 1999-2009. World J Gastroenterol. 2012;18:4335–41.
11. Dellon ES, Erichsen R, Baron JA, Shaheen NJ, Vyberg M, Sorensen HT, et al. The increasing incidence and prevalence of eosinophilic oesophagitis outpaces changes in endoscopic and biopsy practice: national population-based estimates from Denmark. Aliment Pharmacol Ther. 2015;41:662–70.
12.•• Hirano I. How to approach a patient with eosinophilic esophagitis. Gastroenterology. 2018;155:601–6 **This paper reviews the clinical presentations and diagnostic evaluation of EoE and explains the importance of obtaining multiple biopsies during EGD to rule out this disorder**.
13. Molina-Infante J, Gonzalez-Cordero PL, Lucendo AJ. Proton pump inhibitor-responsive esophageal esoinophilia: still a valid diagnosis? Curr Opin Gastroenterol. 2017;33:285–92.
14. Carlson DA, Kahrilas PJ. How to effectively use high-resolution esophageal manometry. Gastroenterology. 2016;151:789–92.
15. Carlson DA, Pandolfino JE. High-resolution manometry in clinical practice. Gastroenterol Hepatol. 2015;11:374–84.
16.• Roman S, Huot L, Zerbib F, Bruley des Varannes S, Gourcerol G, et al. High-resolution manometry improves the diagnosis of esophageal motility disorders in patients with dysphagia: a randomized multicenter study. Am J Gastroenterol. 2016;111:372–80 **This paper demonstrates the superiority of HRM to conventional manometry in the diagnosis of motility disorders**.
17. Carlson DA, Ravi K, Kahrilas PJ, Gyawali CP, Bredenoord AJ, et al. Diagnosis of esophageal motility disorders: esophageal pressure topography vs. conventional line tracing. Am J Gastroenterol. 2015;110:967–77.
18. Soudagar AS, Sayuk GS, Gyawali CP. Learners favour high resolution oesophageal manometry with better diagnostic accuracy over conventional line tracings. Gut. 2012;61:798–803.
19. Kahrilas PJ, Bredenoord AJ, Fox M, Gyawali CP, Roman S, Smout AJPM, et al. The Chicago Classification of esophageal motility disorders, v3.0. Neurogastroenterol Motil. 2015;27:160–74.
20. Yadlapati R. High-resolution esophageal manometry: interpretation in clinical practice. Curr Opin Gastroenterol. 2017;33:301–9.
21. Pandolfino JE, Leslie E, Luger D, Mitchell B, Kwiatek MA, et al. The contractile deceleration point: an important physiologic landmark on oesophageal pressure topography. Neurogastroenterol Motil. 2010;22:395–400.
22. Kwiatek MA, Nicodème F, Pandolfino JE, Kahrilas PJ. Pressure morphology of the relaxed lower esophageal sphincter: the formation and collapse of the phrenic ampulla. Am J Physiol Gastrointest Liver Physiol. 2012;302(3):G389–96.
23. Roman S, Lin Z, Pandolfino JE, Kahrilas PJ. Distal contraction latency: a measure of propagation velocity optimized for esophageal pressure topography studies. Am J Gastroenterol. 2011;106:443–51.
24. Pandolfino JE, Roman S, Carlson D, Luger D, Bidari K, Boris L, et al. Distal esophageal spasm in high-resolution esophageal pressure topography: defining clinical phenotypes. Gastroenterology. 2011;141:469–75.
25.•• Kahrilas PJ, Bredenoord AJ, Carlson DA, Pandolfino JE. Advances in management of esophageal motility disorders. Clin Gastroenterol Hepatol. 2018;16:1692–700 **State of the art discussion of the interrelationship between diagnostic modalities in the diagnosis and management of esophageal motility disorders**.
26. Vaezi MF, Pandolfino JE, Vela MF. ACG clinical guideline: diagnosis and management of achalasia. Am J Gastroenterol. 2013;108: 1238–49.
27. Kahrilas PJ, Boeckxstaens G. The spectrum of achalasia: lessons from studies of pathophysiology and high-resolution manometry. Gastroenterology. 2013;145(5):954–65.
28.• Samo S, Carlson DA, Gregory DL, Gawel SH, Pandolfino JE, et al. Incidence and prevalence of achalasia in central Chicago, 2004-2014, since the widespread use of high-resolution manometry. Clin Gastroenterol Hepatol. 2016;15:366–73 **This paper explores the rise in prevalence of achalasia over a decade likely due to increased detection of the disease and more accurate diagnoses with HRM**.
29. Rohof WO, Salvador R, Annese V, Bruley des Varannes S, Chaussade S, et al. Outcomes of treatment for achalasia depend on manometric subtype. Gastroenterology. 2013;144:718–25.
30. Pratap N, Kalapala R, Darisetty S, Joshi N, Ramchandani M, Banerjee R, et al. Achalasia cardia subtyping by high-resolution manometry predicts the therapeutic outcome of pneumatic balloon dilatation. J Neurogastroenterol Motil. 2011;17:48–53.
31. Scherer JR, Kwiatek MA, Soper NJ, Pandolfino JE, Kahrilas PJ. Functional esophagogastric junction obstruction with intact peristalsis: a heterogeneous syndrome sometimes akin to achalasia. J Gastrointest Surg. 2009;13:2219–25.
32. Krishnan K, Lin CY, Keswani R, Pandolfino JE, Kahrilas PJ, Komanduri S. Endoscopic ultrasound as an adjunctive evaluation in patients with esophageal motor disorders subtyped by high-resolution manometry. Neurogastroenterol Motil. 2014;26:1172–8.
33. Schupack D, Katzka DA, Geno DM, Ravi K. The clinical significance of esophagogastric junction outflow obstruction and hypercontractile esophagus in high resolution esophageal manometry. Neurogastroenterol Motil. 2017;29:1–9.
34. Smout A, Fox M. Weak and absent peristalsis. Neurogastroenterol Motil. 2012;24(suppl 1):40–7.
35. Xiao Y, Kahrilas PJ, Nicodème F, Lin Z, Roman S, Pandolfino JE. Lack of correlation between HRM metrics and symptoms during the manometric protocol. Am J Gastroenterol. 2014;109:521–6.
36. Ravi K, Friesen L, Issaka R, Kahrilas PJ, Pandolfino JE. Long-term outcomes of patients with normal or minor motor function abnormalities detected by high-resolution esophageal manometry. Clin Gastroenterol Hepatol. 2015;13:1416–23.
37. Gyawali CP, Roman S, Bredenoord AJ, Fox M, Keller J, et al. Classification of esophageal motor findings in gastro-esophageal reflux disease: conclusions from an international consensus group. Neurogastroenterol Motil. 2017;29:e13104.
38. Xiao Y, Read A, Nicodème F, Roman S, Kahrilas PJ, Pandolfino JE. The effect of a sitting vs supine posture on normative esophageal pressure topography metrics and Chicago Classification diagnosis of esophageal motility disorders. Neurogastroenterol Motil. 2012;24:e509–16.
39. Sweis R, Anggiansah A, Wong T, Kaufman E, Obrecht S, Fox M. Normative values and inter-observer agreement for liquid and solid bolus swallows in upright and supine positions as assessed by

esophageal high-resolution manometry. Neurogastroenterol Motil. 2011;23:509–e198.
40. Fornari F, Bravi I, Penagini R, Tack J, Sifrim D. Multiple rapid swallowing: a complementary test during standard oesophageal manometry. Neurogastroenterol Motil. 2009;21:718–e41.
41. Herregods TV, Roman S, Kahrilas PJ, Smout AJ, Bredenoord AJ. Normative values in esophageal high-resolution manometry. Neurogastroenterol Motil. 2015;27:175–87.
42. Hirano I, Pandolfino JE, Boeckxstaens GE. Functional lumen imaging probe for the management of esophageal disorders: expert review from the clinical practice updates committee of the AGA institute. Clin Gastroenterol Hepatol. 2017;15:325–34.
43. Carlson DA. Functional lumen imaging probe: the FLIP side of esophageal disease. Curr Opin Gastroenterol. 2016;32:310–8.
44. Gentile N, Katzka D, Ravi K, Trenkner S, Enders F, Killian J, et al. Oesophageal narrowing is common and frequently underappreciated at endoscopy in patients with oesophageal eosinophilia. Aliment Pharmacol Ther. 2014;40:1333–40.
45. Kwiatek MA, Hirano I, Kahrilas PJ, Rothe J, Luger D, Pandolfino JE. Mechanical properties of the esophagus in eosinophilic esophagitis. Gastroenterology. 2011;140:82–90.
46. Chen JW, Pandolfino JE, Lin Z, Ciolino JD, Gonsalves N, et al. Severity of endoscopically identified esophageal rings correlates with reduced esophageal distensibility in eosinophilic esophagitis. Endoscopy. 2016;48:794–801.
47.• Nicodème F, Hirano I, Chen J, Robinson K, Lin Z, et al. Esophageal distensibility as a measure of disease severity in patients with eosinophilic esophagitis. Clin Gastroenterol Hepatol. 2013;11:1101–7.e1 **This paper demonstrates the prognostic value of FLIP measurements in predicting the risk of food impaction in patients with EoE**.
48. Rieder E, Swanstrom LL, Perretta S, Lenglinger J, Riegler M, et al. Intraoperative assessment of esophagogastric junction distensibility during per oral endoscopic myotomy (POEM) for esophageal motility disorders. Surg Endosc. 2013;27:400–5.
49. Rohof WO, Hirsch DP, Kessing BF, Boeckxstaens GE. Efficacy of treatment for patients with achalasia depends on the distensibility of the esophagogastric junction. Gastroenterology. 2012;143:328–35.
50.• Yoo IK, Choi SA, Kim WH, Hong SP, Cakir OO, et al. Assessment of clinical outcomes after peroral endoscopic myotomy via esophageal distensibility measurements with the endoluminal functional lumen imaging probe. Gut Liver. 2019;13:32–9 **This paper reports how FLIP measurements are predictive of treatment response in the setting of achalasia**.
51.• Ngamruengphong S, von Rahden BH, Filser J, Tyberg A, Desai A, et al. Intraoperative measurement of esophagogastric junction cross-sectional area by impedance planimetry correlates with clinical outcomes of peroral endoscopic myotomy for achalasia: a multicenter study. Surg Endosc. 2016;30:2886–94 **This paper illustrates the potential intra-operative role of FLIP to tailor therapy in order to optimize treatment response for patients with achalasia**.
52. Teitelbaum EN, Soper NJ, Pandolfino JE, Kahrilas PJ, Hirano I, Boris L, et al. Esophagogastric junction distensibility measurements during Heller myotomy and POEM for achalasia predict postoperative symptomatic outcomes. Surg Endosc. 2015;29:522–8.
53. Carlson DA, Lin Z, Kahrilas PJ, Sternbach J, Donnan EN, Friesen L, et al. The functional lumen imaging probe detects esophageal contractility not observed with manometry in patients with achalasia. Gastroenterology. 2015;149:1742–51.
54.• Carlson DA, Kahrilas PJ, Lin Z, Hirano I, Gonsalves N, et al. Evaluation of esophageal motility utilizing the functional lumen imaging probe. Am J Gastroenterol. 2016;111:1726–35 **This paper demonstrates that FLIP may have a greater sensitivity for the detection of achalasia when compared to HRM**.

Publisher's Note Springer Nature remains neutral with regard to jurisdictional claims in published maps and institutional affiliations.