Annals of Hematology (2019) 98:1511–1512
https://doi.org/10.1007/s00277-018-3561-9

LETTER TO THE EDITOR

Diffuse large B cell lymphoma and schistosomiasis: a rare simultaneous occurrence

Magda Zanelli[1] · Maurizio Zizzo[2,3] · Maria Cecilia Mengoli[1] · Riccardo Valli[1] · Giovanni Martino[4] · Daniela Fenocchio[5] · Loredana De Marco[1] · Stefano Ascani[6]

Received: 3 November 2018 / Accepted: 15 November 2018 / Published online: 19 November 2018
© Springer-Verlag GmbH Germany, part of Springer Nature 2018

Dear Editor,

A 15-year-old African girl came to emergency department showing a clinical presentation of acute abdomen. Medical history was completely unremarkable (no previous surgery, trauma, and hemostasis disorders). Lab tests, HIV test, and tumor markers were within the normal ranges. Abdominal computed tomography (CT) scan without contrast medium showed a bulky hypodense mass in contact with the gynecological organs and no apparent cleavage planes with them.

At laparotomy, a bulky pelvic mass strictly adherent to the uterus, ovaries, fallopian tubes, and large intestine was detected. A surgical biopsy of the mass was performed. Histologically, the specimen consisted of fragments of lymph node almost completely replaced by a diffuse proliferation of large-sized, polymorphic lymphoid cells (Fig. 1). At immunohistochemistry, the neoplastic cells expressed B cell markers such as CD20 (Fig. 1, right inset) and CD79alpha and were positive for CD10, BCL6, and BCL2. MUM1/IRF4, CD30, CD5, c-MYC, and HHV8 were negative. In situ hybridization for Epstein-Barr virus (EBV)–encoded small RNA (EBER) was negative as well. The proliferation index, evaluated with Ki67/MIB1, was high and approximately 80% (Fig. 1, left inset). The material was not adequate to perform fluorescence in situ hybridization (FISH) to detect c-MYC rearrangement and BCL2 and/or BCL6 translocations due to DNA denaturation. A diagnosis of diffuse large B cell lymphoma, not otherwise specified (NOS), germinal-center (GCB)-like, was rendered. An additional finding within the B cell lymphoma was the presence of small foci rich in eosinophils, histiocytes, and small T lymphocytes surrounding eggs of *Schistosoma* (Fig. 2). The patient's workup revealed urinary infection by *Schistosoma haematobium*.

Three weeks after surgery, the patient underwent 6 cycles of chemotherapy according to the R-CHOP regimen (rituximab plus cyclophosphamide, doxorubicin, vincristine, and prednisone). Currently, she is alive and without disease (at post-chemotherapy staging) and in 10-month follow-up.

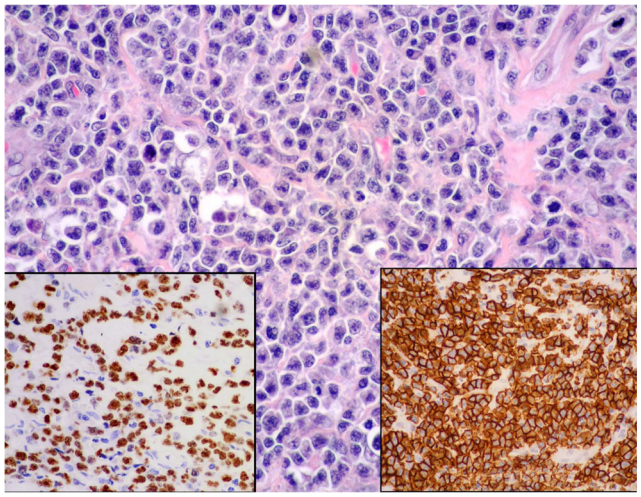

Fig. 1 Diffuse proliferation of polymorphic, large-sized lymphoid cells (HE × 20); *right inset*, CD20 immunohistochemical positivity highlights the B cell phenotype of the tumor; *left inset*, high proliferative index of the neoplasm, evaluated with Ki67

✉ Maurizio Zizzo
zizzomaurizio@gmail.com

1 Department of Oncology and Advanced Technologies, Pathology Unit, Azienda Unità Sanitaria Locale/IRCCS di Reggio Emilia, Viale Risorgimento, 80, 42123 Reggio Emilia, Italy

2 Department of Oncology and Advanced Technologies, Surgical Oncology Unit, Azienda Unità Sanitaria Locale/IRCCS di Reggio Emilia, Viale Risorgimento, 80, 42123 Reggio Emilia, Italy

3 Clinical and Experimental Medicine PhD Program, University of Modena and Reggio Emilia, Modena, Italy

4 Institute of Hematology-CREO, Ospedale Santa Maria della Misericordia, University of Perugia, Piazza Menghini, 1, 06129 Perugia, Italy

5 Pathology Unit, Ospedale Santa Maria della Misericordia, University of Perugia, Piazza Menghini, 1, 06129 Perugia, Italy

6 Pathology Unit, Ospedale di Terni, University of Perugia, Viale Tristano di Joannuccio, 05100 Terni, Italy

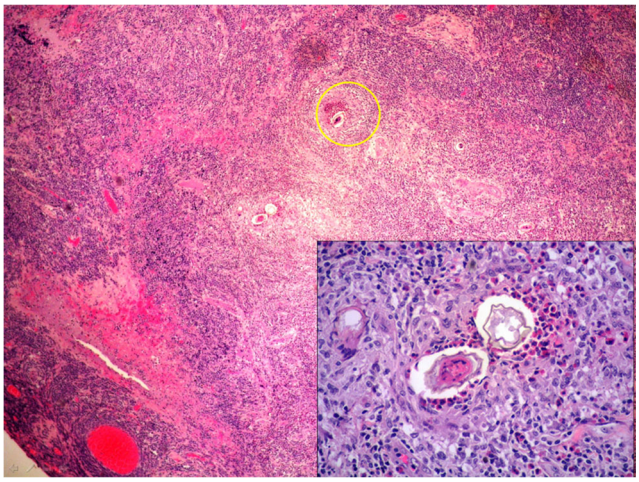

Fig. 2 The lymphomatous proliferation containing eggs of *Schistosoma*. In the *inset*, foci rich in eosinophils around eggs of *Schistosoma* are highlighted

Infection with *Schistosoma haematobium*, leading to chronic inflammation, is a well-recognized risk factor for bladder cancer [1]. To the best of our knowledge, the simultaneous occurrence of *Schistosoma* infection and lymphoma has been only exceptionally reported [2, 3].

In the current WHO classification of hematopoietic and lymphoid tumors, diffuse large B cell lymphoma (DLBCL) associated with chronic inflammation (DLBCL-CI) is defined as a neoplasm occurring in the context of longstanding chronic inflammation generally involving body cavities or narrow spaces [4]. The prototype of this category is represented by pyothorax-associated lymphoma (PAL) which is a DLBCL occurring in patients who have undergone artificial pneumothorax as a therapy for tuberculosis and subsequently develop chronic pyothorax [4, 5]. PAL is consistently associated with EBV infection and shows an aggressive behavior [4, 5]. Recently, another group of DLBCL has been included in the category of DLBCL-CI, but renamed as fibrin-associated EBV+ large B cell lymphoma, because it arises in areas of fibrinous material [6]. In contrast to PAL, these tumors are not mass-forming lesions, but are made up of small collections of neoplastic cells and therefore only detected incidentally [6]. They arise in unusual sites as in the context of pseudocysts and cardiac myxoma or in association with prosthetic cardiac valves and metallic implants [6]. Interestingly, differently from PAL, most cases frequently follow an indolent course and are potentially cured by surgery alone. The spectrum of DLBCL-CI seems to be quite broad, including scenarios with very different clinical outcomes and treatments. Therefore, in order to ensure the correct therapeutic choice, an integrated clinicopathological approach of these tumors is mandatory.

In the present case, DLBCL was EBV negative and does not belong strictly speaking to the category of DLBCL-CI, which generally shows a strong association with EBV infection. However, considering that *Schistosoma* infection definitely elicits a chronic inflammatory stimulus and bladder carcinoma is a well-recognized sequela of schistosomiasis, a relation between infection and lymphoma occurrence could be hypothesized. Additional studies and cases are essential to better understand the broad clinicopathological spectrum of DLBCL arising in association with chronic inflammation.

Compliance with ethical standards

Conflict of interest The authors declare that they have no conflict of interest.

Ethical approval Local ethics committee (Comitato Etico dell'Area Vasta Emilia Nord, Italy) ruled that no formal ethics approval was required in this particular case.

Informed consent Written informed consent was obtained from patient's relatives (mother) for publication of this case report and any accompanying images. A copy of the written consent is available for review by the Editor-in-Chief of this journal.

References

1. Ishida K, Hsieh MH (2018) Understanding urogenital schistosomiasis-related bladder cancer: an update. Front Med (Lausanne) 5:223
2. Chrimwami B, Okoda L, Nelson AM (1991) Lymphoma and Schistosoma mansoni schistosomiasis. Report of 1 case. Arch Anat Cytol Pathol 39(1–2):59–61
3. Natori K, Izumi H, Ishikara S, Fujimoto DNY, Kuraishi Y (2008) Malignant lymphoma and Schistosoma japonica infection. Br J Haematol 142(2):147
4. Swerdlow SH, Campo E, Harris NL, Jaffe ES, Pilleri SA, Stein H. Thiele J et al (eds) (2017) WHO classification of tumours of haematopoietic and lymphoid tissues, WHO classification of tumours, revised 4th edn. IARC: World Health Organization
5. Ascani S, Piccioli M, Poggi S, Briskomatis A, Bolis GB, Liberati F, Frongillo R, Caramatti C, Fraternali-Orcioni G, Gamberi B, Zinzani PL, Lazzi S, Leoncini L, O'Leary J, Piccaluga PP, Pileri SA (1997) Pyothorax-associated lymphoma: description of the first two cases detected in Italy. Ann Oncol 8(11):1133–1138
6. Boyer DF, McKelvie PA, de Leval L, Edlefsen KL, Ko YH, Aberman ZA, Kovach AE, Masih A, Nishino HT, Weiss LM, Meeker AK, Nardi V, Palisoc M, Shao L, Pittaluga S, Ferry JA, Harris NL, Sohani AR (2017) Fibrin-associated EBV-positive large B-cell lymphoma. An indolent neoplasm with features distinct from diffuse large B-cell lymphoma associated with chronic inflammation. Am J Surg Pathol 41(3):299–312