Child's Nervous System (2019) 35:2171–2178
https://doi.org/10.1007/s00381-019-04194-0

ORIGINAL ARTICLE

Feasibility and effectiveness of a newly modified protocol-guided selective dorsal rhizotomy via single-level approach to treat spastic hemiplegia in pediatric cases with cerebral palsy

Qijia Zhan[1] · Liang Tang[2] · Yanyan Wang[1] · Bo Xiao[1] · Min Shen[3] · Shuyun Jiang[4] · Rong Mei[1] · Zhibao Lyu[5]

Received: 7 January 2019 / Accepted: 6 May 2019 / Published online: 29 May 2019
© Springer-Verlag GmbH Germany, part of Springer Nature 2019

Abstract

Purpose It still remains challenging to treat CP cases with spastic hemiplegia using SDR via a single-level approach when guided by the traditional EMG response grading system. Our aim was to assess the feasibility and effectiveness of a newly modified protocol-guided single-level laminectomy SDR to treat such pediatric patients.

Methods A retrospective cohort review was conducted in the CP cases with spastic hemiplegia undergone our newly modified protocol-guided single-level approach SDR since May 2016 to October 2017, and followed by intensive rehabilitation program for at least 12 months in both Shanghai Children's Hospital and Shanghai Rehabilitation and Vocational Training Center for the Disabled. Inclusion and exclusion criteria were set for the selection of patients in the current study. Our study focused on the setup, EMG recording interpretation, and outcome measures for this newly modified rhizotomy scheme.

Results Eleven cases were included in the current study. Based on our new rhizotomy protocol, a total of 34 rootlets over our 11 cases were cut (2 in 4, 3 in 4, 4 in 1, and 5 rootlets in 2 cases, respectively). After SDR and the following rehabilitation program at a mean duration of 19 months, muscle tone of those "target muscles" in affected lower extremities which identified during pre-op assessment decreased by a mean of 1.4 degrees (Modified Ashworth Scale) in our cases. Strength of those target muscles and ROM of joints involved in their lower limbs were reported to have improved significantly as well. All cases showed major progress with regard to their motor function. A mean of about 10-point increase of GMFM-66 score was reported, and five of six cases who were with GMFCS level II preoperatively improved their GMFCS level at the last assessment. Kinematics of joints of hip, knee, and ankle on the affected side in our cases demonstrated a major correction, along with improvement of their foot pressure patterns to the ground during their gait cycles. Surgery-related complications, such as cerebral–spinal fluid leak/infection, long-term hypoesthesia, or urinary/bowel incontinence were not recorded in the current study.

Conclusion Single-level SDR when guided by our simplified rhizotomy protocol is feasible and effective to treat pediatric CP cases with spastic hemiplegia.

Keywords Simplified rhizotomy scheme · EMG response interpretation · Outcome measures · Comparison

Introduction

Selective dorsal rhizotomy (SDR) is a neurosurgical procedure developed to decrease spasticity in the lower extremities in cases with spastic cerebral palsy (CP), thereby to improve their motor function [1]. Intra-operative EMG response grading system has been widely applied as a crucial measure to help neurosurgeons deicide which rootlet required transaction

✉ Bo Xiao
xiao977@hotmail.com

1 Department of Neurosurgery, Shanghai Children's Hospital, Shanghai Jiao Tong University, 355 Luding Rd, Shanghai, China

2 Rehabilitation Center, Shanghai Children's Hospital, Shanghai Jiao Tong University, 355 Luding Rd, Shanghai, China

3 Rehabilitation Center, Shanghai Rehabilitation and Vocational Training Center for the Disabled, 265 Linyi North Rd, Shanghai, China

4 Gait and Motion Analysis Center, Yueyang Hospital of Integrated Traditional and Western Medicine, Shanghai University of Traditional Chinese Medicine, 110 Ganhe Rd, Shanghai, China

5 Department of General Surgery, Shanghai Children's Hospital, Shanghai Jiao Tong University, 355 Luding Rd, Shanghai, China

during SDR procedure [2–5]. In clinical practice, neurosurgeons hardly perform SDR via single-level approach in spastic hemiplegic cases. One major reason is that EMG responses in those cases during surgery are relatively difficult to match the rhizotomy criteria when using the rhizotomy scheme based on the traditional EMG response grading system.

In the current study, our aim was to assess the feasibility and effectiveness of single-level approach SDR guided by a newly modified rhizotomy protocol when treating CP cases in children with spastic hemiplegia by focusing on its setup, EMG recording interpretation, and outcome measures.

Methods

A retrospective study was carried out in pediatric CP cases with spastic hemiplegia undergone our newly modified protocol-guided SDR in our institute since May 2016 to October 2017. Relevant clinical and follow-up data were taken from the Database of Pediatric Cerebral Palsy Patients in the Rehabilitation Department of both Shanghai Children's Hospital and Shanghai Rehabilitation and Vocational Training Center for the Disabled. Diagnosis of spastic hemiplegic CP in these cases was made by a multidisciplinary team that included rehabilitation physicians, pediatric neurologists, and physiotherapists. This study was supervised and approved by the Institutional Science and Research Board in our institute.

Inclusion and exclusion criteria

Selection criteria for CP cases included in the current study were as follows: (1) with the diagnosis of spastic hemiplegia; (2) age at SDR guided by our newly modified protocol ≥ 3, but ≤ 14 years old; (3) at least 12 months post-op rehabilitation therapy conducted at our institutes; and (4) pre-op and follow-up evaluation was made by the same rehabilitation team. The exclusion criteria included were the following: (1) combined with other neurological disorders, (2) fixed tendon contractures in the lower extremities, (3) with hip dysplasia, (4) previously operated on with tendon lengthening or other orthopedic procedures to treat spasticity, (5) with moderate to severe mental retardation, and (6) loss to follow-up.

Clinical assessment

Based on the Rehabilitation and Evaluation Protocol for CP Children in both institutes, assessments included measurements of (1) muscle tone (using the Modified Ashworth Scale (MAS)) and strength (Muscle Strength Grading System) of those spastic muscles (particularly on muscles of hip adductor, hamstring, rectus femoris, gastrocnemius, soleus, tibialis anterior); (2) range of motion (ROM) of those joints involved in lower limbs (hip, knee, and ankle), which included both passive and active; (3) the level of Gross Motor Function Classification System (GMFCS) and Gross Motor Function Measure 66 items (GMFM-66) score; and (4) gait analysis.

Pre-op assessment required to identify those "target muscles" in lower extremities which was part of our newly modified rhizotomy protocol. Target muscles were defined as muscles of which muscle tone was ≥ grade 2 (MAS). Head and lumbar MRI without contrast were performed preoperatively in all our cases, in order to rule out those potential structural abnormalities in central nervous system, and clarify the location of conus medullaris.

Surgical procedure

Patients were operated on under general anesthesia in prone position on a water-garment warmer to maintain body temperature between 36.0 and 37.0 °C during surgery. Minimum alveolar concentration (MAC) of sevoflurane inhalation was kept at 0.5 since the skin incision was made.

The skin cut was typically at the level of L2 with the length of 3.5–4 cm. After L2 laminectomy was done, microscope was required to move in. The dura was then sharply incised in the midline for a length of approximately 1.0–1.2 cm. Arachnoid membrane was then opened, and a sheet with a width of 5 mm was placed ventrally around all of the roots of the cauda equina at this level. The tip of the sheet directed towards the chief surgeon was sutured to the skin to prevent its migration during the procedure. Each rootlet was suspended over rhizotomy probes and tested by electrical stimulation. Rootlets were then left spared or cut based on our modified rhizotomy protocol. This procedure was repeated until all rootlets are probed. The dura mater was then closed with running stitches of 4-0 monocryl, and skin incision was sutured in layers.

Intraoperative nerve rootlet stimulation and EMG interpretation

EMG needle electrodes were placed in the bilateral hip adductors, rectus femoris, hamstring, gastrocnemius medialis, gastrocnemius lateralis, peroneus longus, tibialis anterior, and anal sphincter. Direct stimulation over those nerve rootlets was achieved through bipolar stimulation with rhizotomy probes. All stimulation and EMG recordings were conducted using Cadwell-Cascade Elite neurophysiological monitoring system.

Single pulse of electrical stimulation with duration of 0.2 ms and intensity started since 0.00 mA with step of 0.01 mA was applied to differentiate the following: (1) whether the rootlet stimulated was motor or sensory (differentiation of ventral and dorsal nerve rootlets was based on the threshold of stimulation, and the latency of EMG responses to the

stimulus); (2) if it was sensory rootlet, whether stimulation initially innervated target muscle responses (among 15 channels monitored, EMG responses in which first reached 200 μV amplitude). If yes, then we perform train stimulation on the same rootlet for 1 s with stimulation duration of 0.2 ms, intensity of by which 200 μV EMG amplitude could be reached during single pulse stimulation, and in a frequency of 50 Hz, in order to decide whether we needed to section it in 50% or 75% (detailed in "New rhizotomy protocol" section).

New rhizotomy protocol

Our modified rhizotomy protocol was briefly graded into three levels (Fig. 1):

1. Dorsal rootlets that evoke EMG response in non-target muscles were left intact.
2. Dorsal rootlets that could evoke responses in a target muscle with NO EMG responses observed in the opposite extremities during train stimulation were transected 50%.
3. Dorsal rootlets that could evoke responses in a target muscle with EMG responses observed in the opposite extremities during train stimulation were transected 75%.

Postoperative care and rehabilitation

After SDR procedure, the patients were kept in PICU for one night. Postoperative analgesia was administered as a routine with intravenous morphine drip for 48 h and use of ibuprofen starting 24 h after the surgery. Once their activity was liberalized, the patients were transferred to an inpatient rehabilitation unit for an intensive therapy program focusing on stretching and strengthening of their lower extremities. The typical length of stay was 3 weeks in the inpatient rehabilitation unit. As a routine, our team was required to perform an additional static assessment (measurement of muscle tone, strength, and range of motion) in those cases before transferring them to an intensive outpatient program of 3–5 days of rehabilitation therapy per week for 12 months.

Data collection and analysis

Demographic data were interpreted using descriptive statistics. Data are reported as number and percentage, mean ± standard deviation, or range. Comparison between preoperative and postoperative GMFM-66 score was performed using Wilcoxon signed-rank test. A p value of less than 0.05 was



Fig. 1 Examples of modified EMG interpretation (obtained in four cases). (a) When single-pulse stimulation was carried out, EMG responses obtained in Rt. tibialis anterior which was not the "target muscle" identified during pre-op assessment, the rootlet was left intact. (b) EMG responses obtained in Lt. lateral gastrocnemius which was the target muscle, but train stimulation did not elicit EMG responses on the Rt. side, and the rootlet was cut 50%. (c) EMG responses obtained mainly in Lt. hamstring which was the target muscle, but train stimulation did not elicit EMG responses on the Rt. side, and the rootlet was cut 50%. (d) EMG responses obtained in Rt. hamstring which was the target muscle, but train stimulation did elicit EMG responses on the Lt. side (mainly hamstring and the medial gastrocnemius), and the rootlet was cut 75%

regarded as being statistically significant. All data were entered into IBM SPSS Statistics Version 23.0 for further analysis.

Results

Among 15 cases with spastic hemiplegia undergone our modified rhizotomy protocol-guided SDR since the middle of 2016 to October 2017, 11 matched the criteria of the current study. The age at SDR in these children was between 4 and 8 years. Preoperatively, prominent spasm solely restricted in the posterior part of the leg (gastrocnemius and soleus) was found in six cases. One case had his marked spastic muscles of hip adductor, hamstring, gastrocnemius, and soleus in the right lower extremity. A total of 28 muscles were identified as target muscles in these 11 cases. The mean follow-up duration post-SDR was 19.0 ± 5.2 (15–31) months. Long-term surgery-related complications were not recorded in our study. None of our cases received additional orthopedic procedure or pharmaceutical treatment for spasticity during the whole follow-up. All cases improved dramatically post-op with regard to their motor function. Among six cases with their pre-OP GMFCS level II, five were revealed upgrading to level I at the time of the last assessment. GMFM-66 score in all 11 cases in our study at the last follow-up was statistically better than at pre-op (84.9 ± 9.1 vs. 75.0 ± 10.3). Clinical data are summarized in Table 1.

Table 1 General clinical data of 11 cases included in the study

Characteristics	No. (%)[a]
Gender	
Boy	6 (54.5)
Girl	5 (45.5)
Age at surgery (years) (mean, SD)	5.7 ± 1.3
Etiology of spasticity	
Premature	2 (18.2)
Asphyxia	2 (18.2)
Unknown	7 (63.6)
Spastic side	
Right	8 (72.7)
Left	3 (27.3)
Target muscle identified at pre-op	
Gastrocnemius and soleus	6 (54.5)
Gastrocnemius, soleus, and hamstring	4 (36.4)
Gastrocnemius, soleus, hamstring, and hip adductor	1 (9.1)
GMFCS level	
At pre-op	
Level I	5 (45.5)
Level II	6 (54.5)
At the last follow-up	
Level I	10 (90.9)
Level II	1 (9.1)
GMFM-66	
At pre-op (mean, SD)	75.0 ± 10.3
At the last follow-up (mean, SD)	84.9 ± 9.1*
Surgery-related complications	
CSF leak or infection	0 (0.0)
Hypoesthesia	0 (0.0)
Hypersensitivity (≤ 2 weeks)	2 (18.2)
Urinary/bowel incontinence	0 (0.0)
Follow-up (months) (mean, SD)	19.0 ± 5.2

SD standard deviation, *GMFCS* gross motor function classification system, *GMFM* gross motor function measure, *CSF* cerebral spinal fluid

*Statistically significant difference obtained when compared with pre-op

[a] Unless otherwise indicated

Intra-operative EMG interpretation and rhizotomy results

The number of rootlets stimulated during surgery varied from 55 to 67 across cases, among which, about one third were motor. Differentiation of motor and sensory rootlets was mainly based on their electrophysiological characteristics. Sensory ones required ten times higher amplitude of electrical stimulation to elicit EMG responses. When stimulation over sensory rootlets, EMG latency was about 7 ms longer than on those motor ones.

In a total of 411 dorsal rootlets identified in these 11 cases, 34 matched our newly modified rhizotomy criteria, most of which (33/34) were cut 50%. Number of rootlets required sectioning during SDR procedure ranged from 2 to 5 across our cases when based on our rhizotomy protocol. Interestingly, when tried to apply the traditional EMG response grading system virtually to guide rootlet rhizotomy in these cases by using our EMG data, we found out that 5 rootlets matched the traditional criteria in only 3 cases (27.2%) (Table 2).

Muscle tone, strength of target muscles, and ROM of joints involved

Muscle tone of target muscles had a tendency to decrease with time post-SDR (2.3 ± 0.5 vs. 1.5 ± 0.4 vs. 1.0 ± 0.4 in 28 muscles, pre-op, 3 weeks post-op, and at the last follow-up, respectively). Among the four main muscles we focused on (hip adductor, hamstring, gastrocnemius, and soleus), muscle tone of gastrocnemius and soleus reduced the most. Ankle clonus which was observed pre-op in three cases was completely vanished after SDR surgery. With the post-SDR rehabilitation program being on, the strength of those target muscles

Table 2 EMG interpretation and rhizotomy data in the study

Characteristics	Value (mean, SD)
Rootlets stimulated (number)	55–67 (60.9 ± 3.6)
Motor rootlet (number)	22–25 (23.5 ± 1.3)
EMG threshold (mA)	0.01–0.10 (0.05 ± 0.02)
EMG latency to the stimulus (ms)	3.5–9.3 (5.4 ± 1.9)
Sensory rootlet (number)	35–42 (37.4 ± 3.6)
EMG threshold (mA)	0.18–1.80 (0.49 ± 0.24)
EMG latency to the stimulus (ms)	6.7–15.5 (12.2 ± 2.5)
Sum of rootlets matched our criteria (number)	34
Rootlet cut 50% (number)	2–5 (3.0 ± 1.0)
Rootlet cut 75% (number)	0–1 (0.1 ± 0.3)
Sum of rootlets matched the traditional criteria (number)	5
Rootlet cut 50% (number)	0–2 (0.4 ± 0.7)
Rootlet cut 75% (number)	0–1 (0.1 ± 0.3)

EMG electromyography, *SD* standard deviation

improved dramatically after the reduction of muscle tone in these cases. Both passive and active ROMs were revealed notable increase post-SDR as well (Table 3).

Gait analysis

Gait patterns improved significantly post-op in all our cases included in the current study. Kinematics of the affected ankle joint demonstrated major improvement during the whole gait cycles in all 11 cases. Our patients showed as well progress of knee extension (spastic side) at initial contact during stance phase. In addition, improvement of internal tibia torsion was observed in all cases at the last assessment. Prominent correction of hip external rotation was revealed in all our cases as well. Foot pressure patterns on the affected side during gait cycles also improved dramatically (Fig. 2).

Discussion

SDR under the guidance of the traditional EMG response grading system to treat spastic CP cases has been widely practiced for decades [2, 6–10]. It was first applied in SDR via multilevel approach which was mainly based on the principle that each dorsal root contained the sensory input from the structures within the distribution of its corresponding body segment (dermatome) [2, 6, 7]. Due to the nature that a dorsal root at a particular level usually has few rootlets, such EMG interpretation scheme initially was adopted to help neurosurgeons during surgery to differentiate which rootlet required to cut, and how much to cut. The electrophysiological EMG grading method turned extremely important after the advent of the single-level approach SDR, and became an essential part of the surgery [8–11]. With more SDR surgeries being practiced, neurosurgeons have gradually been aware that it is difficult to use this grading scheme in children with spastic hemiplegia to guide the rhizotomy procedure. A crucial reason is that it could hardly reach the 3+ or 4+ EMG responses when stimulating dorsal rootlets in those cases.

In the current study, we have also encountered this phenomenon. Of the 411 dorsal rootlets we tested during surgery, 5 could match the rhizotomy criteria of the traditional EMG scheme only in 3 cases. Three rootlets were revealed in one case with spasm discovered in his hip adductor, hamstring, gastrocnemius, and soleus on the right lower limb. Other two rootlets were found in two different cases, one in each. The traditional scheme of EMG response grading system failed to differentiate dorsal rootlets which required sectioning in the rest of eight cases during our SDR procedure when based on data of our EMG recordings. This phenomenon suggested the limitation of this traditional grading scheme when surgically dealing with spastic hemiplegic children.

In 2016, Bales et al. [10] proposed a modified rhizotomy protocol that suggested taking preoperative evaluation results into account when performing SDR. Before the surgery, the assessment is required to mark the so-called target muscles in lower extremities of those CP cases, which need to be focused on during the SDR procedure. Bales' rhizotomy scheme for the first time gives the potential to be applied to treat spastic hemiplegic CP cases with SDR via single-level approach. Due to the nature that spastic status in cases with spastic hemiplegia is relatively mild and the spasm affected body parts are quiet limited, we simplified his scheme when applying it in SDR to treat cases with spastic hemiplegia by eliminating the small-probability event that the abnormal EMG responses would be obtained via train stimulation on those dorsal rootlets through which single-pulse stimulation only evoked EMG responses on non-target muscles, therefore making our newly modified protocol more simple and clearer. In the current study, a total of 34 rootlets over our cases were considered

Table 3 Changes of muscle tone, muscle strength of the target muscles, and ROM of the joints involved pre- and post-op

Measures	At pre-op Value (mean, SD)	3 weeks Post-op Value (mean, SD)	At the last follow-up Value (mean, SD)
Muscle tone (grade)			
Gastrocnemius	2.5 ± 0.5	1.7 ± 0.3	1.0 ± 0.4
Soleus	2.2 ± 0.4	1.2 ± 0.3	0.9 ± 0.5
Hamstring	2.2 ± 0.4	1.5 ± 0.4	1.1 ± 0.2
Hip adductor	2.0[a]	1.5 [a]	1.0[a]
Muscle strength (grade)			
Gastrocnemius	4.1 ± 0.3	4.3 ± 0.5	5.0 ± 0.0
Soleus	4.1 ± 0.3	4.2 ± 0.4	4.6 ± 0.5
Hamstring	4.2 ± 0.4	4.0 ± 0.0	4.8 ± 0.4
Hip adductor	4.0[a]	4.0[a]	5.0[a]
ROM of joints involved (degree)			
Passive ROM			
Ankle[b]	44.1 ± 8.9	54.5 ± 7.6	63.6 ± 5.5
Knee[c]	107.0 ± 4.5	119.0 ± 6.5	129.0 ± 8.9
Hip[d]	45.0[a]	55.0[a]	60.0[a]
Active ROM			
Ankle[b]	34.5 ± 9.3	37.7 ± 6.8	50.5 ± 7.2
Knee[c]	97.0 ± 4.5	100.0 ± 3.5	116.0 ± 6.5
Hip[d]	30.0[a]	35.0[a]	50.0[a]

ROM range of motion, *SD* standard deviation

[a] not applicable due to sample size (only in one case)

[b] Dorsal and plantar flexion

[c] Flexion

[d] Abduction with hip flexed

to be associated with the spasticity of those target muscles. Our results suggest that single-level approach SDR is feasible to treat CP cases with spastic hemiplegia when guided by this newly simplified rhizotomy protocol.

Reduction of muscle tone of those target muscles in our cases is satisfactory after SDR when guided by this modified rhizotomy scheme. Among all muscles focused on in our study, muscle tone of gastrocnemius and soleus decreased the most, which completely avoid tendon lengthening surgery in these cases during the follow-up. Decrease of muscle tone of those spastic muscle groups after SDR was widely reported in previous studies since 1980s [12–14]. Our results are comparable with those in the previous studies, though rhizotomy protocols are different. Improvement of muscle strength of those spastic muscles and ROM of joints involved was widely reported in literatures after post-SDR rehabilitation [15, 16]. Though using a modified rhizotomy scheme, muscle strength of those target muscles in our cases increased markedly at an average of 0.7 grades after the following intensive rehabilitation program. ROM of those joints in the current study was observed improved as well. The GMFM-66 is a measurement widely accepted in rehabilitation field to assess motor function in CP cases. In the current study, significant increase of GMFM-66 score in our study was observed after post-SDR rehabilitation at a mean duration of 19 months, particularly in dimensions reflecting motor function in lower limbs of our cases. This result is consistent with others which were published earlier [15, 17, 18]. Interestingly, five of six cases which were with their pre-op GMFCS level II were observed upgrading to level I after post-SDR rehabilitation, which is much better than the previous study [19]. Whether it is due to spastic hemiplegic cases with relatively mild pre-op status, and operated on at a younger age in the current study remains unclear. The comparison of gait kinematics in the cases in our study after post-SDR rehabilitation is encouraging. Besides the major improvement of the pressure patterns on their affected foot to the ground, kinematics of all joints involved in the lower limbs improved significantly during gait cycles after our new protocol-guided SDR and the following rehabilitation program. Major correction of hip external rotation and knee internal rotation were observed in all cases at the last follow-up. Our results are comparable with those in cases managed in the traditional way, though all of those CP cases were diplegic or quadriplegic [20, 21].

Based on our newly modified rhizotomy scheme, we solely section those dorsal rootlets that mainly elicit EMG responses on those spastic muscles. The basis of neuroelectrophysiology of our modified rhizotomy scheme is slightly different from

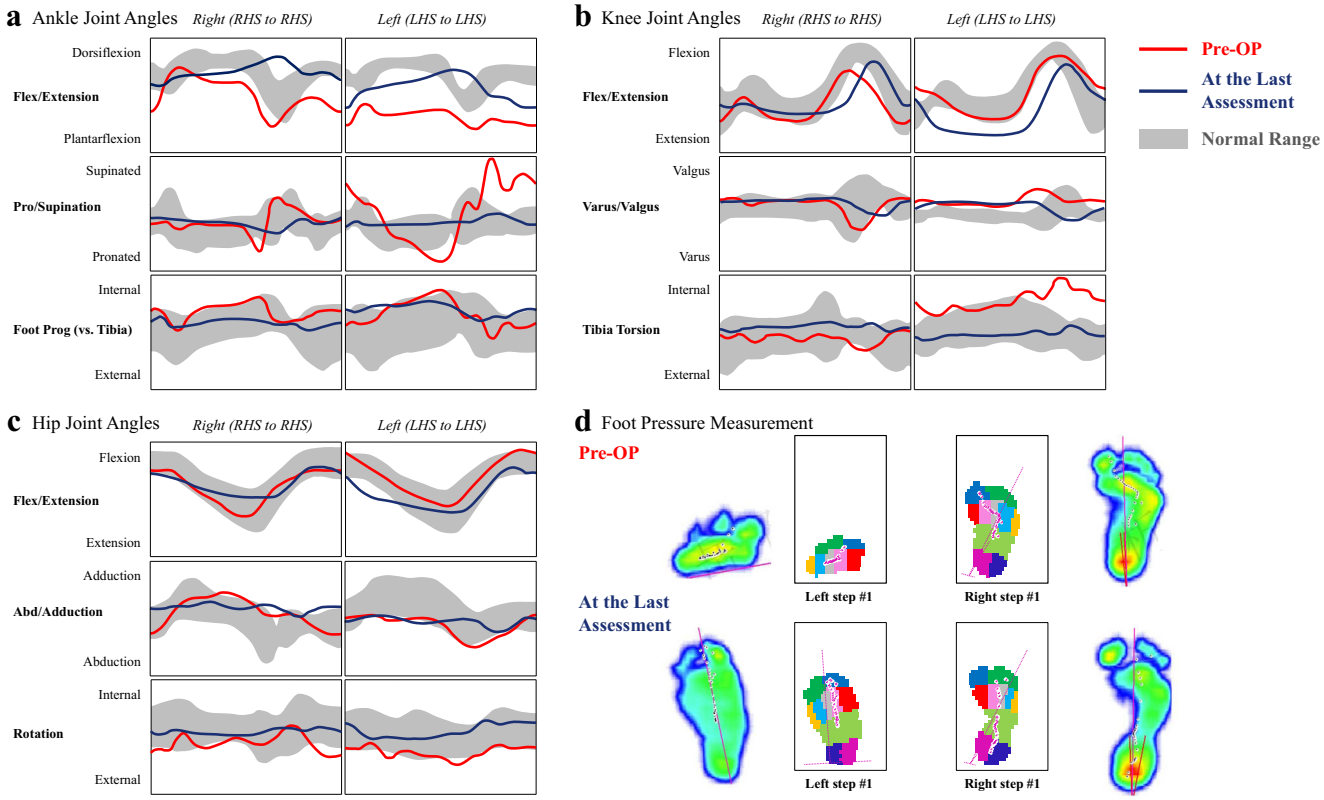

Fig. 2 Part of gait analysis data comparison in a representative case with spastic hemiplegia on his left side (pre and at the last assessment). **a** Improvement of dorsiflexion on the Lt. ankle joint during gait cycles observed postoperatively. **b** Internal tibia torsion on the Lt. side improved dramatically after SDR. **c** Correction of external rotation of Lt. hip joint post SDR observed. **d** Foot pressure pattern on the left side during gait cycles getting better

that of the traditional EMG grading system. When based on the traditional scheme [2], the dorsal rootlet via which electrical stimulation evokes activity in more diffuse electrical circuits of the spinal cord would be taken as the one having more association with limb spasm during daily activity of that patient. While our newly modified scheme is based on the hypothesis that only the dorsal rootlets which have lowest threshold with those spastic muscle among 15 muscles monitored during surgery are associated with spasm in that particular muscle in the physiological condition. Meanwhile, our scheme takes it into account whether input via those rootlets would evoke diffuse activity of electrical circuits in the spinal cord. The reason we take L2 approach is mainly because we believe that this approach can reduce the chance of damage to the conus of the spinal cord, and at the same time completely avoid the possibility of missing the dorsal rootlets.

Cases included in the current study had been undergoing rehabilitation therapy for years before the SDR surgery. Spasticity was still severe in their involved lower extremities after long-term rehabilitation treatment, resulting in unsatisfactory outcomes. Significant reduction of spasticity in those target muscles right after our modified rhizotomy protocol-guided SDR procedure was revealed in our cases (muscle tone 2.3 ± 0.5, pre-SDR, vs. 1.5 ± 0.4, 3 weeks post-SDR), which provided a better condition for the following rehabilitation therapy, leading to a major improvement with regard to their motor function in those cases.

The current study has several limitations. In addition to its retrospective nature, our sample is also small. Therefore, statistical analysis became difficult in the current study with regard to some of our measurements. Moreover, the duration of the follow-up for our cases is relatively short. All of our cases have not yet reached their adolescency. Thus, whether such effectiveness could sustain when their body weight rises remains unclear. Following studies are required to verify our conclusions with more cases, longer follow-up, and better having a control group.

Conclusion

Single-level SDR when guided by our simplified rhizotomy protocol is feasible and effective to treat pediatric CP cases with spastic hemiplegia. Those patients could benefit from such procedure followed by rehabilitation program with regard to their motor function.

Compliance with ethical standards

Conflict of interest None.

References

1. Graham D, Aquilina K, Cawker S, Paget S, Wimalasundera N (2016) Single-level selective dorsal rhizotomy for spastic cerebral palsy. J Spine Surg 2:195–201. https://doi.org/10.21037/jss.2016.08.08
2. Fasano VA, Broggi G, Zeme S (1988) Intraoperative electrical stimulation for functional posterior rhizotomy. Scand J Rehabil Med Suppl 17:149–154
3. Steinbok P, Kestle JR (1996) Variation between centers in electrophysiologic techniques used in lumbosacral selective dorsal rhizotomy for spastic cerebral palsy. Pediatr Neurosurg 25:233–239. https://doi.org/10.1159/000121131
4. Turner RP (2009) Neurophysiologic intraoperative monitoring during selective dorsal rhizotomy. J Clin Neurophysiol 26:82–84. https://doi.org/10.1097/WNP.0b013e31819f9077
5. Georgoulis G, Brînzeu A, Sindou M (2018) Dorsal rhizotomy for children with spastic diplegia of cerebral palsy origin: usefulness of intraoperative monitoring. J Neurosurg Pediatr 22(1):89–101. https://doi.org/10.3171/2018.1.PEDS17577
6. Fasano VA, Broggi G, Barolat-Romana G, Sguazzi A (1978) Surgical treatment of spasticity in cerebral palsy. Childs Brain 4:289–305
7. Peacock WJ, Arens LJ (1982) Selective posterior rhizotomy for the relief of spasticity in cerebral palsy. S Afr Med J 62:119–124
8. Park TS, Gaffney PE, Kaufman BA, Molleston MC (1993) Selective lumbosacral dorsal rhizotomy immediately caudal to the conus medullaris for cerebral palsy spasticity. Neurosurgery 33:929–933. https://doi.org/10.1097/00006123-199311000-00026
9. Park TS, Johnston JM (2006) Surgical techniques of selective dorsal rhizotomy for spastic cerebral palsy. Neurosurg Focus 21:1–6
10. Bales J, Apkon S, Osorio M, Kinney G, Robison RA, Hooper E, Browd S (2016) Infra-conus single-level laminectomy for selective dorsal rhizotomy: technical advance. Pediatr Neurosurg 51:284–291. https://doi.org/10.1159/000448046
11. Kothbauer KF, Deletis V (2010) Intraoperative neurophysiology of the conus medullaris and cauda equine. Childs Nerv Syst 26:247–253. https://doi.org/10.1007/s00381-009-1020-6
12. Arens LJ, Peacock WJ, Peter J (1989) Selective posterior rhizotomy: a long-term follow-up study. Childs Nerv Syst 5:148–152
13. Mittal S, Farmer JP, Al-Atassi B, Montpetit K, Gervais N, Poulin C, Benaroch TE, Cantin MA (2002) Functional performance following selective posterior rhizotomy: long-term results determined using a validated evaluative measure. J Neurosurg 97:510–518
14. Dudley RW, Parolin M, Gagnon B, Saluja R, Yap R, Montpetit K, Ruck J, Poulin C, Cantin MA, Benaroch TE, Farmer JP (2013) Long-term functional benefits of selective dorsal rhizotomy for spastic cerebral palsy. J Neurosurg Pediatr 12:142–150. https://doi.org/10.3171/2013.4.PEDS12539
15. Josenby AL, Wagner P, Jarnlo GB, Westbom L, Nordmark E (2012) Motor function after selective dorsal rhizotomy: a 10-year practice-based follow-up study. Dev Med Child Neurol 54:429–435. https://doi.org/10.1111/j.1469-8749.2012.04258.x
16. Munger ME, Aldahondo N, Krach LE, Novacheck TF, Schwartz MH (2017) Long-term outcomes after selective dorsal rhizotomy: a retrospective matched cohort study. Dev Med Child Neurol 59:1196–1203. https://doi.org/10.1111/dmcn.13500
17. Nordmark E, Josenby AL, Lagergren J, Andersson G, Strömblad LG, Westbom L (2008) Long-term outcomes five years after selective dorsal rhizotomy. BMC Pediatr 8(54). https://doi.org/10.1186/1471-2431-8-54
18. Bolster EA, van Schie PE, Becher JG, van Ouwerkerk WJ, Strijers RL, Vermeulen RJ (2013) Long-term effect of selective dorsal rhizotomy on gross motor function in ambulant children with spastic bilateral cerebral palsy, compared with reference centiles. Dev Med Child Neurol 55:610–616. https://doi.org/10.1111/dmcn.12148
19. Romei M, Oudenhoven LM, van Schie PEM, van Ouwerkerk WJR, van der Krogt MM, Buizer AI (2018) Evolution of gait in adolescents and young adults with spastic diplegia after selective dorsal rhizotomy in childhood: a 10 year follow-up study. Gait Posture 64:108–113. https://doi.org/10.1016/j.gaitpost.2018.06.002
20. Grunt S, Henneman WJ, Bakker MJ, Harlaar J, van der Ouwerkerk WJ, van Schie P, Reeuwijk A, Becher JG, Vermeulen RJ (2010) Effect of selective dorsal rhizotomy on gait in children with bilateral spastic paresis: kinematic and EMG-pattern changes. Neuropediatrics 41:209–216. https://doi.org/10.1055/s-0030-1267983
21. Oudenhoven LM, van der Krogt MM, Romei M, van Schie PEM, van de Pol LA, van Ouwerkerk WJR, Harlaar J, Buizer AI (2018) Factors associated with long-term improvement of gait after selective dorsal rhizotomy. Arch Phys Med Rehabil 100:474–480. https://doi.org/10.1016/j.apmr.2018.06.016

Publisher's note Springer Nature remains neutral with regard to jurisdictional claims in published maps and institutional affiliations.