References

1. Brandt T. Vertigo: Its Multisensory Syndromes. Munich: Springer Science & Business Media; 2013.
2. Westheimer G, Blair SM. The ocular tilt reaction—a brainstem oculomotor routine. Invest Ophthalmol 1975;14:833-9.
3. Brandt T, Dieterich M. Skew deviation with ocular torsion: a vestibular brainstem sign of topographic diagnostic value. Ann Neurol 1993;33:528-34.
4. Parulekar MV, Dai S, Buncic JR, Wong AM. Head position–dependent changes in ocular torsion and vertical misalignment in skew deviation. Arch Ophthalmol 2008;126:899-905.
5. Dieterich M, Brandt T. Ocular torsion and tilt of subjective visual vertical are sensitive brainstem signs. Ann Neurol 1993;33:292-9.
6. Brodsky MC, Holmes JM. Torsional augmentation for the treatment of lateropulsion and torticollis in partial ocular tilt reaction. J AAPOS 2012;16:141-4.
7. Wong AM, Colpa L, Chandrakumar M. Ability of an upright-supine test to differentiate skew deviation from other vertical strabismus causes. Arch Ophthalmol 2011;129:1570-75.
8. Frisén L. Practical estimation of ocular torsion and the subjective vertical. Neuro-ophthalmol 2000;23:195.
9. Zwergal A, Rettinger N, Frenzel C, Dieterich M, Brandt T, Strupp M. A bucket of static vestibular function. Neurology 2009;72:1689-92.
10. von Noorden GK, Jenkins RH, Rosenbaum AL. Horizontal transposition of the vertical rectus muscles for treatment of ocular torticollis. J Pediatr Ophthalmol Strabismus 1993;30:8-9.

Angiostrongylus—a technique for removing a rare parasite from the cornea of a child

Pradhnya Sen, MBBS, MS, Ashok Date, MBBS, MS, Elesh Jain, DOMS, DNB, and Amit Mohan, MS, FAICO

We report a case of an Angiostrongylus parasite in the corneal stroma in an 8-year-old boy and our technique for its removal. The parasite was identified on slit-lamp examination. Its location was confirmed on anterior segment optical coherence topography (AS-OCT). The parasite was found on the superficial corneal stroma in the periphery and was removed after lamellar dissection of the cornea following marking with trephine.

Author affiliations: Pediatric Ophthalmology and Strabismus, Sadguru Netra Chikitsalaya and Post Graduate Institute of Ophthalmology, Chitrakoot, Madhya Pradesh, India

Submitted August 24, 2018.
Revision accepted November 13, 2018.
Published online February 12, 2019.

Correspondence: Dr. Pradhnya Sen, MBBS, MS, Consultant and Head of Department, Pediatric Ophthalmology and Strabismus, Sadguru Netra Chikitsalaya and Post Graduate Institute of Ophthalmology, Jankikund, Chitrakoot, MP, India (email: drpradhnyasen@rediffmail.com).

J AAPOS 2019;23:119-120.

Copyright © 2019, American Association for Pediatric Ophthalmology and Strabismus. Published by Elsevier Inc. All rights reserved.

1091-8531/$36.00
https://doi.org/10.1016/j.jaapos.2018.11.005

Case Report

An 8-year-old boy presented at Children Eye Care Centre, Sadguru Netra Chikitsalya, Chitrakoot, with a complaint of foreign body sensation, redness, and diminished vision in his right eye for the previous 4 days, following traumatic injury with a wooden object. On examination, his best-corrected visual acuity was 20/60 in the right eye and 20/20 in the left eye. Intraocular pressure was 14 mm Hg in each eye by noncontact tonometer. Slit-lamp examination revealed circumcorneal congestion in the right eye, and two white, coiled structures with a tracklike appearance from 10 to 12 o'clock in the peripheral superficial corneal stroma, with surrounding infiltrates (Figure 1). The anterior chamber showed a fibrinous reaction, the pupil was round and reactive to light, and the lens was clear. The left eye was normal. Dilated fundus examination of both eyes was within normal limit.

Anterior segment optical coherence topography (AS-OCT) revealed two linear opacities in the superficial stroma (Figure 2). One was within 181 μm and the other within 131 μm of the anterior surface. Systemic examination did not reveal any abnormality. Routine blood investigations, x-ray chest, abdominal ultrasound, and stool examination were within normal limits. A provisional diagnosis of corneal parasite was made, and surgical excision under general anesthesia was planned with cover of systemic and topical medications (albendazole, 15 mg/kg tablet; prednisolone 1 mg/kg tablet; moxifloxacin and dexamethasone eye drops 4 times daily; atropine ointment at bedtime).

The area containing the parasite was removed with a 4 mm corneal trephine. The segment was elevated using a crescent blade (Figure 3), and the worm was removed whole; a sample was sent for histopathological examination. The parasite was identified as *Angiostrongylus cantonensis*. The patient's status improved significantly following treatment, with resolution of anterior uveitis and healing of the corneal defect within 7 days (Figure 4). At 6 weeks' follow-up the eye had quieted, and visual acuity was 20/20 in each eye.

Discussion

Angiostrongylus is a rodent lungworm commonly encountered in Southeast Asian countries. It is a well-recognized cause of eosinophilic meningitis in many Pacific islands and in Southeast Asia.[1] The parasite normally cycles between rodents and several land mollusks. Rodents are the definitive hosts; mollusks or snails are intermediate hosts. It is thought that human infection occurs following ingestion of undercooked infected snails or raw vegetables contaminated by larvae from mollusks.[2] Ocular

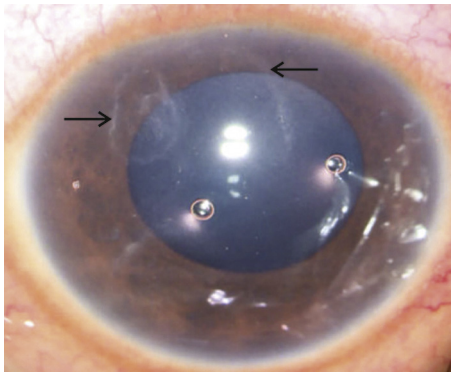

FIG 1. Worm in superficial corneal stroma.

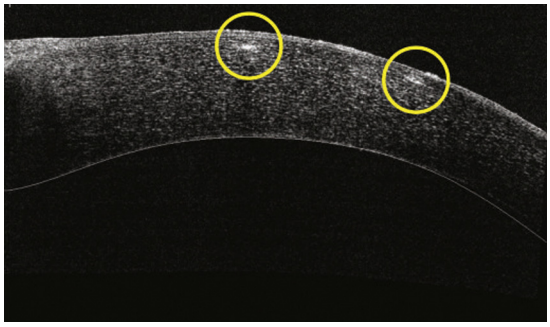

FIG 2. Anterior segment optical coherence tomography showing two linear opacities in the superficial stroma.

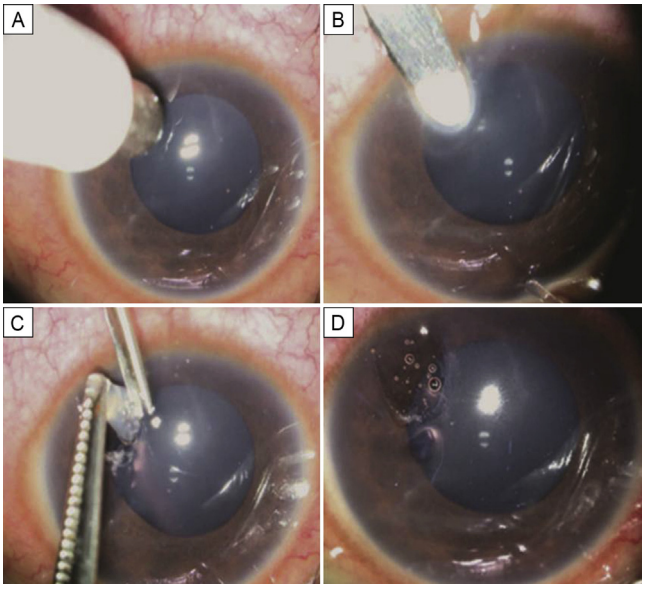

FIG 3. Intraoperative steps in removal of worm. A, Marking with trephination. B, Elevating the flap with crescent blade. C, Removal of worm along-with flap. D, Raw abraded cornea after worm removal.

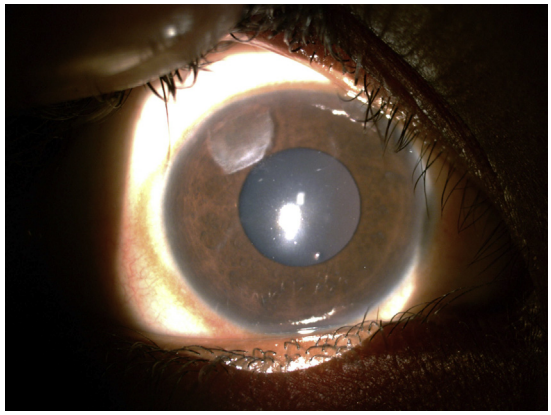

FIG 4. Postoperative photograph of patient at 1-week follow up.

angiostrongyliasis has been reported in various countries worldwide.[3,4] Ocular findings includes uveitis, subretinal tracks, retinal detachment, optic neuritis, necrotizing retinitis, granulomatous hypertensive uveitis, iritis, keratitis and extraocular muscle palsies. Recovery of live worm has been reported from the anterior chamber, vitreous cavity and the subretinal space.[5,6] To our knowledge this is the first report of isolating a worm from corneal stroma by means of trephination. Treatment includes chemoparalysis with lidocaine or immobilization with cryoprobe, diode, or YAG laser photocoagulation. We performed surgical excision because the worm was in the peripheral superficial stroma. Albendazole or mebendazole is indicated if systemic infection is present.[7]

Literature Search

PubMed was searched last on February 2, 2019, without date or language restriction, using the following terms: *cornea* AND *Angiostrongylus*, *Angiostrongylus cantonensis* AND *worm removal*.

References

1. Alicata JE. The discovery of *Angiostrongylus cantonensis* as a cause of human eosinophilic meningitis. Parasitol Today 1991;7:151-3.
2. Ash LR. Observations on the role of mollusks and planarians in the transmission of *Angiostrongylus cantonensis* infection to man in New Caledonia. Rev Biol Trop 1976;24:163-74.
3. Diao Z, Wang J, Qi H, Li X, Zheng X, Yin C. Human ocular angiostrongyliasis: a literature review. Trop Doct 2011;41:76-8.
4. Thu TP, Nguyen NX, Lan le T, Küchle M. Ocular *Angiostrongylus cantonensis* in a female Vietnamese patient: case report. Klin Monbl Augenheilkd 2002;219:892-5 [in German].
5. Wang QP, Lai DH, Zhu XQ, Chen ZG, Lunn ZR. Human angiostrongyliasis. Lancet Infect Dis 2008;8:621-30.
6. Tiwari US, Aishwarya A, Gandhi S, Sisodia P. *Angiostrongylus cantonensis* in anterior chamber. Indian J Ophthalmol 2019;67:158-60.
7. Zanini GM, Graeff-Teixeira C. Inactivation of infective larvae of *Angiostrongylus costaricensis* with short time incubations in 1.5% bleach solution, vinegar or saturated cooking salt solution. Acta Trop 2001;78:17-21.