Journal of Arthroscopy and Joint Surgery 6 (2019) 42–47

Contents lists available at ScienceDirect

Journal of Arthroscopy and Joint Surgery

journal homepage: www.elsevier.com/locate/jajs

Avoiding complications in elbow arthroscopy

William D. Harrison [a,*], Xenia Tonge [a], Vijay Bhalaik [b]

[a] Health Education England North-West, Mersey Deanery, Summers Rd, Liverpool, L3 4BL, UK
[b] Wirral University Hospital Trust, Arrowe Park Road, The Wirral, UK

ARTICLE INFO

Article history:
Received 29 November 2018
Accepted 1 January 2019
Available online 2 January 2019

Keywords:
Elbow arthroscopy
Complications
Indications
Anatomy

ABSTRACT

The elbow joint is a complex anatomical structure and is susceptible to a wide variety of complex pathologies, ranging from traumatic to inflammatory. Elbow arthroscopy is a challenging procedure with a steep learning curve and a high risk of iatrogenic injury. The indications for arthroscopic elbow surgery are discussed in this article, along with a suggested comprehensive surgical technique, including patient set-up and steps to avoid iatrogenic damage. There is detailed explanation of specific portal sites, with advantages and disadvantages of each, as well as the anatomical considerations. This article also reviews the available literature regarding the frequency of complications and in particular; nerve injury and ways in which they may be avoided.
Crown Copyright © 2019 Published by Elsevier, a division of RELX India, Pvt. Ltd on behalf of International Society for Knowledge for Surgeons on Arthroscopy and Arthroplasty. All rights reserved.

1. Introduction

Elbow arthroscopy is a challenging procedure, used for a variety of increasingly complex elbow pathologies. The elbow is complex hinge joint and is composed of the humeroulnar, humeroradial and radioulnar joints. It has tight access with a small working space, large fat pads and is bordered by important and delicate anatomical structures. The elbow contributes heavily towards upper limb function and can be compromised from seemingly innocuous pathologies and poor rehabilitation.

The theoretical advantages of arthroscopic surgery include decreased post-operative pain, improved articular diagnostic assessment, reduced heterotrophic ossification, better cosmesis and decreased morbidity. According to O'Driscoll et al.'s large case series from 1992, arthroscopy has a diagnostic benefit in over two-thirds of patients and a therapeutic benefit occurs in 60–95% of patients.[1]

The evidence base of elbow arthroscopy compared to that of the knee and the shoulder is much less established. The merits of arthroscopic assessment and treatment of the elbow are countered however, by a relatively high iatrogenic complication rate.[1] The risk of neurovascular injury in particular, compromises the regular use of elbow arthroscopy. As such, the indications for surgery remain quite controversial. An understanding of the pathoanatomy of the elbow is crucial to successful surgery and the procedure. Gaining experience in elbow arthroscopy can be challenging due to the infrequency of cases. Quantifying the learning curve is difficult, however, experience is important factor for good outcomes.

1.1. Current indications for elbow arthroscopy

The indications for elbow arthroscopy largely depend on the experience of the arthroscopist. Patient selection in elbow surgery is a key component to achieving good results. The most common broad indications in adults, with satisfactory outcomes include: debridement or fixation of osteochondral defects, clearance of posterior impingement and arthroscopic release of the post-traumatic stiff elbow, including plica.[2] Elbow arthroscopy is also an excellent option for debridement for septic elbow arthritis, synovectomy for inflammatory arthritis, loose body extraction and debridement for osteoarthritis.[3] See Table 1.

Elbow arthroscopy is also a valid option in the management of paediatric and adolescent pathologies. Micheli et al. reviewed their practice of paediatric elbow arthroscopy showing their paediatric indications as follows: osteochondritis dessicans (58%), arthrofibrosis (20%), synovitis (10%), acute trauma (10%) and posterior olecranon impingement syndrome (10%).[4]

There is debate about the efficacy of arthroscopic tennis elbow release. A randomised, double-blind sham-controlled trial has been set-up (awaiting results) in order to compare arthroscopic release of extensor carpi radialis brevis (ECRB) with sham surgery.[5]

* Corresponding author.
E-mail addresses: will.d.harrison@gmail.com (W.D. Harrison), xenia.tonge@doctors.org.uk (X. Tonge), vijaybhalaik@nhs.net (V. Bhalaik).

https://doi.org/10.1016/j.jajs.2019.01.001
2214-9635/Crown Copyright © 2019 Published by Elsevier, a division of RELX India, Pvt. Ltd on behalf of International Society for Knowledge for Surgeons on Arthroscopy and Arthroplasty. All rights reserved.

Table 1
Current indications for elbow arthroscopy.[2–7]

Common	Uncommon
Debridement of osteophytes	ECRB release
Release of soft tissue contractures	Adjunct to fracture fixation
Synovectomy	Diagnostic
Osteochondral defect management	
Washout for septic arthritis	
Removal of loose bodies	
Assessment of valgus instability	

The role of elbow arthroscopy as a diagnostic tool compared to established radiological options is controversial.[6] The authors' view is that a clear surgical target should be identified pre-operatively, given the high reported iatrogenic injury rates from the procedure itself. Therefore, it is recommended that the surgeon and the patient fully understand the diagnosis, the rationale and the surgical goals for elbow arthroscopy prior to undergoing the procedure.

Acute elbow trauma can also be managed arthroscopically, although much less frequent than elective indications. In a review article of 13 publications, van Tongel et al. summarised the use of arthroscopy in fracture management to include displaced radial head fractures, coronoid and capitellum fractures in adults and displaced radial neck and lateral humeral condyle fractures in children.[7] Soft tissue reconstruction in the form of distal biceps repair, medial avulsion of triceps repair and reconstruction of the radial ulnohumeral ligamentous complex have also been published.[7] These procedures are not mainstream and they have little evidence to support their efficacy. These indications are not recognised by the senior author.

As our understanding of elbow pathoanatomy is improving, surgical indications will continue to evolve and elbow arthroscopy is becoming a mainstream specialist procedure. Many indications for this surgery still pose considerable controversy and there is a paucity of level I and II research to provide guidance. Other areas of established arthroscopic practice; such as arthroscopy in the degenerative knee, and more recently, subacromial arthroscopic shoulder decompression have been shown to be less effective than previously thought.[8,9] The importance of these studies are to better understand the role of arthroscopic surgery in specific patient groups and guide patient selection.

1.2. Anatomical considerations

An understanding of the surface anatomy of the elbow is fundamental to safe portal positioning and understanding risk when using instruments inside the joint. Portal landmarks are discussed in detail in the next section. It is important to acknowledge that normal and pathological variants in the neuroanatomy exist around the elbow and that extravasation of fluid and other intra-operative circumstances can alter the usual pathway of the nerves. Also, it very important to recognise that the neuroanatomy dynamically changes through flexion-extension and pro-supination.

Unlu et al. performed a cadaveric study of 20 specimens using Steinmann pins to simulate an arthroscopy portal. The proximity of the neurovascular structures to the pins was measured in five different positions. The radial nerve is considered a high risk structure, particularly from the anterolateral portal. The radial nerve showed significant proximity to the anterolateral portal in full elbow flexion, full elbow extension, and forearm supination. Although we pronate the forearm to protect the posterior interosseous nerve (PIN) during open surgery, there is evidence to suggest that supination translates the PIN further from the joint capsule, and is preferred for arthroscopic surgery when working near the anterior capsule of the radial head.[10]

The distance between the median nerve and anterior portals was significantly decreased with full extension.[11] There was a significant 10–20% nerve-pin contact in their cadaveric series, although this does not correlate with the post-operative clinical manifestation of transient nerve injury after elbow arthroscopy which was quoted at 1.7% in a series of 416 patients.[12] The median nerve and brachial artery are at relatively low risk of injury as they are protected by brachialis and theoretically, the lateral decubitus positioning will allow the neurovascular structures to move anteriorly due to gravity.

Miller et al. looked at the relationship of nerves to the capsule after insufflation and also at varying degrees of flexion.[13] The key messages from the paper were that insufflation improved the distance of the nerve from the bone, however it did not displace the nerve from the capsule. This has implications for intra-articular debridement near the capsule, that may lead to nerve injury - known as a "from within-out injury".

The ulnar nerve lies on the medial head of triceps and posterior to the medial intermuscular septum. At the level of the elbow, it sits superficial to the capsule and the medial collateral ligament. The ulnar nerve is at risk in posterior compartment surgery, particularly if the instruments over penetrate through the capsule. The ulnar nerve also significantly limits instrumentation in the medial gutter.

1.3. Portals

Not only is it important to mark out the portals pre-operatively, but also to assess all available radiological imaging and to make a plan based on pathology for the likely portal utilisation and sequence during the case.

The nomenclature of the elbow portals has varied between literature sources and also over time, as the use of certain portals have gone out of favour. Table 2 describes the commonly used nomenclature of the portals and further discussion of the landmarks, hazards and uses are described below.

1.4. Medial portal

The anteromedial portal is 2 cm anterior and 2 cm proximal to the medial epicondyle and should be just anterior to the medial intermuscular septum. The trajectory of the trochar is towards the radial head and the advice is to stay on the bone. It provides an excellent view to the entire anterior compartment of the elbow and also the medial gutter. The anteromedial portal avoids damage to the medial antebrachial cutaneous nerve, however it lies 4–14 mm from the medial nerve and 9–17 mm from the brachial artery.[14] Avoiding extension at the time of portal creation is important as it has been shown to obliterate the bone-to-nerve distance in experimental cadaveric studies, making the risk of iatrogenic injury much higher. Pro-supination is ideally in a neutral position to avoid radial nerve damage from the anteromedial portal.[10] The portal is therefore made at 90° flexion and

Table 2
Commonly used portals for elbow arthroscopy.

Medial	Posterior	Lateral
Anteromedial (also known as proximo-medial)	Posterocentral	Anterolateral
	Posterolateral	Proximal-lateral Midlateral (soft-spot) Accessory lateral

in neutral supination and the blunt trochar passes between the humerus and brachialis, which acts as a protective cushion to the anterior neurovascular structures.

1.5. Lateral portals

The anterolateral portal lies at proximal border of the lateral epicondyle and also approximately 1 cm anterior to the lateral epicondyle. Once again, care must be taken to avoid injury to the radial nerve which lies between 4 and 11 mm from this portal.[14] This portal is best made under direct vision, using an inside-out technique to avoid radial nerve injury. It is safe to pass the instruments from an anterolateral to posteromedial orientation, rather than entering the joint by pushing across transversely towards the neurovascular structures.

The proximal lateral portal is 1 − 2 cm proximal to the lateral epicondyle and is anterior to the lateral column of the distal humerus and is considered the safest portal to use. The proximal lateral portal in particular gives good visualisation of the entire anterior compartment including the lateral recess, medial capsule, coronoid process and anterior humeral fossa.

The midlateral utilises the same entry point and trajectory as the initial insufflation needle in the soft-spot of the elbow, in the middle of triangle of the lateral olecranon, the radial head and the lateral epicondyle. The main structure at risk is the posterior antebrachial cutaneous nerve. It is used in each case for the insufflation of the joint capsule and can also be used as a visualisation and instrumentation portal for the inferior radiocapitellar joint and radioulnar joint.

Accessory lateral portals can be placed around the areas between the posterolateral (described below) and the midlateral portals. They provide alternative access to pathologies of the radiocapitellar joint and can be considered an augment to visualisation or difficult access for instrumentation in this tight area.

1.6. Posterior portals

The posterolateral portal is 2–3 cm proximal from the tip of the olecranon in the 90° flexed elbow and lies on the lateral border of the triceps tendon. The structures at risk with this portal are the medial and posterior antebrachial cutaneous nerves, however it is also considered a relatively safe portal. It gives good visualisation of the entire posterior compartment and the lateral gutter with access to the radiocapitellar joint. It is the primary posterior portal in most cases.

The posterocentral portal is in the midline of the elbow, 3 cm proximal to the tip of the olecranon. It is a safe portal and penetrates through the triceps tendon. It uses are for visualisation and instrumentation of the olecranon tip, the humeral fossa and the humeral trochlea. It can also be used to assess the medial gutter and for safe removal of loose bodies found in the posterior compartment.

1.7. Surgical technique

Surgical technique is not prescriptive, but the following are a series of recommendations to reduce the risk of iatrogenic injury. Clinical reassessment should be performed on the day of surgery to assess the overlying skin, the range of movement in the elbow, range of movement in the shoulder and a full neurovascular assessment. Deformity and the chronically contracted elbow are important to recognise pre-operatively at it can lead to aberrant position of the neurovascular structures.[2] A subluxating ulnar nerve may also be identified clinically and is best felt proximal to the medial epicondyle.[15]

The first step is an examination under anaesthesia of the elbow assessing the range of movement and evidence of instability. Options for positioning include supine, prone and lateral decubitus. Positioning for arthroscopy is usually in the lateral decubitus position with elbow in 90° flexion, which is the senior authors preferred method (See Fig. 1). Lateral decubitus, or even prone positioning, make the posterior compartment more accessible and the limb more stable during work. The lateral position theoretically may allow the anterior neurovascular structures to move away from the capsule by gravity.

The advantage of the supine position is a more anatomic position, easier to convert to an open medial collateral ligament reconstruction and it is easier for the anaesthetist. The

Fig. 1. Patient positioning. Lateral decubitus with a Mayo table over the patient for tool placement and an arm bolster to bring the elbow to 90° of flexion.

disadvantages of supine positioning include the set-up for limb suspension, stability of the arm whilst working, and difficulty accessing the posterior compartment.

An above-elbow tourniquet is placed with an impervious shut-off drape. Chinese finger traps provide excellent hold of the distal upper limb. Landmarks are drawn up; the olecranon, triceps tendon, medial and lateral epicondyles, radial head and the likely paths of the ulnar, radial/posterior interosseous and median nerves (see Figs. 2–4). It is better to define landmarks and all portals at the start, rather than halfway through the procedure when swelling can compromise accuracy. A Mayo table can be placed over the midriff portion of the patient to enable the passage of instruments and improve ergonomics.

The WHO checklist and exsanguination of the limb are performed and the forearm is bound with a crepe bandage. It is recommended that the bandage is not too tight as it can lead to neuropraxia. Insufflation of the joint is performed using a 20 ml syringe of normal saline to the midlateral portal described as the soft spot in the middle of triangle of the lateral olecranon, the radial head and the lateral epicondyle (see Fig. 5). Joint insufflation increases the bone-to-nerve distance by 12 mm for median nerve and 6 mm for radial nerve and reduces the risk of damage at the portal site.[13] It is however, important to note that joint insufflation does not increase the capsule-to-nerve distance.[13] This is important as intra-operative diathermy and instrumentation near the capsule can easily lead to nerve damage. Confirmation of joint insufflation is made by seeing fullness in the olecranon fossa and re-filling of the syringe once thumb pressure is removed (indicating that the fluid has not extravasated into the soft tissues). (See Fig. 6).

The dermal layer only is incised with a 15 blade and then systematic and careful blunt dissection is made down to the joint capsule in a "nick and spread technique". The elbow capsule is breached with a blunt trocar (see Fig. 7), at which point saline will

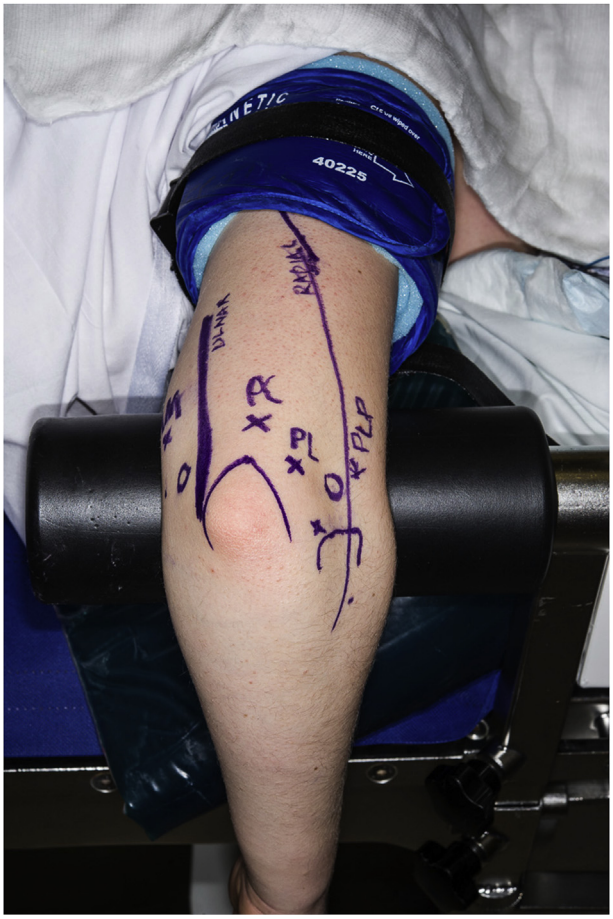

Fig. 2. Surface landmarks – posterior view. PC refers to the posterocentral portal and PL is the posterolateral portal.

Fig. 3. Surface landmarks – lateral view. PLC refers to the proximolateral portal. Note the area of the midlateral portal (soft spot), marked with an "X" and the relation of the radial nerve to the PLC.

Fig. 4. Surface landmarks – medial view. AM refers to the anteromedial portal which is adjacent to the ulnar nerve.

Fig. 5. Joint insufflation into the midlateral portal (soft spot) with a 20 ml syringe.

Fig. 6. Confirmation of joint insufflation, with a jet of saline seen after the removal of the syringe. The needle can be left in situ and used as an irrigation portal.

Fig. 7. Access to the anteromedial portal. Initially with a "nick and spread" technique followed by a blunt trochar to access the joint. Note the arm is at 90° flexion.

pass through the portal. A 4.5 mm scope using a low-flow cannula is passed into the joint and pressurised with 30 mmHg of irrigating fluid. Avoid high pressures within the elbow as it can easily lead to capsule rupture. A smaller scope, such as a 2.7 mm may be used for posterior portals and paediatric patients. Using a scope with no perforations near the tip can reduce intraoperative extravasation. Excessive fluid pressure and prolonged operating time can lead to capsular damage, intra-articular bleeding and extravasation of fluid. All these factors can contribute inadvertent neurovascular damage. The most important step in fluid management is balancing the inflow and the outflow. A tip for reducing extravasation volumes is to gently bind the forearm intraoperative with a bandage. Once the procedure is complete, the unwrapping of the forearm will allow locally high pressure extravasation at the portals to easily diffuse into the remainder of the forearm. Factors that reduce the operative time include the ergonomics of the set-up, the experience of the surgeon, the assistant and the scrub team. The elbow is re-examined after the procedure to assess the range of movement, particularly for impingement and stiffness indications.

Once the scope is within the joint, intra-operative principles to reduce iatrogenic damage include portal placement under direct vision (particularly the anterolateral portal), gentle movement within the joint to avoid chondral damage, avoidance of suction shaver or diathermy near the anterior capsule of the elbow and always debride under direct vision. Hooded burrs reduce the risk of inadvertent iatrogenic injury and focus the mind to a smaller area of activity. The efficient use of portals allows better visualisation and access to various areas of the joint. Decision making of portal use comes with experience. Moving between portals requires care and can be supplemented by using retractors or sheaths to pass the scope over. The same care needs to be taken when re-utilising a portal as when it was first created. Infiltration of the local anaesthetic to the joint can be a useful option for analgesia, but has a risk of transient postoperative nerve palsy from extravasation of fluid from the joint capsule to the surrounding nerves.

1.8. Complications

A number of case reports and small series have reported traumatic nerve palsies with an alarming frequency. The mainstay of the current literature on elbow arthroscopy explore the indications and the nuance of portal positioning. There are no randomised controlled trials assessing the efficacy of elbow arthroscopy.

Two large retrospective series report over 800 cases of elbow arthroscopy and give us the best insight into the risks of surgery – which are discussed below.[12,16] The indications for surgery from both articles pooled from a wide range of inflammatory, degenerative and traumatic aetiologies, with a variety of intra-operative procedures being undertaken in both series.

The superficial infection rates ranged from 7 to 11% and deep infection from 0.8 to 2.2%.[12,16] The use of intraoperative steroid injection had a significant contribution towards the development of infection ($P < 0.0001$).[12]

Persistent contracture of <20° occurred in 1.5% of cases and half of these required return to theatre for manipulation as a second procedure. There were no cases in either series of persistent post-operative contracture >20°.[12,16]

There is speculation that major nerve palsies are under-reported in the literature following elbow arthroscopy.[17] Kelly et al. reported 2.5% (12/473) had transient nerve palsies.[16] The nerve palsies were broken down into; five ulnar palsies (1%), four superficial radial palsies (0.8%), one posterior interosseous palsy (0.2%), one medial antebrachial cutaneous palsy (0.2%), and one anterior interosseous palsy (0.2%). An underlying diagnosis of rheumatoid arthritis ($p < 0.001$) and a pre-operative contracture ($p < 0.05$) proved to be the most significant risk factor for nerve palsy. This low rate of transient nerve palsy was mirrored in the paper by Nelson et al. who reported just 1.7% (7/417) cases developing these temporary symptoms.[12] There were no persistent neurological injuries in either series, nor any complication of vascular injury, haematoma or compartment syndrome.[12,16]

"Major complications" occurred in 5% of cases, often requiring further surgery. The indications for return to theatre included washout for deep infections (9/473), heterotrophic ossification (6/473), and manipulation under anaesthesia for persistent contracture (4/473).[16]

Nelson et al. adjusted for the case complexity against the presence of complications and concluded that "complexity does not appear to affect the rate of complications with modern surgical techniques".[12] However, these types of post-hoc subgroup analyses are fraught with type II error and therefore are not reliable.

1.9. Checklist of recommendations to reduce risks of surgery

1. Pre-operative physical examination to assess for deformity and subluxating ulnar nerve
2. Marking of anatomic landmarks and likely portals
3. Pre-operative joint capsule distension
4. Portal placement with the elbow at 90°
5. Use of a "nick and spread" technique

6. Place portals under direct vision when possible
7. Recognise that the neuroanatomy is dynamic with elbow movement
8. Avoiding radiofrequency diathermy and burring with suction when in the proximity of nerves; especially in the posteromedial corner and anterior capsule
9. Familiarity with the advantages of, preferably, five portals.[2]

Declarations of interest

None.

Conflicts of interest

This research did not receive any specific grant from funding agencies in the public, commercial, or not-for-profit sectors.

Appendix A. Supplementary data

Supplementary data to this article can be found online at https://doi.org/10.1016/j.jajs.2019.01.001.

References

1. O'Driscoll SW, Morrey BF. Arthroscopy of the elbow. Diagnostic and therapeutic benefits and hazards. *J Bone Joint Surg Am*. 1992;74(1):84–94.
2. Doornberg JN, Bexkens R, Thé B, Eygendaal D. Arthroscopy of the elbow. *Orthop Traumatol*. 2016;30(4):301–309. https://doi.org/10.1016/j.mporth.2016.07.001.
3. Adams JE, King GJ, Steinmann SP, Cohen MS. Elbow arthroscopy: indications, techniques, outcomes, and complications. *J Am Acad Orthop Surg*. 2014;22(12):810–818. https://doi.org/10.5435/jaaos-22-12-810.
4. Micheli LJ, Luke AC, Mintzer CM, Waters PM. Elbow arthroscopy in the pediatric and adolescent population. *Arthroscopy*. 2001;17(7):694–699. https://doi.org/10.1053/jars.2001.25338.
5. Matache BA, Berdusco R, Momoli F, Lapner PLC, Pollock JW. A randomized, double-blind sham-controlled trial on the efficacy of arthroscopic tennis elbow release for the management of chronic lateral epicondylitis. *BMC Muscoskelet Disord*. 2016;17(1):239. https://doi.org/10.1186/s12891-016-1093-9.
6. Torabi M, Martell B, Tuohy C, Lenchik L. Mri–arthroscopy correlation of the elbow: a primer for radiologists. *Curr Radiol Rep*. 2016;4(2):10. https://doi.org/10.1007/s40134-015-0137-5.
7. van Tongel A, Macdonald P, van Riet R, Dubberley J. Elbow arthroscopy in acute injuries. *Knee Surgery. Sport Traumatol Arthrosc*. 2012;20(12):2542–2548. https://doi.org/10.1007/s00167-012-1904-y.
8. Sihvonen R, Paavola M, Malmivaara A, et al. Arthroscopic partial meniscectomy versus sham surgery for a degenerative meniscal tear. *N Engl J Med*. 2013;369(26):2515–2524. https://doi.org/10.1056/NEJMoa1305189.
9. Beard DJ, Rees JL, Cook JA, et al. Arthroscopic subacromial decompression for subacromial shoulder pain (CSAW): a multicentre, pragmatic, parallel group, placebo-controlled, three-group, randomised surgical trial. *Lancet*. 2018 Jan 27;391(10118):329–338.
10. Arrigoni P, Cucchi D, Menon A, et al. The posterior interosseous nerve crosses the radial head midline and increases its distance from bony structures with supination of the forearm. *J Shoulder Elbow Surg*. 2018;Nov(18):S1058–S2746. https://doi.org/10.1016/j.jse.2018.08.019, 30614-1.
11. Unlu MC, Kesmezacar H, Akgun I, Ogut T, Uzun I. Anatomic relationship between elbow arthroscopy portals and neurovascular structures in different elbow and forearm positions. *J Shoulder Elbow Surg*. 2006;15(4):457–462. https://doi.org/10.1016/j.jse.2005.09.012.
12. Nelson GN, Wu T, Galatz LM, Yamaguchi K, Keener JD. Elbow arthroscopy: early complications and associated risk factors. *J Shoulder Elbow Surg*. 2014;23(2):273–278. https://doi.org/10.1016/j.jse.2013.09.026.
13. Miller CD, Jobe CM, Wright MH. Neuroanatomy in elbow arthroscopy. *J Shoulder Elbow Surg*. 1995;4(3):168–174. https://doi.org/10.1016/S1058-2746(05)80047-3.
14. Lynch GJ, Meyers JF, Whipple TL, Caspari RB. Neurovascular anatomy and elbow arthroscopy: inherent risks. *Arthroscopy*. 1986;2(3):190–197. https://doi.org/10.1016/S0749-8063(86)80067-6.
15. Hilgersom NFJ, Cucchi D, Luceri F, et al. Locating the ulnar nerve during elbow arthroscopy using palpation is only accurate proximal to the medial epicondyle. *Knee Surg Sports Traumatol Arthrosc*. 2018 Aug 23. https://doi.org/10.1007/s00167-018-5108-y [Epub ahead of print].
16. Kelly EW, Morrey BF, O'Driscoll SW. Complications of elbow arthroscopy. *J Bone Joint Surg Am*. 2001;83-A(1):25–34. https://doi.org/10.1016/s0749-8063(85)80038-4.
17. Desai MJ, Mithani SK, Lodha SJ, Richard MJ, Leversedge FJ, Ruch DS. Major peripheral nerve injuries after elbow arthroscopy. *Arthrosc J Arthrosc Relat Surg*. 2016. https://doi.org/10.1016/j.arthro.2015.11.023.