Cancer Letters 456 (2019) 80–87

Contents lists available at ScienceDirect

Cancer Letters

journal homepage: www.elsevier.com/locate/canlet

Mini-review

Management of immune related adverse events induced by immune checkpoint inhibition

Andreas Teufel[a,*], Tianzuo Zhan[a], Nicolai Härtel[a], Jan Bornschein[b], Matthias P. Ebert[a], Nadine Schulte[a]

[a] Department of Medicine II, Medical Faculty Mannheim, Heidelberg University, Theodor Kutzer Ufer 1-3, 68167, Mannheim, Germany
[b] Translational Gastroenterology Unit, John Radcliffe Hospital, Oxford University Hospitals, Oxford, UK

ARTICLE INFO

Keywords:
Immune related adverse events
irAE
Checkpoint blockade
CTLA-4
PD-1
PD-L1
Nivolumab
Pembrolizumab
Ipilimumab

ABSTRACT

In recent years, immune checkpoint inhibitors (ICIs) were successfully introduced to cancer therapy and these drugs have already become essential for the treatment of various non-curable tumors. Compared to conventional chemotherapy or tyrosine kinase inhibitors, ICIs generally exhibit a favorable side effect profile further promoting their increasing prescription rate.

However, increasing use of these substance made clear that ICI induced activation of the immune system may also lead to immune-related adverse events (irAEs). Common irAEs are dermatological, gastrointestinal, or endocrine side effects but further tissue types and organ systems may also be affected. A detailed knowledge of these potential side effects is important as early recognition is the key to successful treatment, reversibility of organ dysfunction and in some cases even prevention of fatal outcome. In more severe irAEs, immunosuppression may be necessary to cope with these side effects.

To increase awareness of irAEs and support immediate and successful management, we provide a comprehensive review on most common irAEs of ICIs, their diagnosis, and treatment.

1. Background

Since FDA approval of ipilimumab, an anti-CTLA-4 antibody, immune checkpoint inhibitors (ICIs) have emerged as highly effective treatment option in various cancer entities [1]. Thus, ICIs are now essential to the first-line treatment of melanoma and metastatic non-small cell lung cancer (NSCLC), and are emerging treatment options for many other solid tumors [1–5]. Furthermore, prembrolizumab, an anti-PD-1 antibody, was approved for treatment of any adult or pediatric, unresectable or metastatic solid tumor that is classified asa microsatellite instability-high (MSI-H) or with a deficient DNA mismatch repair system (dMMR). Several molecular mechanisms were found to promote high efficacy in these MSI-H/dMMR tumors, among them tumor infiltrating lymphocytes, elevated tumor mutational burden, and upregulated PD-L1 expression [6–8]. As the first tumor "type-agnostic" therapeutic option, immune therapy will become treatment of choice for many of these entities [9]. However, some tumors, including pancreatic cancer [10], hepatocellular carcinoma (HCC) [11] or head and neck squamous cell cancer [12] display resistance against ICIs, and patients do not benefit from these agents. Combination therapy using ICIs with tyrosine kinase inhibitors (TKIs) or other drugs may be an effective solution to overcome the current difficulties in treating ICI resistant cancers such as HCC and bring treatment and the related outcome to the next level [13,14]. Overall, ICIs will be a substantial part of clinical decision algorithms in cancer therapy for the upcoming decades. (see Table 1, Figs. 1 and 2)

However, with a broad application of these drugs, specific ICI related adverse effects (irAEs) are increasingly recognized. These irAEs may be different from major side effects observed under conventional chemotherapy or TKI treatment, as they are mostly due to an overactivated immune system and comparable to autoimmune diseases. To increase awareness of these very diverse side effects and foster early and adequate treatment, we summarize the most common irAEs and provide an overview on established, effective treatment options.

2. Mechanisms of immune checkpoint inhibition

Immune checkpoints protect tissues from an activated immune system, e.g. in response to pathogens. Primary mechanism is a downregulation of T-cell activation or effector functions.

* Corresponding author. University Medical Center Mannheim Department of Medicine II, Division of Hepatology and Division of Clinical Bioinformatics Medical Faculty Mannheim, University of Heidelberg, Theodor-Kutzer-Ufer 1-3, 68167, Mannheim, Germany.
E-mail address: andreas.teufel@medma.uni-heidelberg.de (A. Teufel).

https://doi.org/10.1016/j.canlet.2019.04.018
Received 29 January 2019; Received in revised form 2 April 2019; Accepted 9 April 2019
0304-3835/ © 2019 Elsevier B.V. All rights reserved.

Table 1
Summary of common irAEs, stage Definition and suggested Treatment.

irAE	irAE grade				Frequency[a] all grades
	I	II	III	IV	
Skin rash	Rash covering < 10% BSA	Rash 10–30% BSA, limiting daily activities	Rash covering > 30% BSA, limiting self-care	Rash covering > 30% of BSA, associated with life-threatening superinfection; Stevens-Johnson syndrome, TEN and bullous dermatitis	30%
Treatment	Topical corticosteroids, antihistamines	Topical corticosteroids, antihistamines	Systemic corticosteroid, e.g. prednisone 0.5–1 mg/kg/d, hold ICI	Systemic corticosteroid, e.g. prednisone 0.5–1 mg/kg/d, hold ICI	
Colitis	Abnormal stool frequency, up to 4/d	Abdominal pain; mucus or blood in stool, Stool frequency up to 6/d	Severe abdominal pain; disturbed bowel habits; peritoneal signs, Stool frequency > 7/d	Life-threatening consequences	30–40%
Treatment	Anti-diarrheal medication	Stool and blood work, endoscopy, consider symptomatic treatment	Hold ICI, Prednisone 1 mg/kg/day	Discontinue ICI, Prednisone 1 mg/kg/day	
Hepatitis	AST and/or ALT up to 3x ULN; Total bilirubin up to 1.5x ULN	ASL and/or ALT 3-5x ULN; Total bilirubin 3-5x ULN	AST and/or ALT > 5x ULN; Total bilirubin > 3x ULN		38%
Treatment	Close monitoring	Rule out alternative causes, Hold ICI	Consider liver biopsy, Prednisone 1–2 mg/kg/day, taper over 4–8 weeks, Permanent discontinuation of ICI	Consider liver biopsy, Prednisone 1–2 mg/kg/day, taper over 4–8 weeks, Permanent discontinuation of ICI	
Hypophysitis	Asymptomatic or mild symptoms	Moderate symptoms, limiting activity	Severe, limiting self-care activity	Life-threatening	10%
Treatment	Close monitoring	Hold ICI, lab work up, Consider hormone replacement	In case of central adrenal insufficiency: Hydrocortisone 10 mg/m2 (devided into 2–3 doses), In case of central hypothyroidism: levothyroxine 1 µg/kg, For adrenal crisis see standard clincial practice guidelines	In case of central adrenal insufficiency: Hydrocortisone 10 mg/m2 (devided into 2–3 doses), In case of central hypothyroidism: levothyroxine 1 µg/kg, For adrenal crisis see standard clincial practice guidelines	
Thyroiditis	Asymptomatic	Symptomatic, limiting activity	Severe, limiting self-care activity	Life-threatening	25%
Treatment		Consider b-Blocker, consider thyroid replacement therapy	Consider b-Blocker, consider thyroid replacement therapy, Hold ICI	Consider b-Blocker, consider thyroid replacement therapy, Hold ICI	
Nephritis	Creatinine 1.5–2.0 × above baseline	Creatinine 2–3 × above baseline	Creatinine > 3 x baseline or > 4.0 mg/dL	Life-threatening; dialysis	2%
Treatment	Rule out other causes of kidney impairment	Consider prednisolone 0.5–1 mg/kg/d, Hold ICI	Prednisolone 0.5–1 mg/kg/d, Hold ICI	Prednisolone 0.5–1 mg/kg/d, Permanently discontinue ICI	
Meningitis	Asymptomatic	Symptomatic, limiting activity	Severe, limiting self-care activity	Life-threatening	0.1–0.2%
Treatment	MRI brain, consider lumbar puncture, consider oral prednisone 1 mg/kg/d, Discontinue ICI	MRI brain, consider lumbar puncture, < !–Soft-enter Run-on– > consider oral prednisone 1 mg/kg/d, Discontinue ICI	Hospitalization, MRI brain, consider lumbar puncture including PCR for HSV and other viral PCRs, hold ICI, consider acyclovir and antibiotic until CSF results, < !–Soft-enter Run-on– > high dose i.v. steroids (e.g. prednisone 500 mg/d for 3 days followed by 1 mg/kg/d), Discontinue ICI	Hospitalization, MRI brain, consider lumbar puncture including PCR for HSV and other viral PCRs, hold ICI, consider acyclovir and antibiotic until CSF results, < !–Soft-enter Run-on– > high dose i.v. steroids (e.g. prednisone 500 mg/d for 3 days followed by 1 mg/kg/d), Discontinue ICI	
Encephalitis	Asymptomatic	Symptomatic, limiting activity	Severe, limiting self-care activity	Life-threatening	0.1–0.2%
Treatment	MRI brain, consider lumbar puncture, consider oral prednisone 1 mg/kg/d, Discontinue ICI	MRI brain, consider lumbar puncture, < !–Soft-enter Run-on– > consider oral prednisone 1 mg/kg/d, Discontinue ICI	Hospitalization, MRI brain, consider lumbar puncture including PCR for HSV and other viral PCRs, hold ICI, consider acyclovir and antibiotic until CSF results, < !–Soft-enter Run-on– > high dose i.v. steroids (e.g. prednisone 500 mg/d for 3 days followed by 1 mg/kg/d), Discontinue ICI	Hospitalization, MRI brain, consider lumbar puncture including PCR for HSV and other viral PCRs, hold ICI, consider acyclovir and antibiotic until CSF results, < !–Soft-enter Run-on– > high dose i.v. steroids (e.g. prednisone 500 mg/d for 3 days followed by 1 mg/kg/d), Discontinue ICI	
Pancreatitis		Enzyme elevation or radiologic findings only	Severe pain, Vomiting, Medical intervention indicated (analgesia, nutrition)	Life-threatening consequences, Urgent	20%
Treatment		Close monitoring, Hold ICI	I.v. fluids, Consider prednisolone 1 mg/kg/day, Permanently discontinue ICI	I.v. fluids, Consider prednisolone 1 mg/kg/day, Permanently discontinue ICI	
Pneumonitis	Asymptomatic, compatible radiological changes	Symptomatic, limiting daily activity	Severe symptoms, limiting self-care, need for oxygen	Life-threatening respiratory distress, need for urgent intervention	19%
Treatment	Close monitoring	Prednisolone 1 mg/kg/day, Consider bronchoscopy and biopsy, Hold ICI	Prednisolone 1 mg/kg/day, Consider bronchoscopy and biopsy, Permanently discontinue ICI, Consider ICU care	Prednisolone 2 mg/kg/day, Consider bronchoscopy and biopsy, Permanently discontinue ICI, Consider ICU care	
Myocarditis	Abnormal ECG and/or biomarker	Mild symptoms, Abnormal ECG and/or biomarker	Abnormal ECG and/or biomarker, symptoms with mild activity	Decompensation, life threatening conditions	2.4%
Treatment	Close monitoring	Close monitoring	Consider prednisolone 1 mg/kg/day, Hold ICI	Prednisolone 1 mg/kg/day, Permanently discontinue ICI, Consider ICU care	

[a] Frequency may vary significantly depending on ICI. Highest documented rates of occurence were summarized (mostly in combination therapy).

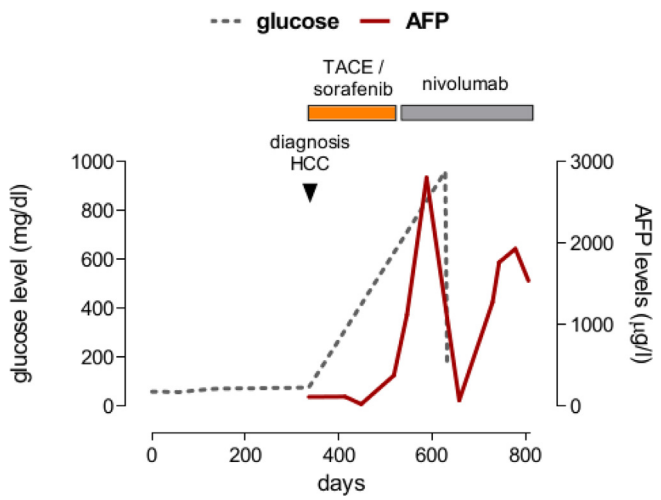

Fig. 1. A 79 year-old male suffering from HCC and accompanying liver cirrhosis (Child Pugh score A) was started on nivolumab (3 mg/kg body weight every other week). After three doses of nivolumab, he developed severe hyperglycemia and ketoacidosis, requiring intensive care treatment. After full recovery he received intensified insulin therapy. Restaging showed regression of a vascular tumor thrombus and a significant drop of AFP levels from 2799 to 41 µg/l. Therapy with nivolumab was therefore continued and well tolerated. Despite increasing AFP levels consecutive MRI scans showed disease stabilization.

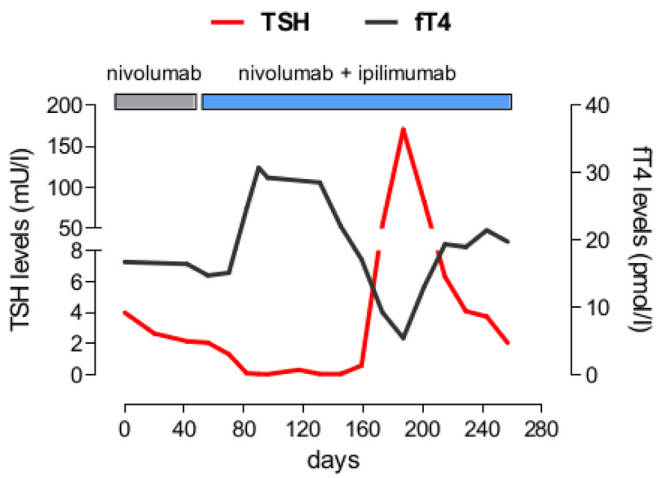

Fig. 2. A 70 year-old female was diagnosed with squamous cell carcinoma of the distal esophagus and multiple liver metastases. She received three cycles of nivolumab (240 mg iv every other week), followed by a combination of nivolumab (every other week) and ipilimumab (1 mg/kg body weight, every sixth week). Two weeks after initiation of combination ICI treatment, the patient developed hyperthyroidism. Ultrasound of the thyroid gland revealed no specific findings apart from a struma multinodosa. Serum autoimmune antibodies were not detected. Thyreostatic therapy with carbimazol was initiated. After 4 months, the condition changed to hypothyroidism requiring hormone substitution. Despite thyroid irAE, dual ICI treatment was continued resulting in disease control and recovery of quality of life. Overall, due to early and rigorous irAE treatment, checkpoint inhibition was well tolerated.

Blocking immune checkpoints, e.g. through antibodies directed against specific receptors such as CTLA-4 or PD-1, has proven to be an effective strategy to increase activity of the immune system and enhance immune surveillance, cytotoxic action, and, ultimately, patients' survival.

CTLA-4 is expressed on activated T-cells, and primarily engaged in down-regulating the degree of T-cell activation. Generally, the CTLA-4 signal is balanced with a co-stimulatory signal delivered by CD28. However, CTLA-4 shows a higher affinity than CD28 to their mutual ligands CD80 and CD86 hence surpassing the CD28 signal and limiting the T-cell response [15,16].

Binding of PD-1 by a ligand transmits an inhibitory signal on T cell activity. The PD-1 receptor clusters with T-cell receptors (TCRs) and recruits phosphatase SHP2. The latter induces dephosphorylation of the proximal TCR signaling molecules, ultimately leading to a suppression of T-cell activation [17].

Thus, blockade of the inhibitory CTLA-4 or PD-1 receptor was identified as effective therapeutic strategy through enhancement of the activity of the immune system [16].

3. Immune related adverse events (irAE)

Stimulation of the PD-1/PD-L1 axis modulates the immune response towards an increased tumor cell clearance, thereby providing a highly effective treatment option for solid cancers. However, induction of the PD-1/PD-L1 and CTLA-4 axes were also demonstrated to be involved in autoimmunity [18–21]. Autoimmune diseases like inflammatory bowel diseases, rheumatoid arthritis, autoimmune hepatitis, or systemic lupus erythematosus were previously linked to an alteration in PD-1/PD-L1 signaling [22,23]. Thus, side effects of ICIs, targeting the PD-1/PD-L1 or CTLA-4 axis, may obviously include inflammatory conditions not observed in conventional chemotherapy or thyrosine kinase inhibition.

Overall, occurrence of all grade irAE may be as high as 75% in patients treated with ipilimumab [24]. In patients treated with anti-PD-1/PD-L1 agents, up to 30% of all grade irAEs were observed [25–27]. High grade irAEs (grade 3 or 4) occur much less often but may still be observed in up to 43% of patients taking ipilimumab [28]. High grade irAE induced by PD-1/PD-L1 targeting agents may occur in up to 20% of patients [25,29]. Combined treatment with CTLA-4 and PD-1 or PD-L1 inhibitors led to irAE rates of 95%, with 55% being grade 3 or 4 [30]. For most ICIs, the overall irAE profile was independent of the administered dose [31]. Only for ipilimumab, a large meta-analysis demonstrated an association of increased irAE occurrence with higher dosage [31].

Among all irAEs associated with checkpoint inhibitors, the most common side effects include dermatological, gastrointestinal, and endocrine irAEs [31–34]. In addition to these, many other irAEs have been reported involving various tissue types and/or organ systems, including pulmonary, cardiovascular, renal, or neurological irAEs. Although the majority of irAEs are mild or moderate in severity, fatal outcomes of irAEs were reported repeatedly. Large retrospective analyses of patients treated with ICIs observed fatal outcome due to irAEs in 0.36% (anti–PD-1) and 1.23% (PD-1/PD-L1 plus CTLA-4) of patients [35]. The irAE related mortality differed significantly between patients treated with anti–CTLA-4 agents, in whom 70% of all fatal irAEs were due to colitis, and anti–PD-1/PD-L1 treated patients in whom pneumonitis was the leading cause of irAE related death, accounting for 35% of all fatal irAEs [35]. Although irAEs may occur at any time during treatment or even after discontinuation of ICI treatment [36,37], most fatal irAEs occurred early after treatment initiation. Among all irAEs, myocarditis shows the highest mortality of approximately 40% [35]. In contrast and despite being the most common cause for fatal outcome in anti–CTLA-4 treated patients, colitis was only fatal in 2%–5% of patients [35].

4. Organ specific toxicity

4.1. Dermatological irAEs

Dermatological irAEs are common and are often observed early after treatment initiation [38]. Overall occurrence of all grade skin irAEs was estimated to be as high as 30% in patients treated with ICIs. These adverse effects can be very diverse and range from a mild non-specific rash, lichenoid reactions, vitiligo, and pruritus [39] to severe dermatological reactions such as extensive exfoliative dermatitis, Stevens-Johnson syndrome, or toxic epidermal necrolysis [40–42]. More

severe skin toxicity was defined as a rash covering more than 30% of the body surface area (BSA, grade 3) or as a combination of a less severe rash (grade 2) with substantial additional symptoms. Grade 4 toxicity was defined as skin sloughing of more than 30% BSA with associated symptoms (e.g. erythema, purpura, epidermal detachment) [38]. These more severe skin irAEs were observed in only up to 3% of patients treated with ICIs [30,43–45].

Initial treatment of mild dermatological side effects (grade 1 or 2) can be managed using antihistamines to treat pruritus, and topical steroids, e.g. hydrocortisone. High grade skin irAEs require discontinuation of ICI treatment and high-dose immunosuppressive treatment, usually applying systemic steroids (e.g. prednisolone 1 mg/kg to be tapered upon clinical improvement of the irAE). After amelioration of skin symptoms and downstaging to grade 1 or grade 2 side effects, re-initiation of ICI treatment may be considered after detailed discussion between patient and physician and depending on efficacy and availability of alternative treatment options [46].

4.2. Colitis

Gastrointestinal side effects, particularly watery diarrhea and enterocolitis are also among the most common complications of ICI treatment. The documented incidence of diarrhea varies but was reported to be between 30 and 40% of patients treated with ipilimumab [47]. However, in patients treated with anti–PD-1/PD-L1, diarrhea occurred at significantly lower rates, in approximately 16% of patients [43]. Colitis was reported only in up to 7–9% of patients treated with ipilimumab [47] and 1–3% of patients treated with nivolumab [27,45,48,49]. Furthermore, the severity of irAEs induced by treatment with ipilimumab was associated with the dose administered [50]. A recent randomized, controlled trial reported colitis in 5% of patients with 10 mg/kg of ipilimumab as compared to 2% among those treated with 3 mg/kg, respectively [51]. Apart from hydro-electrolytic complications or renal failure, severe intestinal inflammation may rarely lead to reflex ileus or intestinal perforation, complications that could be life threatening. Thus, high grade gastrointestinal irAE require early treatment that should not be delayed by endoscopic evaluation. Colonoscopy may reveal erythema (45–79%), erosion or ulceration (57–79%), and/or luminal bleeding.

irAE specific treatment is indicated in high grade colitis, defined by severe abdominal pain, change in bowel habits, fever, ileus, peritoneal signs, urgent need for intervention (e.g. in case of perforation, bleeding, ischaemia, or toxic megacolon), diarrhea with more than 7 bowel motions per day, or hemodynamic problems. Treatment of choice broadly relies on corticosteroids, e.g. prednisolone 1 mg/kg/day, to which most patients respond well. Immunosuppressant therapy should be accompanied by early microbiological diagnostics for gastrointestinal infections, particularly for faecal enteropathogens and clostridium difficile toxin [38]. Depending on the results, additional antibiotic treatment may be considered. In severe and steroid-refractory cases the successful use of infliximab (5 mg/kg) was reported [52,53]. In contrast, mild to moderate gastrointestinal irAE do usually not require corticosteroids but only clinical observation [54]. Again, routine stool diagnostics should be performed to exclude infectious enteritis or opportunistic infections. Endoscopy is necessary to confirm colitis which may be a reason to apply corticosteroids even in gastrointestinal grade 2 irAEs [53,55].

4.3. Immune mediated hepatitis

Immune mediated hepatitis as a side effect of ICIs most often occurs between 8 and 12 weeks after treatment initiation. Thus, liver specific side effects usually occur later than skin or luminal GI specific side effects. However, as for any other irAE, immune mediated hepatitis may occur even after a longer period of treatment with occurrence being documented for up to one year after initial application [56]. Reviews summarizing hepatic adverse events demonstrate an overall low rate of high-grade adverse events (grade 3/4), mostly between 1 and 5% of all patients, with two studies reporting these complications in 10% and 14% under treatment with ipilimumab [30,57].

Treatment of hepatic irAE is generally recommended for grade 3/4 side effects defined as AST (aspartate aminotransferase)/ALT (alanine aminotransferase) > 5× ULN (upper limit of normal) or total bilirubin > 3× ULN. Common recommendations include immune-suppressvie treatment after discontinuation of the ICI. In most cases, hepatic irAE respond well to corticosteroids which can usually be rapidly tapered and discontinued. In rare cases, however, alternative immunosuppressants such as mycophenolate mofetil (MMF, 2 × 500 mg/day) are required [58].

More recent data revealed interesting observations on 16 patients suffering from hepatic irAE, who did not receive immunosuppressant treatment after histological stratification. These patients showed spontaneous improvement of their liver function, and it was concluded that hepatic irAE do not necessarily require systemic corticosteroid administration. Even more, in three out of these 16 patients, immunotherapy was successfully reintroduced without recurrence of liver function impairment [59]. Obviously, these data warrant further evaluation to enable effective patient stratification according to the severity of the irAE. Morphological and molecular predictors of the "natural" course of hepatic irAEs are required to determine the risk of fulminant hepatitis and liver failure. This would allow patient-oriented management with the potential to avoid unnecessary systemic immunosuppressive treatment in the future.

4.4. Endocrine irAEs

Endocrine irAEs are also common among patients treated with ICIs. Overall, endocrine events were observed in up to 14% of patients treated with nivolumab and even up to 30% in patients treated with a combination of nivolumab and ipilimumab [60]. Among all endocrine disorders, pituitary and thyroid irAEs were most commonly observed [60].

Thyroid function disturbance due to ICI treatment was observed in approximately 25% of patients receiving a combination of ipilimumab and nivolumab. The incidence was lower in case of single agent treatment but still considerable, with comparable incidence rates (approximately 13%) for nivolumab and pembrolizumab [60,61]. These patients may exhibit the full range of thyroid disease from painless thyroiditis to (rarely) severe forms of thyroid disease, e.g. thyrotoxic crisis. Patients experiencing hypothyroidism may suffer from fatigue, weakness, asthenia, constipation, intolerance to cold temperatures, dry skin, or weight gain. In contrast, hyperthyroidism can manifest itself as diarrhea, heat intolerance, sweating, weight loss, or new-onset of atrial fibrillation [60,62].

In ipilimumab and ipilimumab/nivolumab treated patients hypophysitis was also observed in up to 10% of patients [60]. In contrast, hypophysitis was rarely present in patients treated with other ICIs. Common symptoms of this condition include nausea, vomiting, weakness, fatigue, mild cognitive dysfunction, hypotension, and fever. In addition, persistent headaches may be a symptom. Low serum levels of sodium may also be associated with hypophysitis [63], but diabetes insipidus in CTLA-4-inhibitor induced hypophysitis is extremely rare [64]. Although rather unspecific, these symptoms were observed in up to 89% of patients with hypophysitis [65] and require advanced diagnostics. The diagnosis of hypophysitis is generally based on laboratory investigations, including test for serum levels of TSH (thyroid stimulating hormone), fT3 (freeT3), fT4 (freeT4), ACTH (adrenocorticotropic hormone), cortisol, LH (luteinizing hormone), FSH (follicle stimulating hormone), prolactin, estradiol in females, and testosterone in men. In addition, an MRI of the brain/pituitary should be performed [66], but pituitary changes may be discrete. If present, MRI findings linked to hypopituitarism might precede clinical signs of pituitary irAE [67,68].

If necessary, transient thyroiditis can be treated with β-blockers in most cases. Thyroid blockers are rarely needed. In severe cases, further diagnostics including ultrasonography or thyroid scintigraphy should be performed to rule out differential diagnoses such as Graves' disease. Patients should be monitored regularly in order to detect signs of permanent hypothyroidism early [69].

A watch-and-wait strategy is appropriate for asymptomatic patients with mild hypothyroidism. In more severe hypothyroidism, thyroid hormone replacement (levothyroxine) therapy should be initiated under TSH monitoring [66].

Symptomatic hypophysitis requires corticosteroids and thyroid hormone replacement. The most dreaded complication is adrenal crisis, which is why steroid replacement should precede levothyroxine. If suspected, patients should immediately be treated with i.v. hydrocortisone (e.g. 100 mg every 8 h) and aggressive fluid replacement (1–3 l within the first 24 h) [66]. Otherwise, patients should receive high dose corticosteroids (e.g. methylprednisolone 1 mg/kg) in case of severe clinical symptoms or clinical signs of pressure on the optic chiasma. This can be tapered under close endocrine monitoring over 4–8 weeks. Since high dose steroids seem not to improve the course of hormonal recovery [70] treatment may be restricted to hormone replacement in patients with mild symptoms (e.g. hydrocortisone (20–30 mg/day) [60,66,69–71]. The likelihood of potential recovery is still uncertain and in some patients hypopituitarism may persist. Particularly, recovery of the adrenal axis is rare [72].

Since endocrine irAEs are common in patients treated with ICI, regular monitoring of serum TSH, fT4, and ACTH and cortisol levels for patients treated with anti-CTLA-4 agents, is advisable [71].

4.5. Miscellaneous, rare irAEs

4.5.1. Nephritis

Early on in the use of ICIs, several cases of ICI associated renal complications were reported [73]. The overall occurrence was initially estimated to be low. A large meta-analysis incorporating 3,695 patients estimated ICI related acute renal injury to occur in approximately 2.2% of patients [74]. However, these numbers were recently challenged by studies reporting a much higher incidence between 13 and 29% [75,76]. A detailed analysis of 13 patients who underwent renal biopsy for the suspicion of acute kidney injury related to ICI treatment demonstrated diverse histological features. In most patients, tubulointerstitial nephritis was identified, but three patients demonstrated granulomatous features, and one thrombotic microangiopathy [74]. Patients with tubulointerstitial nephritis clearly benefit from discontinuation of the checkpoint inhibitor and subsequent corticosteroid treatment (e.g. prednisolone 1 mg/kg, tapered over 4–8 weeks) [74]. Treatment should be given under close monitoring of serum creatinine. In most patients, partial improvement can be achieved, in some even full reconstitution of renal function [74].

4.5.2. Neurological side effects, encephalitis, meningitis

Recent data from a systematic meta-analysis of ICI induced neurological side effects revealed encephalitis and myopathies being the most common neurological irAEs. These were also associated with the highest morbidity and mortality [77].

Both ICI mediated encephalitis and meningitis were estimated to occur in 0.1–0.2% of patients [78–81]. Symptoms may vary and include seizures, confusion, ataxia, and alteration of consciousness. Cerebrospinal fluid exhibits lymphocytic pleiocytosis leading to the diagnosis of ICI induced meningitis or encephalitis. An MRI of the brain can reveal meningeal enhancement in meningitis, whereas the procedure adds information only in a minority of patients with encephalitis [78]. Both ICI induced encephalitis and meningitis respond well to treatment with corticosteroids [78,82].

The incidence of ICI induced myasthenia gravis was also estimated between 0.1 and 0.2% of patients. The clinical presentation may vary from ocular to generalized myasthenia gravis or even myasthenic crisis. In addition, pre-existing myasthenia gravis can exacerbate on ICI treatment. In patients developing myasthenia gravis upon ICI treatment elevated creatine kinase levels in the serum were commonly observed. ICI induced myasthenia gravis usually responds well to corticoid-based treatment. More advanced treatment options such as plasmapheresis were only rarely needed [82–85].

4.5.3. Pancreatitis

Immune mediated pancreatitis was reported in several case reports and recorded in large studies on ICI treatment of several tumor entities [86]. A small retrospective analysis of patients treated with the combination immunotherapy with nivolumab and ipilimumab reported pancreatitis to be rare despite 20% of patients with at least grade 3 changes of serum amylase and 6.3% of patients with at least grade 3 changes of serum lipase, as well as 20% of patients with at least grade 3 changes of both enzymes [87]. This observation was further substantiated by a recent meta-analysis demonstrating that not only the combination immune therapy but also CTLA-4 inhibitors alone can increase the risk of amylase or lipase elevation. However, the meta-analysis did also not confirm a significantly increased risk of pancreatitis compared with controls [88]. Due to the very sparse clinical literature on the management of immune related pancreatitis, general recommendations are lacking. However, i.v. fluids were demonstrated to be important and most patients receive steroids [89].

4.5.4. Pneumonitis

The incidence of all grade pneumonitis ranged between 0 and 2% of ICI treated non-NSCLC patients. The incidence of pneumonitis can vary depending on the tumor type. A higher incidence was observed in non small cell lung cancer (NSCLC) and renal cell cancer (RCC) patients compared to melanoma patients [90]. Lately, even higher rates of up to 19% of ICI related pneumonitis were suggested [91]. Patients with ICI related pneumonitis usually present with non-resolving dyspnea and cough [92]. The diagnosis of pneumonitis is based on CT imaging where signs of ICI induced pneumonitis can appear prior to clinical manifestation of symptoms [93].

The recommended treatment for ICI related pneumonitis also relies on corticosteroids, e.g. methylprednisolone 1 mg/kg. In grade 4 pneumonitis higher doses of 2–4 mg/kg can be considered. Steroids should be tapered over 4–8 weeks. In any case, close monitoring by means of CT imaging is recommended. In patients with persistent or even worsening pneumonitis on corticosteroids, intensified immunotherapy utilizing infliximab, cyclophosphamide, or mycophenolate mofetil may be considered [94,95].

4.5.5. Myocarditis

Myocarditis has the highest mortality among all irAEs (39.7% [35]). Overall, cardiotoxic irAEs are rare. Among patients treated with nivolumab (some oft them in combination with ipilimumab) 0.09% suffered from myocarditis [96]. Up to 2.4% was reported for patients receiving anti-PD-1/anti-CTLA-4 combination therapy in an idependent multicenter registry [97].However, as these adverse events may be life-threatening they need to be considered in any patient complaining about side effects of ICIs. Patients suffering from irAE cardiotoxicity present with dyspnea, palpitation, and signs of congestive heart failure [98]. Due to its rare occurrence there is general lack of experience in the management of immune related mycarditis with most patient receiving steroids [96,97,99].

4.5.6. Re-induction of ICI after successful irAE treatment

Recent data on the re-induction of anti-PD-1 therapy after toxicity of ipilimumab suggested that these irAE are likely to be substance specific and the use of a different ICI can be considered if there is a lack of alternative treatment options [100]. This view was furthermore substantiated by a report on re-induction of anti–PD-1 or anti–PD-L1

treatment after irAEs, without further irAE in 50% of these patients [101]. For some irAEs such as hypophysitis continued treatment can be considered in mild cases, since full reconstitution is rare and many patients require permanent hormone replacement even in case of improvement of inflammation [69]. Since prospective data from clinical trials are lacking, re-induction of ICI treatment after mild irAEs can be considered depending on the severity of the prior irAE and in view of (a lack of) alternative treatment options. However, high grade irAEs with potentially life-threatening toxicity must be regarded an absolute contraindication for further ICI treatment.

5. Summary

Immunotherapy related adverse events are common and may affect nearly all tissue types and organ systems. Among the most common irAEs are dermatological, endocrine, and gastrointestinal irAEs. A detailed knowledge of these potential side effects is important as early recognition is the key to successful treatment, reversibility of organ dysfunction and, in some cases, prevention of fatal outcome. If necessary, treatment is mostly based on corticosteroids to which most irAEs respond well. After successful treatment, ICIs may be continued under close monitoring in most patients with mild to moderate irAEs.

Conflicts of interest

Nothing to declare.

References

[1] G. D'Errico, H.L. Machado, B. Sainz Jr., A current perspective on cancer immune therapy: step-by-step approach to constructing the magic bullet, Clin. Transl. Med. 6 (2017) 3.

[2] P. Grierson, K.H. Lim, M. Amin, Immunotherapy in gastrointestinal cancers, J. Gastrointest. Oncol. 8 (2017) 474–484.

[3] Z.W. Myint, G. Goel, Role of modern immunotherapy in gastrointestinal malignancies: a review of current clinical progress, J. Hematol. Oncol. 10 (2017) 86.

[4] T. Castellano, K.N. Moore, L.L. Holman, An overview of immune checkpoint inhibitors in gynecologic cancers, Clin. Ther. 40 (2018) 372–388.

[5] J.M. Mataraza, P. Gotwals, Recent advances in immuno-oncology and its application to urological cancers, BJU Int. 118 (2016) 506–514.

[6] Z. Jin, H.H. Yoon, The promise of PD-1 inhibitors in gastro-esophageal cancers: microsatellite instability vs. PD-L1, J. Gastrointest. Oncol. 7 (2016) 771–788.

[7] A.M. Mills, E.A. Dill, C.A. Moskaluk, J. Dziegielewski, T.N. Bullock, P.M. Dillon, The relationship between mismatch repair deficiency and PD-L1 expression in breast carcinoma, Am. J. Surg. Pathol. 42 (2018) 183–191.

[8] D.T. Le, J.N. Durham, K.N. Smith, H. Wang, B.R. Bartlett, L.K. Aulakh, S. Lu, H. Kemberling, C. Wilt, B.S. Luber, F. Wong, N.S. Azad, A.A. Rucki, D. Laheru, R. Donehower, A. Zaheer, G.A. Fisher, T.S. Crocenzi, J.J. Lee, T.F. Greten, A.G. Duffy, K.K. Ciombor, A.D. Eyring, B.H. Lam, A. Joe, S.P. Kang, M. Holdhoff, L. Danilova, L. Cope, C. Meyer, S. Zhou, R.M. Goldberg, D.K. Armstrong, K.M. Bever, A.N. Fader, J. Taube, F. Housseau, D. Spetzler, N. Xiao, D.M. Pardoll, N. Papadopoulos, K.W. Kinzler, J.R. Eshleman, B. Vogelstein, R.A. Anders, L.A. Diaz Jr., Mismatch repair deficiency predicts response of solid tumors to PD-1 blockade, Science 357 (2017) 409–413.

[9] L. Yan, W. Zhang, Precision medicine becomes reality-tumor type-agnostic therapy, Cancer Commun. 38 (2018) 6.

[10] J. Jiang, H. Zhou, C. Ni, X. Hu, Y. Mou, D. Huang, L. Yang, Immunotherapy in pancreatic cancer: new hope or mission impossible? Cancer Lett. 445 (2019) 57–64.

[11] https://investors.merck.com/news/press-release-details/2019/Merck-Provides-Update-on-KEYNOTE-240-a-Phase-3-Study-of-KEYTRUDA-pembrolizumab-in-Previously-Treated-Patients-with-Advanced-Hepatocellular-Carcinoma/default.aspx.

[12] A.L. Strome, X. Zhang, S.E. Strome, The evolving role of immuno-oncology for the treatment of head and neck cancer, Laryngoscope Investig. Otolaryngol. 4 (2019) 62–69.

[13] M. Kudo, Immune checkpoint inhibition in hepatocellular carcinoma: basics and ongoing clinical trials, Oncology 92 (Suppl 1) (2017) 50–62.

[14] S. Stein, M. Pishvaian, M. Lee, K. Lee, S. Hernandez, A. Kwan, B. Liu, W. Grossman, K. Iizuka, B. Ryoo, Safety and clinical activity of 1L atezolizumab + bevacizumab in a phase Ib study in hepatocellular carcinoma (HCC), J. Clin. Oncol. 36 (2018) 4074-4074.

[15] P.S. Linsley, J.L. Greene, W. Brady, J. Bajorath, J.A. Ledbetter, R. Peach, Human B7-1 (CD80) and B7-2 (CD86) bind with similar avidities but distinct kinetics to CD28 and CTLA-4 receptors, Immunity 1 (1994) 793–801.

[16] C. Granier, E. De Guillebon, C. Blanc, H. Roussel, C. Badoual, E. Colin, A. Saldmann, A. Gey, S. Oudard, E. Tartour, Mechanisms of action and rationale for the use of checkpoint inhibitors in cancer, ESMO Open 2 (2017) e000213.

[17] T. Yokosuka, M. Takamatsu, W. Kobayashi-Imanishi, A. Hashimoto-Tane, M. Azuma, T. Saito, Programmed cell death 1 forms negative costimulatory microclusters that directly inhibit T cell receptor signaling by recruiting phosphatase SHP2, J. Exp. Med. 209 (2012) 1201–1217.

[18] S. Dai, R. Jia, X. Zhang, Q. Fang, L. Huang, The PD-1/PD-Ls pathway and autoimmune diseases, Cell. Immunol. 290 (2014) 72–79.

[19] L.M. Francisco, P.T. Sage, A.H. Sharpe, The PD-1 pathway in tolerance and autoimmunity, Immunol. Rev. 236 (2010) 219–242.

[20] O.P. Kristiansen, Z.M. Larsen, F. Pociot, CTLA-4 in autoimmune diseases–a general susceptibility gene to autoimmunity? Genes Immun. 1 (2000) 170–184.

[21] J. Romo-Tena, D. Gomez-Martin, J. Alcocer-Varela, CTLA-4 and autoimmunity: new insights into the dual regulator of tolerance, Autoimmun. Rev. 12 (2013) 1171–1176.

[22] M.R. Zamani, S. Aslani, A. Salmaninejad, M.R. Javan, N. Rezaei, PD-1/PD-L and autoimmunity: a growing relationship, Cell. Immunol. 310 (2016) 27–41.

[23] B.T. Fife, K.E. Pauken, The role of the PD-1 pathway in autoimmunity and peripheral tolerance, Ann. N. Y. Acad. Sci. 1217 (2011) 45–59.

[24] A. Bertrand, M. Kostine, T. Barnetche, M.E. Truchetet, T. Schaeverbeke, Immune related adverse events associated with anti-CTLA-4 antibodies: systematic review and meta-analysis, BMC Med. 13 (2015) 211.

[25] B.L. Maughan, E. Bailey, D.M. Gill, N. Agarwal, Incidence of immune-related adverse events with program death receptor-1- and program death receptor-1 ligand-directed therapies in genitourinary cancers, Front. Oncol. 7 (2017) 56.

[26] J. Villadolid, A. Amin, Immune checkpoint inhibitors in clinical practice: update on management of immune-related toxicities, Transl. Lung Cancer Res. 4 (2015) 560–575.

[27] S.L. Topalian, F.S. Hodi, J.R. Brahmer, S.N. Gettinger, D.C. Smith, D.F. McDermott, J.D. Powderly, R.D. Carvajal, J.A. Sosman, M.B. Atkins, P.D. Leming, D.R. Spigel, S.J. Antonia, L. Horn, C.G. Drake, D.M. Pardoll, L. Chen, W.H. Sharfman, R.A. Anders, J.M. Taube, T.L. McMiller, H. Xu, A.J. Korman, M. Jure-Kunkel, S. Agrawal, D. McDonald, G.D. Kollia, A. Gupta, J.M. Wigginton, M. Sznol, Safety, activity, and immune correlates of anti-PD-1 antibody in cancer, N. Engl. J. Med. 366 (2012) 2443–2454.

[28] A.M. Eggermont, V. Chiarion-Sileni, J.J. Grob, R. Dummer, J.D. Wolchok, H. Schmidt, O. Hamid, C. Robert, P.A. Ascierto, J.M. Richards, C. Lebbe, V. Ferraresi, M. Smylie, J.S. Weber, M. Maio, L. Bastholt, L. Mortier, L. Thomas, S. Tahir, A. Hauschild, J.C. Hassel, F.S. Hodi, C. Taitt, V. de Pril, G. de Schaetzen, S. Suciu, A. Testori, Prolonged survival in stage III melanoma with ipilimumab adjuvant therapy, N. Engl. J. Med. 375 (2016) 1845–1855.

[29] V. Kumar, N. Chaudhary, M. Garg, C.S. Floudas, P. Soni, A.B. Chandra, Current diagnosis and management of immune related adverse events (irAEs) induced by immune checkpoint inhibitor therapy, Front. Pharmacol. 8 (2017) 49.

[30] J. Larkin, V. Chiarion-Sileni, R. Gonzalez, J.J. Grob, C.L. Cowey, C.D. Lao, D. Schadendorf, R. Dummer, M. Smylie, P. Rutkowski, P.F. Ferrucci, A. Hill, J. Wagstaff, M.S. Carlino, J.B. Haanen, M. Maio, I. Marquez-Rodas, G.A. McArthur, P.A. Ascierto, G.V. Long, M.K. Callahan, M.A. Postow, K. Grossmann, M. Sznol, B. Dreno, L. Bastholt, A. Yang, L.M. Rollin, C. Horak, F.S. Hodi, J.D. Wolchok, Combined nivolumab and ipilimumab or monotherapy in untreated melanoma, N. Engl. J. Med. 373 (2015) 23–34.

[31] C. Xu, Y.P. Chen, X.J. Du, J.Q. Liu, C.L. Huang, L. Chen, G.Q. Zhou, W.F. Li, Y.P. Mao, C. Hsu, Q. Liu, A.H. Lin, L.L. Tang, Y. Sun, J. Ma, Comparative safety of immune checkpoint inhibitors in cancer: systematic review and network meta-analysis, BMJ 363 (2018) k4226.

[32] Y. Bronstein, C.S. Ng, P. Hwu, W.J. Hwu, Radiologic manifestations of immune-related adverse events in patients with metastatic melanoma undergoing anti-CTLA-4 antibody therapy, AJR Am. J. Roentgenol. 197 (2011) W992–W1000.

[33] J.S. Weber, R. Dummer, V. de Pril, C. Lebbe, F.S. Hodi, M.D.X. Investigators, Patterns of onset and resolution of immune-related adverse events of special interest with ipilimumab: detailed safety analysis from a phase 3 trial in patients with advanced melanoma, Cancer 119 (2013) 1675–1682.

[34] R. Costa, B.A. Carneiro, M. Agulnik, A.W. Rademaker, S.G. Pai, V.M. Villaflor, M. Cristofanilli, J.A. Sosman, F.J. Giles, Toxicity profile of approved anti-PD-1 monoclonal antibodies in solid tumors: a systematic review and meta-analysis of randomized clinical trials, Oncotarget 8 (2017) 8910–8920.

[35] D.Y. Wang, J.E. Salem, J.V. Cohen, S. Chandra, C. Menzer, F. Ye, S. Zhao, S. Das, K.E. Beckermann, L. Ha, W.K. Rathmell, K.K. Ancell, J.M. Balko, C. Bowman, E.J. Davis, D.D. Chism, L. Horn, G.V. Long, M.S. Carlino, B. Lebrun-Vignes, Z. Eroglu, J.C. Hassel, A.M. Menzies, J.A. Sosman, R.J. Sullivan, J.J. Moslehi, D.B. Johnson, Fatal toxic effects associated with immune checkpoint inhibitors: a systematic review and meta-analysis, JAMA Oncol. 4 (2018) 1721–1728.

[36] G.K. Pennock, L.Q. Chow, The evolving role of immune checkpoint inhibitors in cancer treatment, Oncol. 20 (2015) 812–822.

[37] J.J. Luke, P.A. Ott, PD-1 pathway inhibitors: the next generation of immunotherapy for advanced melanoma, Oncotarget 6 (2015) 3479–3492.

[38] J. Haanen, F. Carbonnel, C. Robert, K.M. Kerr, S. Peters, J. Larkin, K. Jordan, E.G. Committee, Management of toxicities from immunotherapy: ESMO Clinical Practice Guidelines for diagnosis, treatment and follow-up, Ann. Oncol. 28 (2017) iv119–iv142.

[39] V. Sibaud, Dermatologic reactions to immune checkpoint inhibitors : skin toxicities and immunotherapy, Am. J. Clin. Dermatol. 19 (2018) 345–361.

[40] S.M. Goldinger, P. Stieger, B. Meier, S. Micaletto, E. Contassot, L.E. French, R. Dummer, Cytotoxic cutaneous adverse drug reactions during anti-PD-1 therapy, Clin. Cancer Res. 22 (2016) 4023–4029.

[41] K.L. Vivar, M. Deschaine, J. Messina, J.M. Divine, A. Rabionet, N. Patel, M.A. Harrington, L. Seminario-Vidal, Epidermal programmed cell death-ligand 1

expression in TEN associated with nivolumab therapy, J. Cutan. Pathol. 44 (2017) 381–384.
[42] S. Saw, H.Y. Lee, Q.S. Ng, Pembrolizumab-induced Stevens-Johnson syndrome in non-melanoma patients, Eur. J. Cancer 81 (2017) 237–239.
[43] C. Robert, G.V. Long, B. Brady, C. Dutriaux, M. Maio, L. Mortier, J.C. Hassel, P. Rutkowski, C. McNeil, E. Kalinka-Warzocha, K.J. Savage, M.M. Hernberg, C. Lebbe, J. Charles, C. Mihalcioiu, V. Chiarion-Sileni, C. Mauch, F. Cognetti, A. Arance, H. Schmidt, D. Schadendorf, H. Gogas, L. Lundgren-Eriksson, C. Horak, B. Sharkey, I.M. Waxman, V. Atkinson, P.A. Ascierto, Nivolumab in previously untreated melanoma without BRAF mutation, N. Engl. J. Med. 372 (2015) 320–330.
[44] C. Robert, J. Schachter, G.V. Long, A. Arance, J.J. Grob, L. Mortier, A. Daud, M.S. Carlino, C. McNeil, M. Lotem, J. Larkin, P. Lorigan, B. Neyns, C.U. Blank, O. Hamid, C. Mateus, R. Shapira-Frommer, M. Kosh, H. Zhou, N. Ibrahim, S. Ebbinghaus, A. RibasK.- investigators, Pembrolizumab versus ipilimumab in advanced melanoma, N. Engl. J. Med. 372 (2015) 2521–2532.
[45] O. Hamid, C. Robert, A. Daud, F.S. Hodi, W.J. Hwu, R. Kefford, J.D. Wolchok, P. Hersey, R.W. Joseph, J.S. Weber, R. Dronca, T.C. Gangadhar, A. Patnaik, H. Zarour, A.M. Joshua, K. Gergich, J. Elassaiss-Schaap, A. Algazi, C. Mateus, P. Boasberg, P.C. Tumeh, B. Chmielowski, S.W. Ebbinghaus, X.N. Li, S.P. Kang, A. Ribas, Safety and tumor responses with lambrolizumab (anti-PD-1) in melanoma, N. Engl. J. Med. 369 (2013) 134–144.
[46] K.M. Plachouri, E. Vryzaki, S. Georgiou, Cutaneous adverse events of immune checkpoint inhibitors: a summarized overview, Curr. Drug Saf. 14 (2019) 14–20.
[47] F.S. Hodi, S.J. O'Day, D.F. McDermott, R.W. Weber, J.A. Sosman, J.B. Haanen, R. Gonzalez, C. Robert, D. Schadendorf, J.C. Hassel, W. Akerley, A.J. van den Eertwegh, J. Lutzky, P. Lorigan, J.M. Vaubel, G.P. Linette, D. Hogg, C.H. Ottensmeier, C. Lebbe, C. Peschel, I. Quirt, J.I. Clark, J.D. Wolchok, J.S. Weber, J. Tian, M.J. Yellin, G.M. Nichol, A. Hoos, W.J. Urba, Improved survival with ipilimumab in patients with metastatic melanoma, N. Engl. J. Med. 363 (2010) 711–723.
[48] J.S. Weber, S.P. D'Angelo, D. Minor, F.S. Hodi, R. Gutzmer, B. Neyns, C. Hoeller, N.I. Khushalani, W.H. Miller Jr., C.D. Lao, G.P. Linette, L. Thomas, P. Lorigan, K.F. Grossmann, J.C. Hassel, M. Maio, M. Sznol, P.A. Ascierto, P. Mohr, B. Chmielowski, A. Bryce, I.M. Svane, J.J. Grob, A.M. Krackhardt, C. Horak, A. Lambert, A.S. Yang, J. Larkin, Nivolumab versus chemotherapy in patients with advanced melanoma who progressed after anti-CTLA-4 treatment (CheckMate 037): a randomised, controlled, open-label, phase 3 trial, Lancet Oncol. 16 (2015) 375–384.
[49] R.S. Herbst, J.C. Soria, M. Kowanetz, G.D. Fine, O. Hamid, M.S. Gordon, J.A. Sosman, D.F. McDermott, J.D. Powderly, S.N. Gettinger, H.E. Kohrt, L. Horn, D.P. Lawrence, S. Rost, M. Leabman, Y. Xiao, A. Mokatrin, H. Koeppen, P.S. Hegde, I. Mellman, D.S. Chen, F.S. Hodi, Predictive correlates of response to the anti-PD-L1 antibody MPDL3280A in cancer patients, Nature 515 (2014) 563–567.
[50] A. Tarhini, Immune-mediated adverse events associated with ipilimumab ctla-4 blockade therapy: the underlying mechanisms and clinical management, Sci. Tech. Rep. 2013 (2013) 857519.
[51] P.A. Ascierto, M. Del Vecchio, C. Robert, A. Mackiewicz, V. Chiarion-Sileni, A. Arance, C. Lebbe, L. Bastholt, O. Hamid, P. Rutkowski, C. McNeil, C. Garbe, C. Loquai, B. Dreno, L. Thomas, J.J. Grob, G. Liszkay, M. Nyakas, R. Gutzmer, J. Pikiel, F. Grange, C. Hoeller, V. Ferraresi, M. Smylie, D. Schadendorf, L. Mortier, I.M. Svane, D. Hennicken, A. Qureshi, M. Maio, Ipilimumab 10 mg/kg versus ipilimumab 3 mg/kg in patients with unresectable or metastatic melanoma: a randomised, double-blind, multicentre, phase 3 trial, Lancet Oncol. 18 (2017) 611–622.
[52] S. Yanai, S. Nakamura, T. Matsumoto, Nivolumab-induced colitis treated by infliximab, Clin. Gastroenterol. Hepatol. 15 (2017) e80–e81.
[53] M. Collins, J.M. Michot, F.X. Danlos, C. Mussini, E. Soularue, C. Mateus, D. Loirat, A. Buisson, I. Rosa, O. Lambotte, S. Laghouati, N. Chaput, C. Coutzac, A.L. Voisin, J.C. Soria, A. Marabelle, S. Champiat, C. Robert, F. Carbonnel, Inflammatory gastrointestinal diseases associated with PD-1 blockade antibodies, Ann. Oncol. 28 (2017) 2860–2865.
[54] R. Yamauchi, T. Araki, K. Mitsuyama, T. Tokito, H. Ishii, S. Yoshioka, K. Kuwaki, A. Mori, T. Yoshimura, O. Tsuruta, T. Torimura, The characteristics of nivolumab-induced colitis: an evaluation of three cases and a literature review, BMC Gastroenterol. 18 (2018) 135.
[55] E. Soularue, P. Lepage, J.F. Colombel, C. Coutzac, D. Faleck, L. Marthey, M. Collins, N. Chaput, C. Robert, F. Carbonnel, Enterocolitis due to immune checkpoint inhibitors: a systematic review, Gut 67 (2018) 2056–2067.
[56] J.S. Weber, F.S. Hodi, J.D. Wolchok, S.L. Topalian, D. Schadendorf, J. Larkin, M. Sznol, G.V. Long, H. Li, I.M. Waxman, J. Jiang, C. Robert, Safety profile of nivolumab monotherapy: a pooled analysis of patients with advanced melanoma, J. Clin. Oncol. 35 (2017) 785–792.
[57] A.M. Eggermont, V. Chiarion-Sileni, J.J. Grob, R. Dummer, J.D. Wolchok, H. Schmidt, O. Hamid, C. Robert, P.A. Ascierto, J.M. Richards, C. Lebbe, V. Ferraresi, M. Smylie, J.S. Weber, M. Maio, C. Konto, A. Hoos, V. de Pril, R.K. Gurunath, G. de Schaetzen, S. Suciu, A. Testori, Adjuvant ipilimumab versus placebo after complete resection of high-risk stage III melanoma (EORTC 18071): a randomised, double-blind, phase 3 trial, Lancet Oncol. 16 (2015) 522–530.
[58] C. Belli, M. Zuin, L. Mazzarella, D. Trapani, P. D'Amico, E. Guerini-Rocco, B. Achutti Duso, G. Curigliano, Liver toxicity in the era of immune checkpoint inhibitors: a practical approach, Crit. Rev. Oncol. Hematol. 132 (2018) 125–129.
[59] E. De Martin, J.M. Michot, B. Papouin, S. Champiat, C. Mateus, O. Lambotte, B. Roche, T.M. Antonini, A. Coilly, S. Laghouati, C. Robert, A. Marabelle, C. Guettier, D. Samuel, Characterization of liver injury induced by cancer immunotherapy using immune checkpoint inhibitors, J. Hepatol. 68 (2018) 1181–1190.
[60] M. Sznol, M.A. Postow, M.J. Davies, A.C. Pavlick, E.R. Plimack, M. Shaheen, C. Veloski, C. Robert, Endocrine-related adverse events associated with immune checkpoint blockade and expert insights on their management, Cancer Treat Rev. 58 (2017) 70–76.
[61] D.L. Morganstein, Z. Lai, L. Spain, S. Diem, D. Levine, C. Mace, M. Gore, J. Larkin, Thyroid abnormalities following the use of cytotoxic T-lymphocyte antigen-4 and programmed death receptor protein-1 inhibitors in the treatment of melanoma, Clin. Endocrinol. 86 (2017) 614–620.
[62] P. Cukier, F.C. Santini, M. Scaranti, A.O. Hoff, Endocrine side effects of cancer immunotherapy, Endocr. Relat. Cancer 24 (2017) T331–T347.
[63] D.J. Byun, J.D. Wolchok, L.M. Rosenberg, M. Girotra, Cancer immunotherapy - immune checkpoint blockade and associated endocrinopathies, Nat. Rev. Endocrinol. 13 (2017) 195–207.
[64] T. Dillard, C.G. Yedinak, J. Alumkal, M. Fleseriu, Anti-CTLA-4 antibody therapy associated autoimmune hypophysitis: serious immune related adverse events across a spectrum of cancer subtypes, Pituitary 13 (2010) 29–38.
[65] M. Ryder, M. Callahan, M.A. Postow, J. Wolchok, J.A. Fagin, Endocrine-related adverse events following ipilimumab in patients with advanced melanoma: a comprehensive retrospective review from a single institution, Endocr. Relat. Cancer 21 (2014) 371–381.
[66] E. Gonzalez-Rodriguez, D. Rodriguez-Abreu, I.-B. Spanish Group for Cancer, Immune checkpoint inhibitors: review and management of endocrine adverse events, Oncol. 21 (2016) 804–816.
[67] B. van der Hiel, C.U. Blank, J.B. Haanen, M.P. Stokkel, Detection of early onset of hypophysitis by (18)F-FDG PET-CT in a patient with advanced stage melanoma treated with ipilimumab, Clin. Nucl. Med. 38 (2013) e182–184.
[68] A.T. Faje, R. Sullivan, D. Lawrence, N.A. Tritos, R. Fadden, A. Klibanski, L. Nachtigall, Ipilimumab-induced hypophysitis: a detailed longitudinal analysis in a large cohort of patients with metastatic melanoma, J. Clin. Endocrinol. Metab. 99 (2014) 4078–4085.
[69] B. Konda, F. Nabhan, M.H. Shah, Endocrine dysfunction following immune checkpoint inhibitor therapy, Curr. Opin. Endocrinol. Diabetes Obes. 24 (2017) 337–347.
[70] L. Min, F.S. Hodi, A. Giobbie-Hurder, P.A. Ott, J.J. Luke, H. Donahue, M. Davis, R.S. Carroll, U.B. Kaiser, Systemic high-dose corticosteroid treatment does not improve the outcome of ipilimumab-related hypophysitis: a retrospective cohort study, Clin. Cancer Res. 21 (2015) 749–755.
[71] P. Iglesias, Cancer immunotherapy-induced endocrinopathies: clinical behavior and therapeutic approach, Eur. J. Intern. Med. 47 (2018) 6–13.
[72] F. Albarel, C. Gaudy, F. Castinetti, T. Carre, I. Morange, B. Conte-Devolx, J.J. Grob, T. Brue, Long-term follow-up of ipilimumab-induced hypophysitis, a common adverse event of the anti-CTLA-4 antibody in melanoma, Eur. J. Endocrinol. 172 (2015) 195–204.
[73] K. Jung, X. Zeng, M. Bilusic, Nivolumab-associated acute glomerulonephritis: a case report and literature review, BMC Nephrol. 17 (2016) 188.
[74] F.B. Cortazar, K.A. Marrone, M.L. Troxell, K.M. Ralto, M.P. Hoenig, J.R. Brahmer, D.T. Le, E.J. Lipson, I.G. Glezerman, J. Wolchok, L.D. Cornell, P. Feldman, M.B. Stokes, S.A. Zapata, F.S. Hodi, P.A. Ott, M. Yamashita, D.E. Leaf, Clinicopathological features of acute kidney injury associated with immune checkpoint inhibitors, Kidney Int. 90 (2016) 638–647.
[75] R. Wanchoo, S. Karam, N.N. Uppal, V.S. Barta, G. Deray, C. Devoe, V. Launay-Vacher, K.D. Jhaveri, Cancer, I. Kidney international network workgroup on immune checkpoint, adverse renal effects of immune checkpoint inhibitors: a narrative review, Am. J. Nephrol. 45 (2017) 160–169.
[76] N.T. Mason, N.I. Khushalani, J.S. Weber, S.J. Antonia, H.L. McLeod, Modeling the cost of immune checkpoint inhibitor-related toxicities, J. Clin. Oncol. 34 (2016) 6627-6627.
[77] S. Knauss, L. Ginesta Roque, P. Huhnchen, L. Heinzerling, W. Bohmerle, M. Endres, [Neurological Side Effects of Checkpoint Inhibitors], Nervenarzt, (2018).
[78] M. Touat, D. Talmasov, D. Ricard, D. Psimaras, Neurological toxicities associated with immune-checkpoint inhibitors, Curr. Opin. Neurol. 30 (2017) 659–668.
[79] A.F. Hottinger, Neurologic complications of immune checkpoint inhibitors, Curr. Opin. Neurol. 29 (2016) 806–812.
[80] L.M. Yshii, R. Hohlfeld, R.S. Liblau, Inflammatory CNS disease caused by immune checkpoint inhibitors: status and perspectives, Nat. Rev. Neurol. 13 (2017) 755–763.
[81] S. Cuzzubbo, F. Javeri, M. Tissier, A. Roumi, C. Barlog, J. Doridam, C. Lebbe, C. Belin, R. Ursu, A.F. Carpentier, Neurological adverse events associated with immune checkpoint inhibitors: review of the literature, Eur. J. Cancer 73 (2017) 1–8.
[82] M.C. Dalakas, Neurological complications of immune checkpoint inhibitors: what happens when you 'take the brakes off' the immune system, Ther. Adv. Neurol. Disord. 11 (2018) 1756286418799864.
[83] S. Suzuki, N. Ishikawa, F. Konoeda, N. Seki, S. Fukushima, K. Takahashi, H. Uhara, Y. Hasegawa, S. Inomata, Y. Otani, K. Yokota, T. Hirose, R. Tanaka, N. Suzuki, M. Matsui, Nivolumab-related myasthenia gravis with myositis and myocarditis in Japan, Neurology 89 (2017) 1127–1134.
[84] N.L. Gonzalez, A. Puwanant, A. Lu, S.M. Marks, S.A. Zivkovic, Myasthenia triggered by immune checkpoint inhibitors: new case and literature review, Neuromuscul. Disord. 27 (2017) 266–268.
[85] T. Liewluck, J.C. Kao, M.L. Mauermann, PD-1 inhibitor-associated myopathies: emerging immune-mediated myopathies, J. Immunother. 41 (2018) 208–211.
[86] Y.Z. Alabed, A. Aghayev, C. Sakellis, A.D. Van den Abbeele, Pancreatitis secondary to anti-programmed death receptor 1 immunotherapy diagnosed by FDG PET/CT,

Clin. Nucl. Med. 40 (2015) e528–529.
[87] C.F. Friedman, V. Clark, A.V. Raikhel, T. Barz, A.N. Shoushtari, P. Momtaz, M.K. Callahan, J.D. Wolchok, P.B. Chapman, M.D. Hellmann, M.A. Postow, Thinking critically about classifying adverse events: incidence of pancreatitis in patients treated with nivolumab + ipilimumab, J. Natl. Cancer Inst. 109 (2017).
[88] Q. Su, X.C. Zhang, C.G. Zhang, Y.L. Hou, Y.X. Yao, B.W. Cao, Risk of immune-related pancreatitis in patients with solid tumors treated with immune checkpoint inhibitors: systematic assessment with meta-analysis, J. Immunol. Res. 2018 (2018) 1027323.
[89] H. Abu-Sbeih, T. Tang, Y. Lu, S. Thirumurthi, M. Altan, A.A. Jazaeri, R. Dadu, E. Coronel, Y. Wang, Clinical characteristics and outcomes of immune checkpoint inhibitor-induced pancreatic injury, J. Immunother. Cancer 7 (2019) 31.
[90] S. Chuzi, F. Tavora, M. Cruz, R. Costa, Y.K. Chae, B.A. Carneiro, F.J. Giles, Clinical features, diagnostic challenges, and management strategies in checkpoint inhibitor-related pneumonitis, Cancer Manag. Res. 9 (2017) 207–213.
[91] K. Suresh, K.R. Voong, B. Shankar, P.M. Forde, D.S. Ettinger, K.A. Marrone, R.J. Kelly, C.L. Hann, B. Levy, J.L. Feliciano, J.R. Brahmer, D. Feller-Kopman, A.D. Lerner, H. Lee, L. Yarmus, F. D'Alessio, R.K. Hales, C.T. Lin, K.J. Psoter, S.K. Danoff, J. Naidoo, Pneumonitis in non-small cell lung cancer patients receiving immune checkpoint immunotherapy: incidence and risk factors, J. Thorac. Oncol. 13 (2018) 1930–1939.
[92] I.Z. Barjaktarevic, N. Qadir, A. Suri, J.T. Santamauro, D. Stover, Organizing pneumonia as a side effect of ipilimumab treatment of melanoma, Chest 143 (2013) 858–861.
[93] S.H. Tirumani, N.H. Ramaiya, A. Keraliya, N.D. Bailey, P.A. Ott, F.S. Hodi, M. Nishino, Radiographic profiling of immune-related adverse events in advanced melanoma patients treated with ipilimumab, Cancer Immunol. Res. 3 (2015) 1185–1192.
[94] M.A. Postow, J. Chesney, A.C. Pavlick, C. Robert, K. Grossmann, D. McDermott, G.P. Linette, N. Meyer, J.K. Giguere, S.S. Agarwala, M. Shaheen, M.S. Ernstoff, D. Minor, A.K. Salama, M. Taylor, P.A. Ott, L.M. Rollin, C. Horak, P. Gagnier, J.D. Wolchok, F.S. Hodi, Nivolumab and ipilimumab versus ipilimumab in untreated melanoma, N. Engl. J. Med. 372 (2015) 2006–2017.
[95] K. Margolin, Ipilimumab in a Phase II trial of melanoma patients with brain metastases, OncoImmunology 1 (2012) 1197–1199.
[96] D.B. Johnson, J.M. Balko, M.L. Compton, S. Chalkias, J. Gorham, Y. Xu, M. Hicks, I. Puzanov, M.R. Alexander, T.L. Bloomer, J.R. Becker, D.A. Slosky, E.J. Phillips, M.A. Pilkinton, L. Craig-Owens, N. Kola, G. Plautz, D.S. Reshef, J.S. Deutsch, R.P. Deering, B.A. Olenchock, A.H. Lichtman, D.M. Roden, C.E. Seidman, I.J. Koralnik, J.G. Seidman, R.D. Hoffman, J.M. Taube, L.A. Diaz Jr., R.A. Anders, J.A. Sosman, J.J. Moslehi, Fulminant myocarditis with combination immune checkpoint blockade, N. Engl. J. Med. 375 (2016) 1749–1755.
[97] S.S. Mahmood, M.G. Fradley, J.V. Cohen, A. Nohria, K.L. Reynolds, L.M. Heinzerling, R.J. Sullivan, R. Damrongwatanasuk, C.L. Chen, D. Gupta, M.C. Kirchberger, M. Awadalla, M.Z.O. Hassan, J.J. Moslehi, S.P. Shah, S. Ganatra, P. Thavendiranathan, D.P. Lawrence, J.D. Groarke, T.G. Neilan, Myocarditis in patients treated with immune checkpoint inhibitors, J. Am. Coll. Cardiol. 71 (2018) 1755–1764.
[98] M. Escudier, J. Cautela, N. Malissen, Y. Ancedy, M. Orabona, J. Pinto, S. Monestier, J.J. Grob, U. Scemama, A. Jacquier, N. Lalevee, J. Barraud, M. Peyrol, M. Laine, L. Bonello, F. Paganelli, A. Cohen, F. Barlesi, S. Ederhy, F. Thuny, Clinical features, management, and outcomes of immune checkpoint inhibitor-related cardiotoxicity, Circulation 136 (2017) 2085–2087.
[99] K. Tajiri, M. Ieda, Cardiac complications in immune checkpoint inhibition therapy, Front. Cardiovasc. Med. 6 (2019) 3.
[100] A.M. Menzies, D.B. Johnson, S. Ramanujam, V.G. Atkinson, A.N.M. Wong, J.J. Park, J.L. McQuade, A.N. Shoushtari, K.K. Tsai, Z. Eroglu, O. Klein, J.C. Hassel, J.A. Sosman, A. Guminski, R.J. Sullivan, A. Ribas, M.S. Carlino, M.A. Davies, S.K. Sandhu, G.V. Long, Anti-PD-1 therapy in patients with advanced melanoma and preexisting autoimmune disorders or major toxicity with ipilimumab, Ann. Oncol. 28 (2017) 368–376.
[101] F.C. Santini, H. Rizvi, O. Wilkins, M. van Voorthuysen, E. Panora, D. Halpenny, M.G. Kris, C.M. Rudin, J.E. Chaft, M.D. Hellmann, Safety of retreatment with immunotherapy after immune-related toxicity in patients with lung cancers treated with anti-PD(L)-1 therapy, J. Clin. Oncol. 35 (2017) 9012-9012.