Abdominal Radiology

© Springer Science+Business Media, LLC, part of Springer Nature 2018
Published online: 27 July 2018

Abdom Radiol (2019) 44:85–94
https://doi.org/10.1007/s00261-018-1714-x

Computed tomographic perfusion with 160-mm coverage: comparative analysis of hepatocellular carcinoma treated by two transarterial chemoembolization courses relative to magnetic resonance imaging findings

Matthieu Bayle,[1] Isabelle Clerc-Urmès,[2] Ahmet Ayav,[3,4] Jean-Pierre Bronowicki,[4,5,6] Isabelle Petit,[1] Xavier Orry,[1] and Valérie Laurent[1,4,7]

[1]Department of Radiology, CHRU Nancy, Brabois Adults Hospital, 54500 Vandoeuvre-lès-Nancy, France
[2]Biostatistics Unit (PARC), CHRU Nancy, 54500 Vandoeuvre-lès-Nancy, France
[3]Department of HBP Surgery, CHRU Nancy, Brabois Adults Hospital, 54500 Vandoeuvre-lès-Nancy, France
[4]Université de Lorraine, Faculté de Médecine, 54500 Vandoeuvre-lès-Nancy, France
[5]Department of Hepato-gastroenterology, CHRU Nancy, Brabois Adults Hospital, 54500 Vandoeuvre-lès-Nancy, France
[6]INSERM, U954, Vandoeuvre-lès-Nancy, France
[7]INSERM, U947, IADI, 54000 Vandoeuvre-lès-Nancy, France

Abstract

Purpose: The aim of this study was to assess hepatocellular carcinoma (HCC) response with CT perfusion parameters before and after two transarterial chemo embolization (TACE) courses compared with MRI, and to search for predictive factors of response.
Methods: 37 lesions (19 patients) were included between October 2015 and September 2017, based on the Barcelona Clinic Liver Cancer guidelines. CT perfusion with 160-mm coverage and MRI were performed before and after the first TACE course, and after the second TACE course. Quantitative perfusion parameters were compared to the response assessed with MRI using mRECIST criteria, defining response groups: complete response (CR), partial response (PR), no response (NR), response (including CR and PR), no complete response (NCR, including PR and NR).
Results: Pre-TACE blood flow (BF) and hepatic arterial blood flow (HABF) were significantly higher in lesions with post-TACE 1 CR than in those with NCR (BF: 118.8 vs. 76.3 mL/100 g/min, $p = 0.0231$; HABF: 76 vs. 44.2 mL/100 g/min, $p = 0.0112$). Pre-TACE time to peak (TTP) and mean transit time (MTT) were significantly lower in lesions with post-TACE 2 response than in those with NR (TTP: 31.5 vs. 46.1 s, $p = 0.0313$; MTT: 15.8 vs. 22.8 s, $p = 0.0204$). Post-TACE 1 and post-TACE 2 perfusion parameters did not exhibit any statistically significant differences relative to MRI response.
Conclusion: Our study did not find, after a first TACE course, perfusion parameters associated with a response to a second TACE course. However, baseline perfusion parameters analysis could lead to better therapeutic management of HCC by targeting lesions likely to respond well to TACE courses.

Key words: Hepatocellular carcinoma—Transarterial chemoembolization—Perfusion imaging—Computed tomography—Magnetic resonance imaging

Liver cancers are the 5th most common cancers worldwide, with Hepatocellular Carcinoma (HCC) being the most common form [1]. HCC is a hypervascular tumor characterized in imaging by intense enhancement at arterial phase and wash-out at portal venous phase, whose diagnosis is most often performed non-invasively

Electronic supplementary material The online version of this article (https://doi.org/10.1007/s00261-018-1714-x) contains supplementary material, which is available to authorized users.

Correspondence to: Matthieu Bayle; *email:* matthieu.bayle2@gmail.com

by computed tomography (CT) or magnetic resonance imaging (MRI) [2].

Therapeutic strategy relies on the tumor's stage. According to the guidelines of the American Association for the Studies of Liver Diseases (AASLD), chemoembolization is indicated in palliative therapeutic management of intermediate-stage HCC, corresponding to Child–Pugh A or B patients, with large or multifocal HCC, without vascular invasion or secondary extrahepatic lesion [3, 4].

Transarterial chemo embolization (TACE) consists in selective intra-arterial injection of chemotherapy emulsified with lipiodol (Lipiodol Ultra Fluid, Guerbet Laboratory, France), followed by embolization with microparticles.

Tumor response should be evaluated according to the mRECIST criteria, by measuring the hypervascular portion of the viable tumor residue and not the total diameter of the lesion, which may be the site of necrosis or lipiodol deposits [4, 5]. This assessment is difficult with computed tomography due to beam-hardening artifacts secondary to the presence of nearby lipiodol. MRI is, for this, a better examination tool [5]. However, these morphological examinations can only measure the size of the residue, without quantifying the tumor perfusion changes. Nevertheless, neoangiogenesis is a key process in tumor growth, particularly for HCC [6].

Computed tomographic (CT) perfusion assesses these data by dynamically measuring tumor enhancement following the injection of contrast medium. This technique has an emerging role in oncological imaging, both for tumor detection and characterization, as well as for evaluation of post-therapeutic response [7, 8]. CT perfusion is highly performant for assessing the response of HCC treated with anti-angiogenic agents [9, 10] or by chemoembolization [11]. The inquiry for predictive factors of chemoembolization response is also a major issue for the therapeutic management of these patients, in order to better identify the good responders and avoid repeating a potentially ineffective and expensive treatment. The most valuable predictive factors in imaging mainly consist in the number and size of the lesions [12], the place of CT perfusion is currently being evaluated.

The objective of the present study was to assess the perfusion data of HCC treated with two successive courses of TACE, in order to highlight predictive factors of response to a first and a second course.

Materials and methods

Study design

This retrospective single-center study included patients treated for HCCs with two courses of TACE in our center between October 2015 and September 2017. A liver MRI and a CT perfusion were scheduled between 4 and 6 weeks before the first treatment course and thereafter between 4 and 6 weeks after the first and second treatment courses.

Ethical aspects

This study was entered into the registry of the Data Protection Office of our center under the number R2018-08. The data were anonymized during their extraction.

Study population

Patients over 18 years of age with 1 or more stage B HCC lesions according to the BCLC classification, having received two TACE courses, with liver MRI and CT perfusion before the first treatment and after each treatment were enrolled.

Diagnosis of HCC was made by MRI or CT according to the Barcelona criteria modified in 2012: lesions > 1 cm, hypervascular at arterial phase, with a wash-out at portal venous phase, within a cirrhotic liver. The indication of TACE treatment was established after a multidisciplinary staff.

Patients with a Child–Pugh score B8, B9 or C, who underwent a previous local treatment for nodule were excluded. Furthermore, patients with renal failure, known to suffer from allergies to iodinated contrast medium or in whom TACE treatment was impossible to administer (extra-hepatic metastasis, portal thrombosis, TP < 50%, platelets < 50,000/mm^3, bilirubinemia > 4 mg/dL, serum creatinine > 1.7 mg/dL) were ineligible. An absence of CT perfusion imaging before and after TACE or uninterpretable CT perfusion also excluded patients from the study.

MRI

Response was assessed by MRI, considered as the gold standard for the evaluation of HCCs. The examinations were performed on 1.5T (Magnetom AERA, Siemens, Erlangen, Germany) and 3T (Magnetom SKYRA and PRISMA, Siemens, Erlangen, Germany) MRI. The acquisition protocols were in accordance with current recommendations with axial T2 weighted sequence with saturation of the fat signal, axial T1 in phase-out phase (IP-OP) sequence, axial diffusion sequence, followed by multiphase axial T1 with saturation of the fat signal (without injection, arterial, portal, and late phases) sequences. The contrast medium consisted of gadobenate dimeglumine (MULTIHANCE, Bracco Imaging France, Courcouronnes, France) at a dose of 0.1 mL/kg.

The examinations were reviewed by a junior radiologist and a senior radiologist specialized in liver imaging in order to define target lesions and to assess response to treatment. Tumor response was evaluated according to the mRECIST criteria, with three response groups defined as follows:

- Complete response (CR).
- Partial response (PR) decrease in the sum of the diameters by at least 30%.
- No response (NR), defined as stable disease (sum of the diameters between − 30% and + 20%) or progressive disease (at least 20% increase of the sum of the diameters).

CT perfusion

The perfusion CT scans were performed on a volumic CT scanner with a 160 mm coverage (Revolution CT, General Electric, Milwaukee, Wisconsin, USA). Perfusion acquisitions were incorporated into the standard quadriphasic liver CT protocol.

Examination began with an acquisition without injection. The second phase corresponded to hepatic perfusion imaging with 160 mm collimation encompassing most of the hepatic parenchyma, performed after intravenous injection of 45 mL of iodinated contrast medium (Xenetix 350, Guerbet, Aulnay-sous-Bois, France), at a flow rate of 5 mL/s. A series of 15 acquisitions of 1 s duration was first performed, at 1 s intervals, corresponding to the arterial enhancement of the lesions, followed by six acquisitions of 1 s duration, at 20 s intervals, corresponding to the wash-out. The total acquisition time was approximately 2 min and 45 s. These series were performed at 80 kV, with variable milliamperes (from 150 to 300 mAs), and an iterative reconstruction algorithm with ASIR-V 100%. The radiation dose (dose-length product) was estimated at 1200 mGy.cm. The acquisitions were made under free breathing with an abdominal compression belt.

Pelvic abdominal acquisitions were subsequently performed after a new injection of 100 mL of iodinated contrast medium, at arterial, portal, and late phases.

Post-processing

CT perfusion data were transferred to a post-processing workstation (Advantage Workstation 4.7, GE Medical Systems) and anonymized. They had an automatic compensation for respiratory movements by elastic image registration, and were analyzed using dedicated software (4D CT perfusion, General Electric).

Regions of interest (ROI) were placed manually in the aorta and in the portal trunk, from which the software calculated the perfusion maps according to a deconvolution algorithm for blood volume (BV, in mL of blood per 100 g of tissue), blood flow (BF, in mL/100 g/min), hepatic arterial blood flow (HABF, in mL/100 g/min), hepatic portal blood flow (HPBF, in mL/100 g/min), mean transit time (MTT, in seconds), and hepatic arterial fraction (HAF, in % of total blood volume). A standard algorithm was used to calculate time to peak (TTP, in seconds) and mean slope increase (MSI, no units).

On pre-TACE CT scans, the ROIs were placed on the whole lesion for hypervascular ones, and on hypervascular areas for lesions with a necrotic component. On post-TACE 1 and 2 CT scans, the ROIs were placed on the residual hypervascular tissue. We did not consider a minimum ROI area. No ROIs were placed on complete response (CR) lesions.

Chemoembolization

Chemoembolizations were performed on a Philips Allura CVFD system (Philips, Eindhoven, Netherland).

The procedure began with a diagnostic coelio-mesenteric angiography to assess the vascular anatomy and possible variants. A Cone-Beam-CT angiography centered on the liver was subsequently performed, allowing us to define the target lesions and their respective feeder arteries.

Each lesion was then treated after selective catheterization with an emulsified mixture of 15 mL of lipiodol and 50 mg of epirubicin. Embolization was performed with a mixture of Iobitridol (Xenetix 350, Guerbet, Aulnay-sous-Bois, France) and microparticles (EmboGold 100-300μ to 700-900μ, Biosphere Medical, Roissy, France), until obtaining a level of devascularization deemed satisfactory by the operator.

Statistical analyses

Lesions within a same patient were defined as independent entities and considered as a statistical unit. The overall sample characteristics are presented as number and percentages for qualitative variables, and as means, quartiles, and standard deviations for quantitative variables.

Comparisons of perfusion parameters according to the MRI response group after one and two TACE were performed using the Chi 2 test for qualitative variables and Student's t test for quantitative variables. A difference of $p < 0.05$ was considered to be significant.

The statistical analysis of the data was performed with the SAS software version 9.4 (SAS Institute, Inc., Cary, N.C.) in conjunction with the Clinical Research Support Platform of our center.

Results

Study sample

Thirty-six patients who fulfilled our inclusion criteria underwent two TACE courses in our center between October 2015 and August 2017, 17 of whom were ultimately excluded. See Fig. 1.

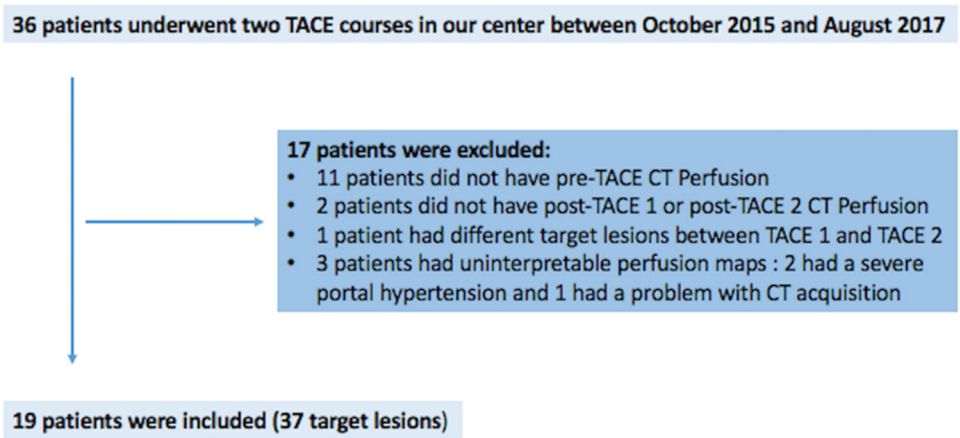

Fig. 1. Flow chart.

Table 1. Lesions characteristics

	N	Median	Q1	Q3	Min	Max
Age	37	68.0	65.0	72.0	39.0	75.0
Sex						
Male	37					
Time between TACE 1 and TACE 2 (d)	37	91.0	78.0	146.0	63.0	216.0
Time between pre TACE CT and TACE 1 (d)	37	53.0	47.0	71.0	32.0	146.0
Time between pre TACE MRI and TACE 1 (d)	37	94.0	75.0	113.0	44.0	174.0
Time between post TACE 1 CT and TACE 2 (d)	37	86.0	68.0	119.0	42.0	231.0
Time between post TACE 1 MRI and TACE 2 (d)	37	104.0	81.0	139.0	63.0	179.0
Pre TACE size (mm)	37	23	16	29	8	156
Post TACE 1 size (mm)	37	12	0	24	0	95
Post TACE 2 size (mm)	37	8	0	17	0	80
Presence of pseudocapsule	17					
Absence of pseudocapsule	20					

TACE transarterial chemoembolization, *CT* computed tomography, *MRI* magnetic resonance imaging

A total of 19 patients were thus included, all male, with a median age of 68 years. Thirty-seven target lesions were studied. All were hypervascular with wash-out. See Table 1.

Six examinations were analyzed for each patient (3 CT scans and 3 MRIs), for a total of 114 examinations. See Fig. 2.

Response assessment by MRI according to mRECIST

After one TACE, 12 lesions (32%) were in CR, 8 (22%) were in PR, and 17 (46%) were in NR.

After two TACE courses, 17 (46%) were in CR, 11 (30%) were in PR, and 9 (24%) were in NR. See Table 2.

Of the 25 lesions with no complete response (NCR, defined as PR or NR) after TACE 1, 5 lesions (20%) were in CR after TACE 2, 11 lesions (44%) were in PR, and 9 lesions (36%) were in NR. See Table 3.

Overall, between TACE 1 and TACE 2, of the 25 lesions in post-TACE 1 NCR, 11 lesions were downstaged and 14 lesions were not downstaged.

Perfusion parameters

The pre-TACE, post-TACE 1, and post-TACE 2 perfusion parameters are presented in Table 7 (Supplemental material).

In post-TACE 1, perfusion characteristics of viable residues were not significantly different from those in pre-TACE, while in post-TACE 2, perfusion characteristics of the viable residues were not significantly different from those recorded in either post-TACE 1 or pre-TACE.

Comparison of MRI response and perfusion data

Post-TACE 1 and post-TACE 2 perfusion parameters did not exhibit any statistically significant differences relative to the type of MRI response.

To the contrary, some pre-TACE perfusion parameters significantly differed according to the type of MRI response:

Post-TACE 1 CR lesions ($N = 12$) had significantly higher pre-TACE BF and HABF than post-TACE 1 NCR lesions ($N = 25$) (BF 118.8 vs. 76.3 mL/100 g/

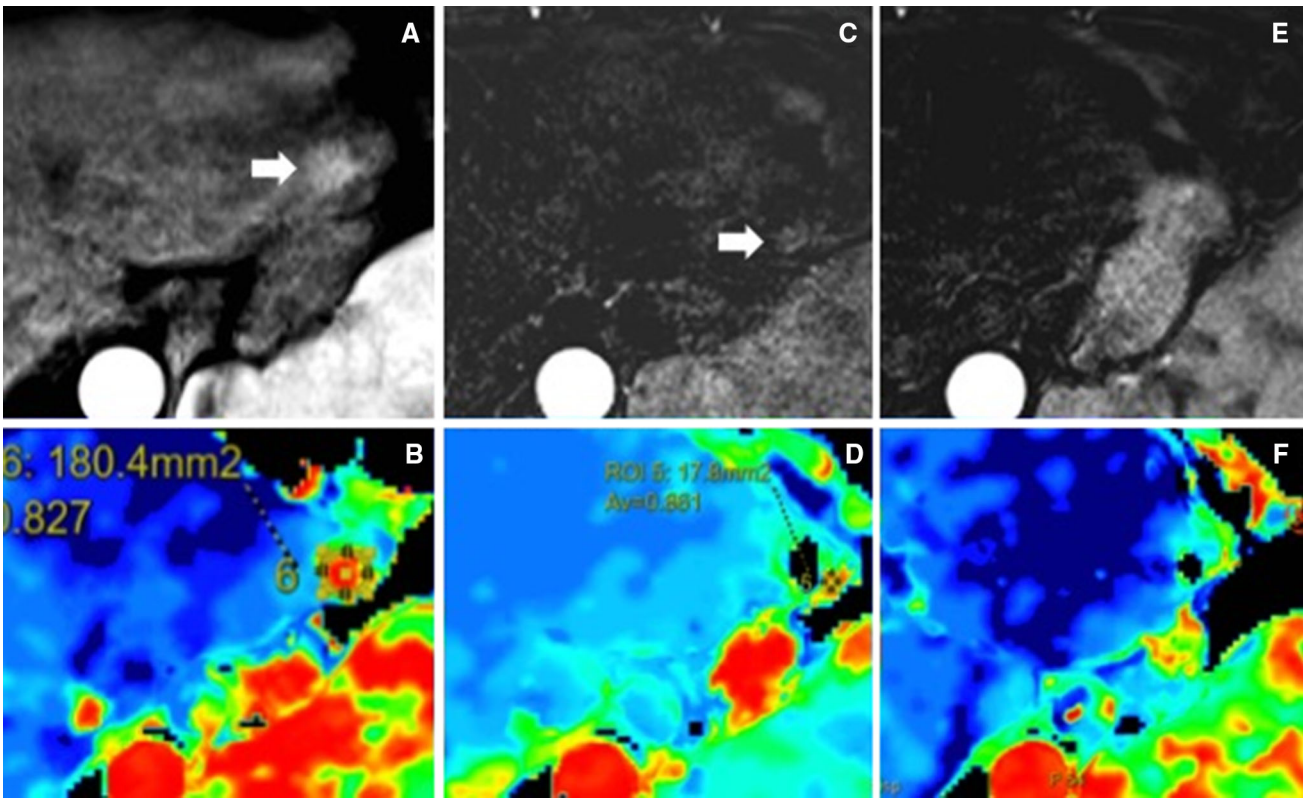

Fig. 2. Magnetic Resonance Imaging and Computed Tomographic Perfusion with Hepatic Arterial Fraction map, of a Hepatocellular Carcinoma lesion treated by two successive TACE courses. A: MRI before TACE; B: CT Perfusion before TACE. Hypervascular lesion of the segment II (arrow, A). C: MRI post-TACE 1; D: CT Perfusion post-TACE 1. Lesion is in Partial Response with a viable residue (arrow, C). E: MRI post-TACE 2; F: CT Perfusion post-TACE 2. Lesion is in Complete Response with a complete lipiodol retention.

Table 2. Post TACE 1 and post TACE 2 mRECIST response according to MRI

	CR	PR	NR
Post TACE 1	12 (32%)	8 (22%)	17 (46%)
Post TACE 2	17 (46%)	11 (30%)	9 (24%)

TACE transarterial chemoembolization, *CR* complete response, *PR* partial response, *NR* no response

Table 3. Post TACE 2 mRECIST response of lesions with no complete response (NCR) after TACE 1

	$N = 25$	%
CR	5	20
PR	11	44
NR	9	36

See Table 2

min, $p = 0.0231$; HABF 76 vs. 44.2 mL/100 g/min, $p = 0.0112$). See Table 4.

Post TACE 2 responding lesions (CR and PR) ($N = 28$) had a significantly lower pre-TACE TTP and MTT than NR lesions ($N = 9$) (TTP 31.5 vs. 46.1 s, $p = 0.0313$; MTT 15.8 vs. 22.8 s, $p = 0.0204$). See Table 5.

Perfusion parameters according to downstaging between TACE 1 and TACE 2

There were no statistically significant differences in perfusion parameters between lesions with downstaging and lesions without downstaging. See Table 6.

Discussion

Based on the meta-analyses of Llovet and Bruix [13] and Marelli [14], arterial chemoembolization improves the survival of patients with unresectable HCC. The targeted HCCs are stage B (intermediate) of BCLC classification, defined by at least one lesion larger than 5 cm, or more than 3 lesions of less than 3 cm, in patients with a Child–Pugh A or B7 cirrhosis, without vascular invasion or extra-hepatic metastasis. There is no recommandation on how many courses of treatment needs to be performed and no relevant criteria on when switching to systemic treatment in the absence of extra-hepatic metastasis or vascular invasion is required. However, increasing the

Table 4. Perfusion parameters comparison between post TACE 1 Complete Response and No Complete Response

	All $N = 37$			NCR $N = 25$ (68%)			CR $N = 12$ (32%)			p
	N	%Mean	SD	N	%Mean	SD	N	%Mean	SD	
MSI pre TACE	37	1.9	1.0	25	1.8	1.0	12	2.1	1.0	0.3798
MSI post TACE 1	25	2.4	1.6	25	2.4	1.6	0			
TTP pre TACE (s)	37	35.0	17.9	25	36.5	18.9	12	32.0	16.0	0.4868
TTP post TACE 1 (s)	25	32.3	23.3	25	32.3	23.3	0			
BV pre TACE (mL/100 g)	37	16.8	6.0	25	16.7	6.5	12	17.0	4.9	0.8869
BV post TACE 1 (mL/100 g)	25	16.4	6.5	25	16.4	6.5	0			
BF pre TACE (mL/100 g/min)	37	90.1	54.1	25	76.3	36.8	12	118.8	72.7	0.0231
BF post TACE 1 (mL/100 g/min)	25	99.8	45.1	25	99.8	45.1	0			
MTT pre TACE (s)	37	17.5	8.0	25	18.3	7.8	12	15.8	8.6	0.3760
MTT post TACE 1 (s)	25	13.7	6.9	25	13.7	6.9	0			
HAF pre TACE	37	0.7	0.2	25	0.7	0.2	12	0.8	0.2	0.5934
HAF post TACE 1	25	0.8	0.2	25	0.8	0.2	0			
HABF pre TACE (mL/100 g/min)	37	54.5	36.6	25	44.2	16,1	12	76.0	55.5	0.0112
HABF post TACE 1 (mL/100 g/min)	25	67.8	38.3	25	67.8	38.3	0			
HPBF pre TACE (mL/100 g/min)	37	35.7	39.5	25	32.9	35.0	12	41.5	48.7	0,5424
HPBF post TACE 1 (mL/100 g/min)	25	32.4	31.9	25	32,4	31,9	0			
Pre TACE size (mm)	37	29.4	27.4	25	32	32.7	12	23.8	8.1	0.4033
Pseudocapsule										0.7317
Presence	17	45.9		11	44		6	50		
Absence	20	54.1		14	56		6	50		

SD standard deviation, *TACE* transarterial chemoembolization, *MSI* mean slope of increase, *TTP* time to peak, *BV* blood volume, *BF* blood flow, *MTT* mean transit time, *HAF* hepatic arterial fraction, *HABF* Hepatic arterial blood flow, *HPBF* hepatic portal blood flow

Table 5. Perfusion parameters comparison between post TACE 2 Response and NR

	Total $N = 37$			No response $N = 9$ (24%)			Response $N = 28$ (76%)			p
	N	%Mean	SD	N	%Mean	SD	N	%Mean	SD	
MSI pre TACE	37	1.9	1.0	9	1.7	1.2	28	2.0	0.9	0.3937
MSI post TACE 1	25	2.4	1.6	9	2.2	1.5	16	2.5	1.7	0.6801
MSI post TACE 2	20	3.5	7.9	9	1.9	1.5	11	4.8	10.5	0.4190
TTP pre TACE (s)	37	35.0	17.9	9	46.1	23.0	28	31.5	14.7	0.0313
TTP post TACE 1 (s)	25	32.3	23.3	9	27.4	13.6	16	35.1	27.3	0.4448
TTP post TACE 2 (s)	20	42.3	25.5	9	46.0	23.2	11	39.3	27.9	0.5711
BV pre TACE (mL/100 g)	37	16.8	6.0	9	19.0	6.2	28	16.1	5.9	0.2250
BV post TACE 1 (mL/100 g)	25	16.4	6.5	9	18.1	6.5	16	15.5	6.6	0.3546
BV post TACE 2 (mL/100 g)	20	18.1	11.9	9	18.6	13.8	11	17.7	10.8	0.8684
BF pre TACE (mL/100 g/min)	37	90.1	54.1	9	71.4	28.9	28	96.1	59.1	0.2385
BF post TACE 1 (mL/100 g/min)	25	99.8	45.1	9	98.2	41.4	16	100.7	48.4	0.8958
BF post TACE 2 (mL/100 g/min)	20	142.4	156.8	9	106.0	72.3	11	172.1	200.9	0.3620
MTT pre TACE (s)	37	17.5	8.0	9	22.8	8.7	28	15.8	7.2	0.0204
MTT post TACE 1 (s)	25	13.7	6.9	9	14.7	8.0	16	13.2	6.5	0.6228
MTT post TACE 2 (s)	20	13.9	8.7	9	13.4	8.0	11	14.4	9.7	0.8172
HAF pre TACE	37	0.7	0.2	9	0.7	0.2	28	0.8	0.2	0.4664
HAF post TACE 1	25	0.8	0.2	9	0.7	0.2	16	0.8	0.2	0.6686
HAF post TACE 2	20	0.6	0.3	9	0.6	0.3	11	0.6	0.3	0.6593
HABF pre TACE (mL/100 g/min)	37	54.5	36.6	9	39.4	15.9	28	59.4	40.2	0.1576
HABF post TACE 1 (mL/100 g/min)	25	67.8	38.3	9	66.6	46.8	16	68.5	34.4	0.9071
HABF post TACE 2 (mL/100 g/min)	20	67,9	49.8	9	68.6	43.7	11	67.4	56.4	0.9593
HPBF pre TACE (mL/100 g/min)	37	35.7	39.5	9	33.1	26.8	28	36.5	43.1	0.8234
HPBF post TACE 1 (mL/100 g/min)	25	32.4	31.9	9	30.4	30.2	16	33.5	33.8	0.8215
HPBF post TACE 2 (mL/100 g/min)	20	93.8	160.2	9	63.8	55.6	11	118.3	211.8	0.4640
Pre TACE size (mm)	37	29.4	27.4	9	23.1	25.9	28	31.4	28	0.4396
Pseudocapsule										0.1007
Presence	17	45.9		2	22.2		15	53.6		
Absence	20	54.1		7	77.8		13	46.4		

See Table 4

Table 6. Post TACE 1 perfusion parameters comparison between lesions with and without Downstaging after TACE 2

	Total $N = 25$			No DS $N = 14$ (56%)			DS $N = 11$ (44%)			p
	N	%/mean	SD	N	%/mean	SD	N	%/mean	SD	
MSI post TACE 1	25	2.4	1.6	14	2.3	1.9	11	2.6	1.1	0.1194
TTP post TACE 1 (s)	25	32.3	23.3	14	32.2	20.3	11	32.4	27.7	0.4351
BV post TACE 1 (mL/100 g)	25	16.4	6.5	14	17.1	6.5	11	15.6	6.8	0.6459
BF post TACE 1 (mL/100 g/min)	25	99.8	45.1	14	101.8	53.9	11	97.3	33.3	0.7659
MTT post TACE 1 (s)	25	13.7	6.9	14	15.2	8.2	11	11.9	4.7	0.4045
HAF post TACE 1	25	0.8	0.2	14	0.7	0.2	11	0.8	0.2	0.5526
HABF post TACE 1 (mL/100 g/min)	25	67.8	38.3	14	67.8	45.9	11	67.8	28.0	0.5708
HPBF post TACE 1 (mL/100 g/min)	25	32.4	31.9	14	34.5	32.1	11	29.8	33.1	0,6078

See Table 4

number of TACE courses would appear to increase overall survival rate [15].

We aimed to determine whether changes in perfusion criteria in CT scanning with 160 mm coverage could represent a tool to assess prognostic factors in response to this treatment, including as early as the first TACE in order not to unduly repeat TACE treatments.

We therefore hypothesized that a modification in the perfusion parameters of the lesions after a first TACE would allow to specify a response after a second course.

Various studies have highlighted significant differences in perfusion values between HCC and the non-cancerous liver; indeed, BV, BF, HAF, and HABF were found higher within the lesions, while TTP and HPBF were lower [6, 16, 17]. CT perfusion has also been studied for the assessment of treatment response to TACE [11, 18–21]. All of these studies, aside from the study of Du et al. [22], present technical limitations since all were performed with a coverage of 4 cm, which is insufficient for the analysis of all the lesions. Yet, each lesion must be analyzed independently.

The present analysis is therefore the first study, to our knowledge, to assess CT perfusion for HCCs before and after two TACE courses, which represents three perfusion acquisitions per patient, with a coverage of 160 mm. These perfusion data were compared to MRI data, the current gold standard for the assessment of HCC tumor response [5, 23].

After a first TACE, of the 37 lesions analyzed, 12 lesions were in CR, 8 in PR and 17 in NR, according to the MRI data.

We chose not to analyze perfusion data of the lesions in CR in MRI (complete lipiodol retention in CT). Indeed, in case of complete retention, there is no longer any detectable perfusion data. However, most published studies have analyzed perfusion parameters in areas with lipiodol retention. Yang namely highlighted that HAF, HABF, and BF within the treated lesions decreased significantly after one TACE [18].

The studies by Ippolito et al. further specified that these same parameters were significantly higher in post-TACE in viable tumor residues than in healthy liver or in treated lesions containing necrosis or lipiodol retention [11, 20, 21]. In light of these procedural discrepancies, it is therefore difficult to compare our results with those of the literature [11, 18–21].

We also considered that in case of complete lipiodol retention, the morphological criteria are sufficient and that the perfusion data cannot provide additional elements. Given that the lesions are already in complete response with the first TACE, it is thus not necessary to search for predictive response criteria.

We therefore deemed more appropriate to focus on zones that were still viable, with no lipiodol retention, in order to search for quantitative data that would allow completing morphological imaging.

When comparing perfusion data of viable lesions in PR and NR after a first TACE, there was no statistically significant difference between these two response groups. The perfusion data therefore does not discriminate the two types of response, whereas these responses are notably different in MRI.

After a second TACE, among the lesions in PR after TACE 1 ($N = 8$), 2 were downstaged (25%): 2 were reclassified CR, 5 remained in PR (62.5%), and 1 progressed (12.5%).

Among the lesions in NR after TACE 1 ($N = 17$), 9 were downstaged (53%): 6 were reclassified PR (35%) and 3 to CR (18%), while 8 remained in NR (47%).

There was no statistically significant difference between the perfusion parameters of the group with downstaging compared to the group without downstaging.

To our knowledge, no other study in the literature has addressed these predictive criteria. Perfusion has been analyzed for the early assessment of treatment response: Marquez [19] had performed CT perfusions before and after a TACE, within a maximum of 48 h. Response was

assessed at 6 weeks of TACE according to the EASL criteria. Early post-TACE HAF was significantly lower in the complete response group compared to the incomplete response group.

Other studies with similar patterns had also shown that early assessment of post-TACE perfusion parameters [24–26], or performing a Cone-Beam-CT immediately after TACE [27, 28], allowed predicting tumor response in the medium term.

Hence, our results bring to light that quantitative data from perfusion CT after a first TACE can not predict element of response to a second TACE.

Secondly, we compared perfusion data of each lesion in pre-TACE according to their respective response type in MRI after one and two TACE courses.

After the first TACE, MRI allowed to define two groups of lesions: CR ($N = 12$) and NCR (PR and NR, $N = 25$). When comparing the perfusion data of these two groups in pre-TACE, certain perfusion parameters were found to differ: pre-TACE BF and pre-TACE HABF were significantly higher in the CR group compared to the NCR group (respectively 118.8 vs. 76.3 mL/100 g/min, $p = 0.0231$; 76 vs. 44.2 mL/100 g/min, $p = 0.0112$).

After the second TACE, MRI conceded two groups of lesions: response (CR or PR) ($N = 28$) and NR ($N = 9$). Again, pre-TACE perfusion parameters differed in these two groups: the pre-TACE TTP and pre-TACE MTT were significantly longer in the NR group than in the Response group (respectively 46.1 vs. 31.5 s, $p = 0.0313$; 22.8 vs. 15.8 s, $p = 0.0204$).

Accordingly, Yang et al. had similarly demonstrated that pre-TACE perfusion parameters were correlated with grades of lipiodol deposition, with pre-TACE HABF and BF being higher in the lesion group exhibiting complete deposition compared to the group with incomplete deposition [29]. Su et al. had furthermore shown that full or partial responders had a higher HAF and HABF and a lower HPBF in pre-TACE compared to the non-responder group [30].

This suggest that, prior to any treatment, lesions in CR after one TACE and those in Response after two TACE courses exhibited different perfusion characteristics from those documented respectively in post-TACE 1 NCR and in post TACE 2 NR, with a more hypervascular nature. Thus, baseline perfusion imaging provides discriminative predictive elements of tumor response after TACE, whereas the initial morphological imaging of these lesions in MRI was perfectly superimposable regardless of their response.

A high pre-TACE blood flow with a more precocious enhancement peak could therefore represent a predictor of good response to TACE treatments, with hypervascularization favoring the intra-arterial administration of chemotherapy and allowing a better lipiodol retention. Such data can only be provided by CT perfusion.

The pathophysiology of HCC is highlighted by arterial neoangiogenesis and a gradual decrease in portal vasculature. The density in micro-vessels in histological section has been well correlated with HAF, BF, and HABF, and inversely correlated with HPBF, while MTT and TTP was not assessed [31]. However, current knowledge of perfusion and the histological grade of HCC remains rather limited. Ippolito et al. failed to observe a correlation between these two parameters [6] while Sahani et al. reported an elevation in BF and BV and a decrease in MTT in well-differentiated HCC compared to moderate or poorly differentiated HCC [32]. Yet, poor tumor differentiation is correlated with worse prognosis [33].

It could thus be hypothesized that, in our study, lesions that failed to respond after two TACE courses were less well-differentiated, which would explain resistance to treatment. However, further studies relative to CT perfusion and anatomopathology would be needed to confirm such link; a prospective study including all HCCs with an analysis of perfusion criteria could be considered in this setting.

Study limitations

Our study has several limitations. First, the number of patients and target lesions are rather low, studies with larger sample numbers would be useful to confirm our results. In addition, several associated factors may have influenced the tumor's response: the TACE were performed by several different operators, the doses of lipiodol and epirubicin as well as the size of the microparticles differed for each lesion, the etiology of cirrhosis and the Child–Pugh stage were not assessed, and histology for these lesions was not available given that diagnosis was made from imaging.

In addition, 11 patients were excluded since their baseline imaging was not performed in our center and therefore these patients did not undergo a perfusion CT. Although many studies have shown interest of CT perfusion in diagnosis and monitoring of HCCs, its use is still not routine in all centers.

Lastly, two patients were excluded due to uninterpretable perfusion maps. Since a double-entry model including the aorta and the portal trunk was used herein for calculating the perfusion mappings, we presumed that these problems were related to the severe portal hypertension presented by these two patients. Future studies could review the influence of the severity of portal hypertension on perfusion parameters.

Conclusion

In conclusion, the analysis of baseline perfusion parameters could lead to better therapeutic management by targeting hypervascular lesions likely to respond well to the first TACE course, thereby avoiding repeating

unnecessary TACE courses for lesions which would tend to respond less favorably, hence reducing the morbidity associated with this treatment.

Compliance with ethical standards

Conflict of interest The authors declare that they have no conflict of interest.

Ethical approval All procedures performed in studies involving human participants were in accordance with the ethical standards of the institutional research committee and with the 1964 Helsinki declaration and its later amendments. For this type of study formal consent is not required.

References

1. El-Serag HB (2012) Epidemiology of viral hepatitis and hepatocellular carcinoma. Gastroenterology 142(1264–1273):e1. https://doi.org/10.1053/j.gastro.2011.12.061
2. Bruix J, Sherman M, American Association for the Study of Liver Diseases (2011) Management of hepatocellular carcinoma: an update. Hepatology 53:1020–1022. https://doi.org/10.1002/hep.24199
3. Heimbach JK, Kulik LM, Finn RS, et al. (2018) AASLD guidelines for the treatment of hepatocellular carcinoma. Hepatology 67:358–380. https://doi.org/10.1002/hep.29086
4. European Association For The Study of The Liver, European Organisation for Research and Treatment of Cancer (2012) EASL-EORTC clinical practice guidelines: management of hepatocellular carcinoma. J Hepatol 56:908–943. https://doi.org/10.1016/j.jhep.2011.12.001
5. Yaghmai V, Besa C, Kim E, et al. (2013) Imaging assessment of hepatocellular carcinoma response to locoregional and systemic therapy. AJR Am J Roentgenol 201:80–96. https://doi.org/10.2214/AJR.13.10706
6. Ippolito D, Capraro C, Casiraghi A, Cestari C, Sironi S (2012) Quantitative assessment of tumour associated neovascularisation in patients with liver cirrhosis and hepatocellular carcinoma: role of dynamic-CT perfusion imaging. Eur Radiol 22:803–811. https://doi.org/10.1007/s00330-011-2307-z
7. García-Figueiras R, Goh VJ, Padhani AR, et al. (2013) CT perfusion in oncologic imaging: a useful tool? AJR Am J Roentgenol 200:8–19. https://doi.org/10.2214/AJR.11.8476
8. Kim SH, Kamaya A, Willmann JK (2014) CT perfusion of the liver: principles and applications in oncology. Radiology 272:322–344. https://doi.org/10.1148/radiol.14130091
9. Jiang T, Kambadakone A, Kulkarni NM, Zhu AX, Sahani DV (2012) Monitoring response to antiangiogenic treatment and predicting outcomes in advanced hepatocellular carcinoma using image biomarkers, CT perfusion, tumor density, and tumor size (RECIST). Invest Radiol 47:11–17. https://doi.org/10.1097/RLI.0b013e3182199bb5
10. Kaufmann S, Thaiss WM, Schulze M, et al. (2017) Prognostic value of perfusion CT in hepatocellular carcinoma treatment with sorafenib: comparison with mRECIST in longitudinal follow-up. Acta Radiol . https://doi.org/10.1177/0284185117732805
11. Ippolito D, Bonaffini P-A, Ratti L, et al. (2010) Hepatocellular carcinoma treated with transarterial chemoembolization: dynamic perfusion-CT in the assessment of residual tumor. World J. Gastroenterol 16:5993–6000
12. Lladó L, Virgili J, Figueras J, et al. (2000) A prognostic index of the survival of patients with unresectable hepatocellular carcinoma after transcatheter arterial chemoembolization. Cancer 88:50–57
13. Llovet JM, Bruix J (2003) Systematic review of randomized trials for unresectable hepatocellular carcinoma: chemoembolization improves survival. Hepatology 37:429–442. https://doi.org/10.1053/jhep.2003.50047
14. Marelli L, Stigliano R, Triantos C, et al. (2007) Transarterial therapy for hepatocellular carcinoma: which technique is more effective? A systematic review of cohort and randomized studies. Cardiovasc Intervent Radiol 30:6–25. https://doi.org/10.1007/s00270-006-0062-3
15. Ikeda K, Kumada H, Saitoh S, Arase Y, Chayama K (1991) Effect of repeated transcatheter arterial embolization on the survival time in patients with hepatocellular carcinoma. An analysis by the Cox proportional hazard model. Cancer 68:2150–2154
16. Ippolito D, Sironi S, Pozzi M, et al. (2008) Hepatocellular carcinoma in cirrhotic liver disease: functional computed tomography with perfusion imaging in the assessment of tumor vascularization. Acad Radiol 15:919–927. https://doi.org/10.1016/j.acra.2008.02.005
17. Yang HF, Du Y, Ni JX, et al. (2010) Perfusion computed tomography evaluation of angiogenesis in liver cancer. Eur Radiol 20:1424–1430. https://doi.org/10.1007/s00330-009-1693-y
18. Yang L, Zhang X, Tan B, et al. (2012) Computed tomographic perfusion imaging for the therapeutic response of chemoembolization for hepatocellular carcinoma. J Comput Assist Tomogr 36:226–230. https://doi.org/10.1097/RCT.0b013e318245c23c
19. Marquez HP, Karalli A, Haubenreisser H, et al. (2017) Computed tomography perfusion imaging for monitoring transarterial chemoembolization of hepatocellular carcinoma. Eur J Radiol 91:160–167. https://doi.org/10.1016/j.ejrad.2017.03.014
20. Ippolito D, Fior D, Bonaffini PA, et al. (2014) Quantitative evaluation of CT-perfusion map as indicator of tumor response to transarterial chemoembolization and radiofrequency ablation in HCC patients. Eur J Radiol 83:1665–1671. https://doi.org/10.1016/j.ejrad.2014.05.040
21. Ippolito D, Fior D, Franzesi CT, et al. (2014) Tumour-related neoangiogenesis: functional dynamic perfusion computed tomography for diagnosis and treatment efficacy assessment in hepatocellular carcinoma. Dig Liver Dis 46:916–922. https://doi.org/10.1016/j.dld.2014.06.002
22. Du F, Jiang R, Gu M, He C, Guan J (2015) The clinical application of 320-detector row CT in transcatheter arterial chemoembolization (TACE) for hepatocellular carcinoma. Radiol Med 120:690–694. https://doi.org/10.1007/s11547-015-0523-3
23. Kloeckner R, Otto G, Biesterfeld S, et al. (2010) MDCT versus MRI assessment of tumor response after transarterial chemoembolization for the treatment of hepatocellular carcinoma. Cardiovasc Intervent Radiol 33:532–540. https://doi.org/10.1007/s00270-009-9728-y
24. Kaufmann S, Horger T, Oelker A, et al. (2015) Volume perfusion computed tomography (VPCT)-based evaluation of response to TACE using two different sized drug eluting beads in patients with nonresectable hepatocellular carcinoma: impact on tumor and liver parenchymal vascularisation. Eur J Radiol 84:2548–2554. https://doi.org/10.1016/j.ejrad.2015.09.009
25. Tamandl D, Waneck F, Sieghart W, et al. (2017) Early response evaluation using CT-perfusion 1 day after transarterial chemoembolization for HCC predicts treatment response and long-term disease control. Eur J Radiol 90:73–80. https://doi.org/10.1016/j.ejrad.2017.02.032
26. Wimmer T, Steiner J, Talakic E, et al. (2017) Computed tomography perfusion following transarterial chemoembolization of hepatocellular carcinoma: a feasibility study in the early period. J Comput Assist Tomogr 41:708–712. https://doi.org/10.1097/RCT.0000000000000592
27. Syha R, Grözinger G, Grosse U, et al. (2016) Parenchymal blood volume assessed by C-arm-based computed tomography in immediate posttreatment evaluation of drug-eluting bead transarterial chemoembolization in hepatocellular carcinoma. Invest Radiol 51:121–126. https://doi.org/10.1097/RLI.0000000000000215
28. Rathmann N, Kara K, Budjan J, et al. (2017) Parenchymal liver blood volume and dynamic volume perfusion CT measurements of hepatocellular carcinoma in patients undergoing transarterial chemoembolization. Anticancer Res 37:5681–5685. https://doi.org/10.21873/anticanres.12004
29. Yang L, Zhang XM, Zhou XP, et al. (2010) Correlation between tumor perfusion and lipiodol deposition in hepatocellular carcinoma after transarterial chemoembolization. J Vasc Interv Radiol 21:1841–1846. https://doi.org/10.1016/j.jvir.2010.08.015

30. Su T-H, He W, Jin L, Chen G, Xiao G-W (2017) Early response of hepatocellular carcinoma to chemoembolization: volume computed tomography liver perfusion imaging as a short-term response predictor. J Comput Assist Tomogr 41:315–320. https://doi.org/10.1097/RCT.0000000000000511
31. Bai R-J, Li J-P, Ren S-H, et al. (2014) A correlation of computed tomography perfusion and histopathology in tumor edges of hepatocellular carcinoma. HBPD INT 13:612–617
32. Sahani DV, Holalkere N-S, Mueller PR, Zhu AX (2007) Advanced hepatocellular carcinoma: CT perfusion of liver and tumor tissue–initial experience. Radiology 243:736–743. https://doi.org/10.1148/radiol.2433052020
33. Martins-Filho SN, Paiva C, Azevedo RS, Alves VAF (2017) Histological grading of hepatocellular carcinoma-a systematic review of literature. Front Med (Lausanne) 4:193. https://doi.org/10.3389/fmed.2017.00193